

CASE REPORT

Propionibacterium avidum infection following breast reduction: high morbidity from a low-virulence pathogen

Pietro G. di Summa^{1,*}, Adrien Yvon², Lorenz Larcher³, Wassim Raffoul¹, and Nathalie Koch¹

¹Department of Plastic, Reconstructive and Aesthetic Surgery, Centre Hospitalier Universitaire Vaudois (CHUV), Lausanne, Switzerland, ²University Hospital of South Manchester, Manchester, UK, and ³Department of Plastic, Reconstructive and Aesthetic Surgery, BHB – PMU, Salzburg, Austria

*Correspondence address. Department of Plastic, Reconstructive and Aesthetic Surgery, Centre Hospitalier Universitaire Vaudois (CHUV), Rue du Bugnon 46, Lausanne 10011, Switzerland. Tel: +41-0213142507; Fax: +41-0213142531; E-mail: pietro.di-summa@chuv.ch

Abstract

Propionibacterium avidum is a common inhabitant of sebaceous glands, traditionally considered to be of low virulence and generally found on implanted foreign material. We report a rare case of *P. avidum* breast abscess, causing severe morbidity following breast reduction surgery. A 36-year-old woman presented with a non-painful wound discharge 3 weeks postoperatively, and was treated conservatively. She was readmitted 7 weeks postoperatively with a red and tender breast. A purulent discharging abscess was drained under ultrasound guidance. A 2-week intravenous course of amoxicillin–clavulanic acid, followed by oral replacement for a month resulted effective. Serial ultrasound imaging was useful in treatment decision-making. The infective potential of *P. avidum* may be underappreciated. Proximity of sutures to the axilla, tobacco smoking and the potential for resorbable sutures to host bacteria may predispose to infection, and should raise the clinician's awareness.

INTRODUCTION

Reduction mammoplasty is a common surgical procedure for symptomatic breast hypertrophy. Postoperative complications include haematoma, infection, fat necrosis and delayed wound healing. Among infection agents, *Staphylococcus aureus* is the most common primary infective organism. *Propionibacterium avidum* [1–4] (*P. avidum*), a common inhabitant of sebaceous glands, is traditionally considered to be of low virulence. We report one of a few cases of *P. avidum* in breast tissue, and to our knowledge, the third described following breast reduction. We recommend an effective treatment for similar cases, drawing from the conclusions of previous literature and our own experience.

CASE REPORT

A 36-year-old Caucasian heavy smoker (1 pack/day), with no other comorbidities, presented with bilateral symptomatic breast hypertrophy. Reduction mammoplasty was performed following Thorek's technique [5]. Standard disinfection was performed with antiseptic povidone–iodine and 600 mg of intravenous (IV) clindamycin was delivered at anaesthesia induction. More than 1.1 kg of tissue was retrieved from each breast. Three weeks postoperatively, wound dehiscence associated with discharge was noted on the inferior border of the right breast. Neither redness nor heat was detected locally. The patient was afebrile with no inflammatory syndrome (WBC count 11 g/l and C-reactive

Received: November 19, 2014. Revised: December 29, 2014. Accepted: January 1, 2015

Published by Oxford University Press and JSCR Publishing Ltd. All rights reserved. © The Author 2015.

This is an Open Access article distributed under the terms of the Creative Commons Attribution Non-Commercial License (<http://creativecommons.org/licenses/by-nc/4.0/>), which permits non-commercial re-use, distribution, and reproduction in any medium, provided the original work is properly cited. For commercial re-use, please contact journals.permissions@oup.com

protein 6 mg/l). A smear of the discharge with liponecrosis showed low quantities of *P. avidum*. No antibiotic therapy was introduced at this moment and dressings with argentic sulfadiazine were prescribed every 48 h (Ialugen-plus, IBSA, Switzerland). Seven weeks postoperatively, a new red and tender induration in between the inferior quadrants of the right breast was noted. Interestingly, the patient remained afebrile with no inflammatory syndrome. A breast ultrasound (US) showed a 4 × 4 × 15 cm encapsulated collection (Fig. 1). The abscess was drained and bacteriological examination of the purulent fluid revealed a larger quantity of *P. avidum*. Amoxicillin–clavulanic acid three times/day IV was started as empirical treatment for soft tissue infection. During the IV antibiotic treatment, no differences were seen in blood test parameters; however, a clinical improvement was evident with the discharge steadily decreasing. A control breast US on Day 5 post IV treatment showed remission of the abscess (Fig. 2). Results of antibiogram analysis confirmed the bacteria presence and its sensitiveness to amoxicillin–clavulanic acid. IV antibiotherapy was continued cessation of wound dehiscence (2 weeks), and then switched to oral amoxicillin for 1 month (750 mg three times a day). A breast US 1 month later showed abscess resolution and antibiotic therapy was discontinued. On physical examination, the infection had healed, and no surgical reintervention was needed (Fig. 3).

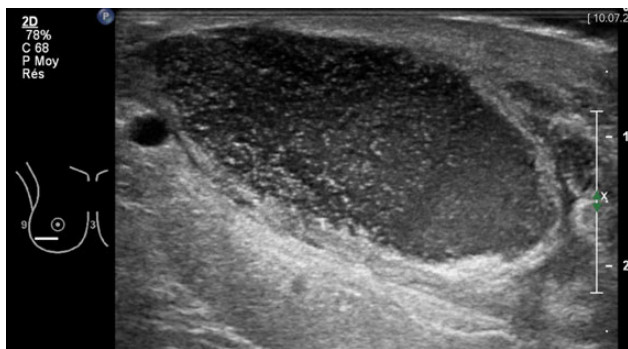


Figure 1: Right breast ultrasonography (US) showing encapsulated purulent collection (4 × 4 × 15 cm) in correspondence of the lower lateral quadrant, 7 weeks after breast reduction surgery. Abscess drainage was performed under US guidance.

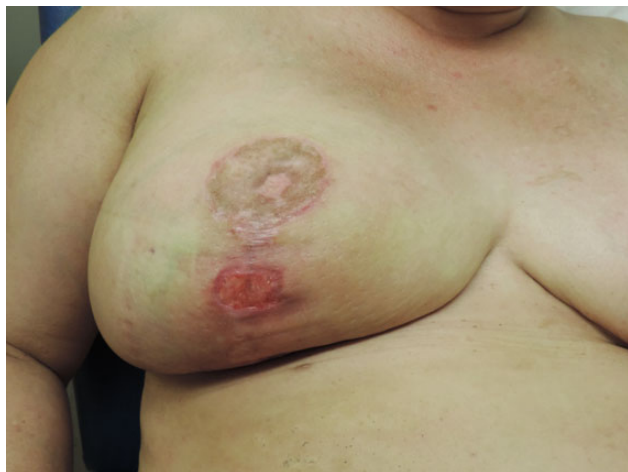

Figure 2: Clinical status after US-guided drainage and 2 weeks IV antibiotic therapy.

DISCUSSION

Propionibacteria are anaerobic, gram-positive bacilli and are a genus of *Coryneform* bacteria. The incubation period of *Propionibacteria* infections can last from a few days to several months [6]. Our case is consistent with previous reports that have described the insidious nature of infections with *P. avidum* following surgery [4]. This organism is a usual inhabitant of sebaceous glands, and hair follicles in the groin, perineal and axillary regions. The slow growth of *P. avidum* and its commensal role as a skin organism means the infections can more easily be overlooked. Typically, *P. avidum* is encountered in the presence of implanted foreign material, which is an ideal terrain for bacterial adherence and biofilm formation [6]. Other described predisposing factors contributing to *P. avidum* infections include immunosuppression, trauma, malignancy, diabetes and obstruction of sinuses or ducts [6]. Tobacco smoking in our case is likely to have increased the pathogen's morbidity postoperatively, severely affecting wound healing and supporting liponecrosis. Even if we could consider breast reduction surgery as a 'clean procedure', scar proximity to the axilla needs to be included among contamination risks. In the few described cases of *P. avidum* infections after breast reduction surgery, several antibiotic treatments have been used (Table 1). Our antibiogram was consistent with previous reports showing *P. avidum* to be sensitive to most antibiotics including penicillins, but not to metronidazole [4, 6]. Briefly, the initial choice was to administer beta-lactamase-resistant penicillins IV, followed by an oral replacement for up to 1 month. For possible penicillin allergies [2], an IV carbapenem (meropenem) was used prior to an oral fluoroquinolone (moxifloxacin). *Propionibacterium avidum* is likely to be found in the presence of implanted foreign materials. It produces an exopolysaccharide-like meshwork that has been hypothesized to play a role in biofilm formation [7], leading to persistent infections that cannot be cleared by the immune system. While no prosthetic material is present in reduction mammoplasty, sutures may host bacteria during their resorption phase, which can last over 70 days. Moreover, the contamination can proceed through the filaments and cause inflammation in the surrounding tissue [8]. In our case, braided resorbable sutures (Vycril™, Ethicon, Johnson & Johnson, USA) were used for deep layers, followed by resorbable monofilaments for the dermis and skin (Monosyn®, B. Braun Medical, Germany) [9, 10]. There is still debate whether braided

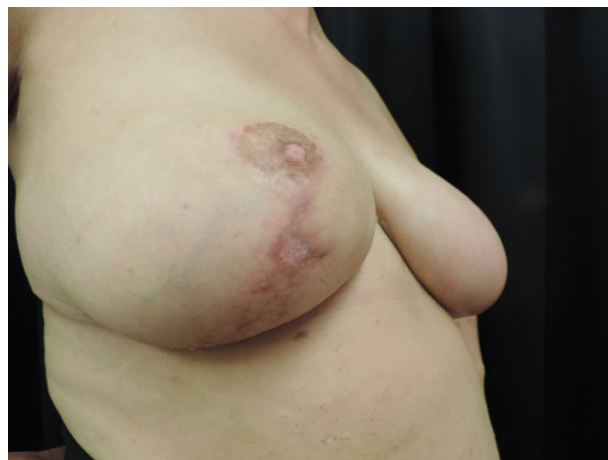

Figure 3: Complete wound healing after 6 weeks of antibiotic treatment and local dressings.

Table 1: Antibiotic treatments for *P. avidum* infection following breast reduction surgery in the literature

Surgery	Treatment	Time to complete healing	Penicillin allergy	Source
Bilateral breast reduction–unilateral infection	IV AC for 2 weeks + 4 weeks oral AC	6 weeks	Recalled possible allergy	Reported case
Bilateral breast reduction and infection	IV flucloxacillin and benzyl penicillin for 5 days + 4 weeks oral AC	5 weeks	No	Panagea et al. [1]
Bilateral breast reduction and infection	IV meropenem + 4 weeks oral moxifloxacin + 4 weeks oral AC	12 weeks	Recalled possible allergy	Levin et al. [2]
Unilateral mastectomy + TRAM flap reconstruction	IV flucloxacillin + penicillin	n/a	No	Werno et al. [4]

AC, amoxicillin–clavulanic acid; IV, intravenous; TRAM, transverse rectus abdomini muscle.

or monofilament resorbable sutures should be used in contaminated surgical fields [9], with some human and *in vivo* studies showing greater infection rates in polyfilament than in monofilament sutures, although other studies suggest no difference [8, 10].

Our case provides evidence that *P. avidum* infections are not exclusive to hardware material or contaminated prosthesis, but can be encountered in breast reduction surgery, suggesting the potential biofilm formation on sutures. *Propionibacterium avidum* gives less striking clinical features when compared with other more common pathogens, and may rest underappreciated. Despite the low virulence of the pathogen, it can finally lead to severe morbidity. In breast reduction with long inframammary scars, and in the presence of predisposing factors such as smoking, diabetes or immunosuppression, *P. avidum* contamination may not remain silent. In such cases, the clinician's suspicion should be raised. According to our experience and given the previously reported cases, we suggest an initial IV treatment with amoxicillin–clavulanic acid until the cessation of wound discharge, followed by a 4-week oral course (or until complete wound healing). An US should be considered as a non-invasive and practical way to follow clinical evolution during antibiotic treatment and on an outpatient basis.

CONFLICT OF INTEREST STATEMENT

None declared.

REFERENCES

- Panagea S, Corkill JE, Hershman MJ, Parry CM. Breast abscess caused by *Propionibacterium avidum* following breast reduction surgery: case report and review of the literature. *J Infect* 2005;51:e253–5.
- Levin B, Foo H, Lee A, Gottlieb T. *Propionibacterium avidum* as the cause of severe breast infection following reduction mammoplasty. *ANZ J Surg* 2008;78:318–9.
- Bradbury RS, Warren SJ, Jones DA, Whipp MJ. *Propionibacterium avidum* causing native breast abscess. *Clin Microbiol Newsl* 2011;33:150–1.
- Werno AM, Laird HM, Seaward LM, Short PF, Murdoch DR. Breast abscess caused by *Propionibacterium avidum*. *Clin Microbiol Newsl* 2004;26:70–1.
- Thorek P. Reduction mammoplasty for pendulous breasts. *GP* 1963;27:95–102.
- Funke G, von Graevenitz A, Clarridge JE III, Bernard KA. Clinical microbiology of coryneform bacteria. *Clin Microbiol Rev* 1997;10:125–59.
- Mak TN, Schmid M, Brzuszkiewicz E, Zeng G, Meyer R, Sfanos KS, et al. Comparative genomics reveals distinct host-interacting traits of three major human-associated propionibacteria. *BMC Genomics* 2013;14:640.
- Merritt K, Hitchins VM, Neale AR. Tissue colonization from implantable biomaterials with low numbers of bacteria. *J Biomed Mater Res* 1999;44:261–5.
- Banche G, Roana J, Mandras N, Amasio M, Gallesio C, Allizond V, et al. Microbial adherence on various intraoral suture materials in patients undergoing dental surgery. *J Oral Maxillofac Surg* 2007;65:1503–7.
- Edmiston CE Jr, Krepel CJ, Marks RM, Rossi PJ, Sanger J, Goldblatt M, et al. Microbiology of explanted suture segments from infected and noninfected surgical patients. *J Clin Microbiol* 2013;51:417–21.