

EIGHTEEN-MONTH RESULTS OF INTRAVITREAL ANTI-VASCULAR ENDO-THELIAL GROWTH FACTOR ON VISION AND MICROCIRCULATION IN RADIATION MACULOPATHY

CHIARA M. EANDI, MD, PhD,*† MARIA S. POLITO, MD,* ANN SCHALENBURG, MD,* LEONIDAS ZOGRAFOS, MD*

Purpose: To evaluate 18 months' results of a strict anti-vascular endothelial growth factor protocol for radiation maculopathy following proton therapy in choroidal melanoma.

Methods: Retrospective, comparative, nonrandomized study of 74 radiation maculopathy patients presenting macular lipid deposits, hemorrhages, microaneurysms, cystoid edema, nerve layer infarction, telangiectasia, or capillary nonperfusion. The study group included 52 consecutive patients injected with intravitreal anti-vascular endothelial growth factors (bevacizumab/ranibizumab: 46/6) every two months for the first and every 3 months for the second year, with minimum 12 months' follow-up. The control group consisted of 22 patients having declined this treatment. Best-corrected visual acuity, spectral domain-optical coherence tomography and optical coherence tomography angiography were re-recorded at baseline, 6, 12, and 18 months. The foveal avascular zone and capillary density were measured at the superficial capillary plexus.

Results: Radiation maculopathy was diagnosed at 2 years (1.5–3.5) after proton therapy. Best-corrected visual acuity at baseline, 12 and 18 months improved in the study group from 0.45, 0.3 to 0.2 logarithm of the minimum angle of resolution, but decreased in the control group from 0.5, 0.9 to 1.0 logarithm of the minimum angle of resolution respectively ($P < 0.001$ at 12 months). Simultaneously, foveal avascular zone enlargement was less in the study (from 0.377, 0.665 to 0.744 mm²) than control group (from 0.436, 1.463 to 2.638 mm²) ($P = 0.05$ at 12 months). CMT (280 and 276 μm) and capillary density (37% and 38%, at baseline, respectively) did not evolve significantly different.

Conclusion: Intravitreal anti-vascular endothelial growth factors, every 2 months for the first and every 3 months for the second year, slow down, over up to 18 months, vision loss and anatomical degradation in radiation maculopathy following proton therapy for choroidal melanoma.

RETINA 41:1883–1891, 2021

Radiation maculopathy (RM) is a major complication of conservative radiation therapy for choroidal melanoma,¹ causing significant visual impairment.^{2,3} This late complication is characterized by a microangiopathy of the small retinal vessels secondary to endothelial cell loss, capillary closure, and internal blood retina barrier breakdown.⁴ These vascular injuries induce hypoxic and proliferative changes leading to macular edema, microaneurysms, dilated vessels, lipid deposits, hemorrhages, nerve fiber layer infarction, and retinal pigment epithelium atrophy.^{4,5}

Several clinical studies report on the efficacy of intravitreal anti-vascular endothelial growth factor (VEGF) agents in the management of RM secondary to plaque or proton therapy, either by documenting a regression of the macular edema observed on B-scan optical coherence tomography (OCT)^{5–11} or by demonstrating a reduction in its incidence when administered prophylactically at 2-to4-month intervals.^{4,12,13}

Optical coherence tomography angiography (OCTA) is a recent noninvasive technique that allows a high-resolution visualization of the macular

microvascular structure within the retina. It detects changes of the perifoveal superficial and deep retinal capillary plexus before anatomical changes are visible on spectral domain OCT (SD-OCT) or clinical fundus examination. Moreover, the OCTA analysis software (Angio Tool software) allows a qualitative and quantitative investigation of perifoveal capillary changes in RM. In that respect, recent papers proposed a grading system¹⁴ and described ocular characteristics of RM secondary to plaque or proton therapy based on such a qualitative and quantitative analysis.^{1,15}

We recently reported the short-term results of 2-month interval intravitreal anti-VEGF treatment over a period of 6 months regarding best-corrected visual acuity (BCVA) and foveal avascular zone (FAZ) area on OCTA, demonstrating positive functional results and a limitation of FAZ enlargement in a nonrandomized, comparative study.⁶ The purpose of the present study is to evaluate the effect over 12 to 18 months on visual acuity, retinal thickness, and the superficial capillary plexus assessed by OCTA of an intravitreal anti-VEGF treatment bimonthly for the first year and every 3 months during the second year.

Methods

Study Design and Patient Population

This is an extension of the retrospective, comparative, nonrandomized study previously reported by Daruich et al.⁶ All research procedures described in this study adhered to the tenets of the Declaration of Helsinki and were approved by the ethics committee of the Swiss Federal Health Department (Authorization CER-VD 2016-01861). All participants signed an informed consent.

Clinical charts of choroidal melanoma patients treated with proton therapy between January 2015

From the *Department of Ophthalmology, University of Lausanne, Jules-Gonin Eye Hospital, Fondation Asile des Aveugles, Lausanne, Switzerland; and †Department of Surgical Science, University of Torino, Torino, Italy.

Meeting Presentation: Preliminary results have been presented at the Euretina Meeting in Paris, September 5–8, 2019.

None of the authors has any financial/conflicting interests to disclose.

A. Schalenbourg and L. Zografos contributed equally as last authors.

This is an open-access article distributed under the terms of the Creative Commons Attribution-Non Commercial-No Derivatives License 4.0 (CCBY-NC-ND), where it is permissible to download and share the work provided it is properly cited. The work cannot be changed in any way or used commercially without permission from the journal.

Reprint requests: Chiara M. Eandi, MD, PhD, Department of Ophthalmology, University of Lausanne, Jules-Gonin Eye Hospital, Fondation Asile des Aveugles, 1002 Lausanne Case postale 5143, Lausanne, Switzerland; e-mail: ceandi@gmail.com

and June 2018 were retrospectively reviewed and consecutive treatment-naïve patients diagnosed with radiation maculopathy and a subsequent follow-up of at least 12 months were selected.

The diagnosis of radiation maculopathy was made by a senior medical retina and ocular oncology specialist (L.Z.) and based on the presence of characteristic signs on fundus examination (lipid deposits, hemorrhages, or microaneurysms) and multimodal imaging (cystoid macular edema or nerve fiber layer infarction on SD-OCT, exudative retinal telangiectasia or capillary nonperfusion on fluorescein angiography or capillary loss on OCTA), as previously reported.^{3,6} Only patients with a disrupted deep capillary plexus on OCTA were enrolled. Logarithm of the minimum angle of resolution (LogMAR) and corresponding Snellen-BCVA was measured at each visit. Comprehensive clinical data, SD-OCT, and OCTA images were recorded at baseline, 6 months, 12 months, and 18 months. Each patient was advised to follow a strict anti-VEGF intravitreal injection protocol. Patients who did not accept the strict treatment regimen were included in the control group.

Acquisition and Analysis of Images

The protocol of acquisition and analysis of images has been described in our previous report.⁶ Briefly, SD-OCT and OCTA scans were acquired on the Angiovue RTx 100 device, which is based on the Angiovue Imaging System (Optovue, Inc, Fremont, CA) to obtain amplitude decorrelation angiography images. This instrument has an A-scan rate of 70,000 scans per second, using a light source centered on 840 nm and a bandwidth of 50 nm. Each OCTA volume contains 304 × 304 A-scans with two consecutive B-scans captured at each fixed position and is acquired over 3 seconds. Two consecutive orthogonal OCTA volumes are acquired to perform a motion correction that automatically minimizes the motion artifacts because of microsaccades (i.e., motion correction technology). Using the split-spectrum amplitude-decorrelation angiography algorithm, measurement noise was reduced by splitting the signal into 11 wavelengths. Volumes were automatically segmented by the software to provide images of the superficial plexus (3 μm below the inner limiting membrane to 16 μm below the outer border of the inner plexiform layer). We controlled the correct segmentation for each patient before extracting the data.

Measurements of the FAZ area were performed manually on 3 × 3-mm OCTA scans at the level of the superficial capillary plexus by two masked observers (one retinal photographer and one retina specialist),

using the publicly available ImageJ software (Version 1.50c4, Wayne Rasband; National Institutes of Health, Bethesda, MD). The mean values of these FAZ area measurements were withheld for further analyses. Because our previous study found a higher repeatability of FAZ measurements in the superficial plexus,⁶ we only reported data from the superficial capillary plexus. The capillary density (CD) was automatically calculated by the Angiovue software.

The central macular thickness (CMT) was measured on SD-OCT volumes in the central subfield of an Early Treatment of Diabetic Retinopathy Study grid centered on the fovea. We set the segmentation from the inner limiting membrane to the Bruch membrane. We also analyzed the presence of macular edema (ME), observed on SD-OCT B-scan.

Anti-Vascular Endothelial Growth Factor Treatment Protocol

The treatment protocol consisted of anti-VEGF intravitreal injections with either bevacizumab 1.25 mg/0.05 mL (Avastin; Roche, Basel, Switzerland) (46 patients) or ranibizumab 0.5 mg/0.05 mL (Lucentis; Novartis, Basel, Switzerland) (6 patients) administered at 2-month intervals during 12 months and at 3-month intervals during the second year. Intravitreal injections were performed at our institution or by the referring ophthalmologist. However, the clinical evaluations were carried out at our institution at 6-month intervals. The use of intravitreal VEGF inhibitors is off-label in this condition.

Statistical Analysis

Comparative analyses were conducted between the patients who strictly followed the treatment protocol and those of the control group during the 18-month follow-up.

Continuous variables are expressed as a median (interquartile range), while discrete variables are presented as numbers (n) or percentages (%). Discrete variables were compared with the “chi-square” test. Continuous variables were compared using the Mann–Whitney test. To calculate the differences between the variables at 6-, 12- and 18- months’ follow-up with the baseline values, we employed the “mean paired changes *t*-test”; for this reason, these differences are expressed as a mean \pm SD. We considered results statistically significant when associated with a *P*-value \leq 0.05.

We used the SPSS software version 20.0 (SPSS, Inc, Chicago, IL) for all analyses.

Results

Seventy-four patients with RM were included. Initially, 52 patients strictly adhered to the anti-VEGF injection protocol, forming the study group, whereas 22 patients declined, and were allocated to the control group. In practice, the mean number of intravitreal anti-VEGF injections was 7.3 (6–8) and 0.7 (0–2) for the study and control group, respectively. Patients in the study group received six injections in the first year and two injections in the following 6 months. The number of injections in the control group varied between zero and two in the first year, and none of the control subjects received an injection in the second year.

The demographic characteristics at baseline of both groups are reported in Table 1. Median age was 58 years (49–67) and 69 years (55–74) for the study and control group, respectively. The former group included 20 men (39%) and 32 women (61%), with in the latter 13 men (59%) and 9 women (41%). Six patients in the study group and 3 in the control group were affected by diabetes mellitus Type 2, whereas 13 and 8 had arterial hypertension, respectively. Thirty (58%) patients in the study group and 11 (50%) in the control group presented ME on SD-OCT B-scan examination at baseline. The estimated median radiation dose to the fovea was 48 cobalt grey equivalent (18–60) (percentage of irradiation 55%, range 30%–100%) and 46 cobalt grey equivalent (27–60) (percentage of irradiation 100%, range 45%–100%) for the study and control group, respectively. The median time elapsed since proton therapy before patient enrolment was 2.0 years (1.5–3.5) in the study group and 2.0 years (1.5–3.3) in the control group. No significant differences were found between the two groups for these baseline characteristics, except for the median age (Mann–Whitney test, *P* = 0.03).

The clinical and imaging characteristics of the two groups recorded at baseline, and at the 6-month, 12-month, and 18-month visit are summarized in Table 2. Over time, the number of patients in each group declined, with only 34 patients left in the study group at the 18-month visit, and 14 and 8 patients in the control group after 12- and 18-months’ follow-up respectively.

Median BCVA at baseline was 0.45 (0.60–0.20) LogMAR (Snellen equivalent 20/50 [20/80–20/32]) and 0.50 (0.70–0.30) LogMAR (Snellen equivalent 20/63 [20/100–20/40]) for the study and control group respectively, and the difference was not statistically significant (Mann–Whitney test, *P* = 0.30). Median BCVA in the study group improved to 0.30 (0.50–0.20) LogMAR (Snellen equivalent 20/40 [20/63–20/32]) both at the 6-

Table 1. Baseline Demographic and Treatment Characteristics of the Cohort, Comparing the Study and Control Group

Baseline Demographic and Treatment Characteristics	Study Group (n = 52)	Control Group (n = 22)	P
Median age in years (range)	58 (49–67)	69 (55–74)	0.03*
Male gender: n (%)	20 (39)	13 (59)	0.10*
Diabetes mellitus: n (%)	6 (12)	3 (14)	0.80*
Arterial hypertension: n (%)	13 (25)	8 (36)	0.32*
Median radiation dose to the fovea in cobalt grey equivalent (range)	48 (18–60)	46 (27–60)	0.38†
Median time since proton therapy in years (range)	2.0 (1.5–3.5)	2.0 (1.5–3.3)	0.64†
Macular edema on OCT: n (%)	30 (58)	11 (50)	0.54*

Bold are statistically significant values.

*Chi-square test.

†Mann–Whitney test.

month and 12-month visit, and to 0.20 (0.50–0.20) LogMAR (Snellen equivalent 20/32 [20/63–20/32]) at the 18-month visit. In the control group, the median BCVA decreased continuously during follow-up from 0.80

(1.00–0.30) LogMAR (Snellen equivalent 20/125 [20/200–20/40]), to 0.90 (1.20–0.43) LogMAR (Snellen equivalent 20/160 [20/400–20/50]), and eventually 1.00 (1.50–0.70) LogMAR (Snellen equivalent 20/200 [20/

Table 2. Clinical and Morphologic (Median [Range]) Characteristics of the Cohort at Baseline, 6-, 12-, and 18-Month Visits, Comparing the Study and Control Group

Clinical and Morphological Characteristics	Study Group	Control Group	P*
Baseline	n = 52	n = 22	
BCVA logMar	0.45 (0.60–0.20)	0.50 (0.70–0.30)	0.30
BCVA Snellen equivalent	20/50 (20/80–20/32)	20/63 (20/100–20/40)	
FAZ A, mm ²	0.377 (0.271–0.632)	0.436 (0.275–1.316)	0.47
CD, %	37 (34–43)	38 (35–43)	0.74
CMT, μm	280 (223–340)	276 (201–320)	0.45
CMT subgroup with ME at baseline, μm, n	(n = 30) 335 (193–470)	(n = 11) 309 (155–569)	0.54
6 months	n = 52	n = 22	
BCVA logMar	0.30 (0.50–0.20)	0.80 (1.00–0.30)	<0.001
BCVA Snellen equivalent	20/40 (20/63–20/32)	20/125 (20/200–20/40)	
FAZ A, mm ²	0.537 (0.328–0.938)	0.948 (0.341–3.449)	0.05
CD, %	35 (31–39)	35 (31–38)	0.92
CMT, μm	259 (218–320)	243 (184–296)	0.38
CMT subgroup with ME at baseline, μm, n	(n = 30) 282 (185–439)	(n = 11) 280 (125–566)	0.59
12 months	n = 52	n = 14	
BCVA logMar	0.30 (0.50–0.20)	0.90 (1.20–0.43)	<0.001
BCVA Snellen equivalent	20/40 (20/63–20/32)	20/160 (20/400–20/50)	
FAZ A, mm ²	0.665 (0.353–1.685)	1.463 (0.443–4.027)	0.05
CD, %	33 (31–38)	34 (28–40)	0.97
CMT, μm	257 (216–312) (n = 30)	263 (154–418) (n = 8)	0.96
CMT subgroup with ME at baseline, μm, n	282 (172–444)	287 (125–641)	0.57
18 months	n = 34	n = 8	
BCVA logMar	0.20 (0.50–0.20)	1.00 (1.50–0.70)	<0.001
BCVA Snellen equivalent	20/32 (20/63–20/32)	20/200 (20/640–20/100)	
FAZ A, mm ²	0.744 (0.389–2.098)	2.638 (0.357–4.566)	0.27
CD, %	32 (30–37)	32 (28–40)	0.79
CMT, μm	246 (209–325)	165 (138–299)	0.12
CMT subgroup with ME at baseline, μm, n	(n = 17) 257 (190–464)	(n=4) 295 (165–325)	NA†

Bold are statistically significant values.

*Mann–Whitney test.

†NA, not-available: too few patients in the control group (n = 4).

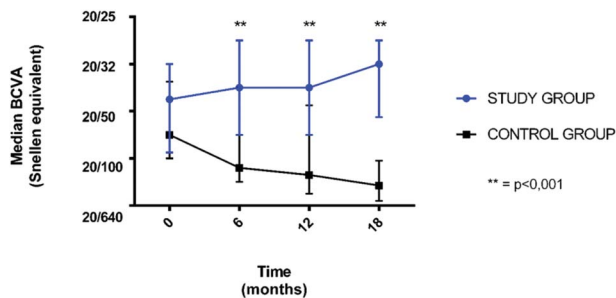


Fig. 1. Evolution of median BCVA (snellen equivalent) following proton therapy (baseline) at the 6-, 12-, and 18-month visits, comparing the study group with the control group.

640–20/100]) at the 6-month, 12-month, and 18-month visit respectively. The differences between the two groups were statistically significant (Mann–Whitney test, $P < 0.001$) (Figure 1).

Concerning the morphological median parameters, the FAZ area was larger in the control group than in the study group and the difference reached statistical significance after 6- and 12-months’ follow-up (Mann–Whitney test, $P = 0.05$) (Figures 2 and 3). Moreover, although the difference in CD loss, and CMT reduction was not statistically significant, a positive trend could be observed between the study and control group. In the subgroup of patients with macular edema at baseline, there was no statistically significant difference of CMT between the two groups at any time point.

The mean differences (\pm SD) between the clinical and imaging variables after 6-, 12- and 18-months’ follow-up compared with those at baseline are reported in Table 3.

In the study group, the FAZ area (mean paired changes t -test, $P = 0.002$, $P < 0.001$, $P = 0.007$), and CD (mean paired changes t -test, $P < 0.001$) were significantly different at each visit, whereas the BCVA (mean paired changes t -test, $P = 0.001$ and $P = 0.02$,

respectively) and CMT (mean paired changes t -test, $P = 0.003$ and $P = 0.01$, respectively) were only significantly different at the 6 and 12-month visit, although, in the subgroup with ME at baseline, CMT remained significantly different at each visit (mean paired changes t -test, $P = 0.04$, $P = 0.03$ and $P = 0.04$ respectively). On the contrary, within the control group, it was only the BCVA which continued to decrease significantly over the 6, 12, and 18-month visits (mean paired changes t -test, $P < 0.001$, $P = 0.003$, $P = 0.002$, respectively), whereas the FAZ area (mean paired changes t -test, $P = 0.01$, $P = 0.02$) was significantly different after 6 and 12 months, and the CD (mean paired changes t -test, $P = 0.02$) only after 6 months.

Discussion

This retrospective, comparative, nonrandomized study evaluates the use of intravitreal anti-VEGF as a treatment for radiation maculopathy secondary to proton therapy in choroidal melanoma patients. In a previous report, we observed less BCVA loss and FAZ enlargement on OCTA over a 6 months’ period in patients treated with intravitreal anti-VEGF than in those of the control group.⁶ In analogy to other protocols,¹⁶ we adopted a strict intravitreal anti-VEGF regimen consisting of injections every 2 months during the first year, and at 3-month intervals in the second year. In the present study, we demonstrate that 2-monthly anti-VEGFs not only reduce progressive vision loss and FAZ enlargement after 6 months, but also after 1 year ($P < 0.001$ and $P = 0.05$, respectively) (Figures 2 and 3). Moreover, although the number of eyes was too small to reach statistically significant conclusions, a positive trend was also observed after 18 months.

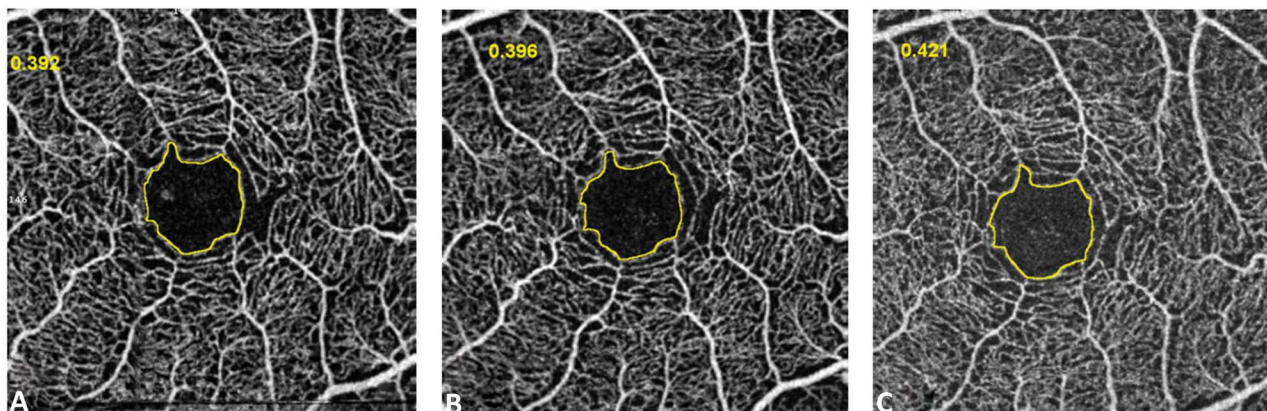


Fig. 2. Absence of significant FAZ area enlargement in a case of radiation maculopathy on OCTA after intravitreal anti-VEGF treatment at 2-month interval during a 12-month period (study group). Foveal avascular zone area (yellow outline) was 0.336 mm² at baseline (A), 0.418 mm² at 6 months (B), and 0.430 mm² at 12 months (C).

Table 3. Mean Variation/Differences of the Clinical and Morphologic Characteristics at 6-, 12-, and 18-Month Visit, Relative to Those at Baseline

Clinical and Morphological Characteristics	Mean (±SD) Differences 6 Months-Baseline		P*		Mean (±SD) Differences 12 Months-Baseline		P*		Mean (±SD) Differences 18 Months-Baseline		P*	
	Study Group	Control Group	Study Group	Control Group	Study Group	Control Group	Study Group	Control Group	Study Group	Control Group	Study Group	Control Group
BCVA logMar	0.07 (±0.14)	-0.13 (±0.10)	0.001	< 0.001	0.06 (±0.17)	-0.21 (±0.22)	0.02	0.003	0.09 (±0.35)	-0.38 (±0.23)	0.13	0.002
FAZ A	0.208 (±0.46)	0.638 (±1.12)	0.002	0.01	0.398 (±0.71)	1.214 (±1.66)	< 0.001	0.02	0.709 (±1.45)	1.660 (±2.54)	0.007	0.11
CD (%)	-2.79 (±5.19)	-2.77 (±5.03)	< 0.001	0.02	-3.83 (±4.84)	-3.85 (±7.45)	< 0.001	0.08	-6.00 (±7.54)	-4.75 (±6.90)	< 0.001	0.09
CMT	-23 (±55)	-15 (±73)	0.003	0.34	-25 (±73)	45 (±203)	0.01	0.46	-20 (±111)	-16 (±204)	0.29	0.82
CMT subgroup with ME at baseline, μm	-40 (±19)	-28 (±56)	0.04	0.63	-42 (±19)	24 (±69)	0.03	0.73	-52 (±24)	-54 (±65)	0.04†	NA‡

Bold are statistically significant values.

*Mean paired changes t-test.

†Mann-Whitney test.

‡NA, not available; too few patients in the control group (n = 4).

These results are consistent with other, non-randomized studies. Shah et al¹¹ reported that 81 of 159 (51%) patients treated with intravitreal bevacizumab for RM secondary to iodine-125 plaque therapy maintained or improved their visual acuity with a mean of five injections over 18 months. Seibel et al¹⁰ described how intravitreal anti-VEGFs stabilized visual acuity and reduced retinal thickness in 35 of 38 (92.1%) eyes with RM secondary to proton therapy over 12 months. Finger et al⁹ preserved BCVA in 96 of 120 (80%) cases presenting RM after palladium-103 or iodine-125 brachytherapy by treating them with continuous intravitreal anti-VEGFs for up to 10 years.

Two recent nonrandomized studies used aflibercept. With a mean of 4.4 intravitreal injections, Fallico et al⁷ improved BCVA and reduced CMT in nine eyes with radiation-induced macular edema after ruthenium-106 plaque therapy over a 24-month follow-up. Murray et al⁸ demonstrated the efficacy of aflibercept in 34 of 40 (85%) RM eyes, independently from the treatment regimen (fixed 6-month vs. treat-and-adjust interval) in a prospective clinical trial over 12 months.

The strength of our study lies in the fact that it has a concurrent, negative control group, as opposed to others who used historical control patients,^{4,11,13} or a positive control group.⁸ Only Shah,¹² had a similar setting but for his prophylactic protocol.

Another strong point of this study is that, besides the usual parameters of BCVA and CMT, we also analyzed morphologic changes, and, comparing with the control group, evaluated quantitatively with OCTA the effects of anti-VEGF treatment on radiation microangiopathy. As a result, we found a significant slowdown of the FAZ area enlargement and CD loss in the treated eyes compared to the nontreated eyes at both 6 and 12 months.

Matet et al³ already showed a correlation between visual acuity and microvascular factors including FAZ area and DCP integrity. In continuity with our previous report,⁶ because of the higher repeatability of FAZ measurement in the SCP compared to the DCP, we only analyzed the modifications at the level of the SCP. Similar findings were reported in recent publications describing OCTA metrics (FAZ area and vessel density) associated with diabetic retinopathy progression and diabetic macular edema development.¹⁷ Incidentally, also for other pathologies there is not yet a consensus whether FAZ dimensions should be measured in the SCP or DCP. Our study illustrates how OCTA metrics such as FAZ area and CD are simple and noninvasive parameters that could be used to monitor disease progression and the response to treatment in eyes with RM.




Fig. 3. Foveal avascular zone area enlargement in a case of radiation maculopathy on OCTA who did not receive intravitreal anti-VEGF injections over a 12-month period (control group). Foveal avascular zone area (yellow outline) was 0.470 mm² at baseline (A), 1.806 mm² at 6 months (B), and 2.614 mm² at 12 months (C).

The mechanisms responsible for FAZ alterations in RM differ from those in other vascular diseases and the effect of VEGF treatment is not fully understood either. Radiation induces DNA damage of the vascular endothelial cells,¹⁸ resulting in cell loss, progressive capillary closure and delayed-onset microangiopathy.¹⁹ There is experimental evidence for the role of bevacizumab in stabilizing the cell cycle and inhibiting mitosis.²⁰ In consequence, a treatment with anti-VEGFs could slow down endothelial cell proliferation, and reduce and delay subsequent capillary occlusion, but without eliminating this process. Our clinical findings support this pathogenetic hypothesis.

Another potential mechanism is derived from observations in the literature where the initial injury to vascular endothelial cells secondary to central nervous system radiation seems to disrupt the blood–brain barrier causing edema and perfusion alterations.^{4,21,22} The subsequent hypoxia causes a VEGF upregulation that is responsible for further blood–brain barrier alterations, leading to neurological damage. Similarly, at the level of the retina we could observe a disruption of the blood–retinal barrier following radiation treatment. Therefore, VEGF inhibition may limit this damage and the subsequent neuronal cell death.⁴

A third hypothesis is inferred from the pathogenetic mechanism underlying the development of microangiopathy and macular edema in diabetic retinopathy, where a high intraocular concentration of VEGF is associated with an overexpression of intercellular adhesion molecule-1, resulting in downstream non-perfusion and capillary dropout.^{23–26} Although diabetic retinopathy differs from the microangiopathy in RM, we speculate that VEGF is also involved in the process. Therefore, regular and long-term anti-VEGF treatment may delay progression of macular edema and capillary ischemia in eyes with RM.

Finally, we speculate that anti-VEGF therapy may impede FAZ enlargement, simply by preventing the edema-induced macular toxicity. In fact, in several diseases, long standing macular edema causes irreversible anatomical alterations, resulting in severe visual loss. Vascular endothelial growth factor inhibition reduces vascular permeability and the consequent fluid accumulation, with its correlated toxicity.

The role of preventive anti-VEGF treatment, administered before RM develops, has not been defined yet. Recently, Kim et al⁴ reported a benefit of bimonthly ranibizumab following proton therapy for small/medium choroidal melanoma. However, the number of treated eyes was too small to drive definitive conclusions. Shah tested 4-monthly bevacizumab, starting immediately following iodine plaque removal, and obtained statistically significantly reduced rates of OCT-evident macular edema ($P = 0.004$), clinically evident radiation maculopathy ($P = 0.001$), moderate vision loss ($P < 0.001$), and poor visual acuity ($P = 0.004$) after 2 years.¹² Recently, the same Philadelphia group confirmed the favorable effect of prophylactic 4-monthly intravitreal bevacizumab for 2 years on the reduction of OCT-evident cystoid macular edema, clinically evident radiation maculopathy and papillopathy, and vision loss up to four years in a retrospective cohort of 1,131 eyes following plaque radiotherapy, when compared with a nonrandomized historical control group.¹³

Limitations of this study include its retrospective design and the insufficient number of eyes with an 18-month follow-up, not allowing a conclusive statistical analysis at this time point. The statistically significant difference in the median age between the two groups is another limitation. In fact, visual prognosis is less favorable in elder patients, which are also those who refused the strict treatment regimen. Moreover, for a

single-center study with its own specific treatment regimen, a comparison with published results is delicate. The use of two different anti-VEGF drugs (bevacizumab and ranibizumab) represents another limitation allowing only to evaluate the general effect of a VEGF inhibition rather than the efficacy of a specific molecule. Finally, OCTA examination presents still limitations in both acquisition, although low quality scans were discarded, and interpretation, because there is still debate whether to use the SCP or DCP for FAZ analysis. Furthermore, the presence of macular edema can affect the quality and segmentation of the OCTA images. However, for this reason, a trained ophthalmologist (L.Z.) controlled the correct segmentation of each examination, to reduce this bias which could have affected the OCTA quantitative data and therefore the results.

In conclusion, intravitreal anti-VEGF treatment, at 2-month intervals for 1 year and at three-months intervals for the second year, is able to slow down over up to 18 months the natural vision loss and anatomical degradation in eyes with radiation maculopathy secondary to proton therapy for choroidal melanoma.

Key words: anti-VEGF, choroidal melanoma, intravitreal treatment, optical-coherence tomography angiography, proton therapy, radiation maculopathy, spectral-domain optical coherence tomography.

Acknowledgments

The authors thank Marc Curchod for technical assistance in image capturing and analysis.

References

- Sellam A, Coscas F, Lumbroso-Le Rouic L, et al. Optical coherence tomography angiography of macular features after proton beam radiotherapy for small choroidal melanoma. *Am J Ophthalmol* 2017;181:12–19.
- Parrozzani R, Midena E, Trainiti S, et al. Identification and classification of macular biomarkers related to visual acuity in radiation maculopathy: a multimodal imaging study. *Retina* 2020;40:1419–1428.
- Matet A, Daruich A, Zografos L. Radiation maculopathy after proton beam therapy for uveal melanoma: optical coherence tomography angiography alterations influencing visual acuity. *Invest Ophthalmol Vis Sci* 2017;58:3851–3861.
- Kim IK, Lane AM, Jain P, et al. Ranibizumab for the prevention of radiation complications in patients treated with proton beam irradiation for choroidal melanoma. *Trans Am Ophthalmol Soc* 2016;114:T2.
- Reichstein D. Current treatments and preventive strategies for radiation retinopathy. *Curr Opin Ophthalmol* 2015;26:157–166.
- Daruich A, Matet A, Schalenbourg A, Zografos L. Intravitreal anti-vascular endothelial growth factor treatment at 2-month intervals reduces foveal avascular zone enlargement and vision loss in radiation maculopathy: a Pilot Study. *Retina* 2019;39:1519–1526.
- Fallico M, Reibaldi M, Avitabile T, et al. Intravitreal aflibercept for the treatment of radiation-induced macular edema after ruthenium 106 plaque radiotherapy for choroidal melanoma. *Graefes Arch Clin Exp Ophthalmol* 2019;257:1547–1554.
- Murray TG, Latiff A, Villegas VM, Gold AS. Aflibercept for radiation maculopathy study: a prospective, randomized clinical study. *Ophthalmol Retina* 2019;3:561–566.
- Finger PT, Chin KJ, Semenova EA. Intravitreal anti-VEGF therapy for macular radiation retinopathy: a 10-year study. *Eur J Ophthalmol* 2016;26:60–66.
- Seibel I, Hager A, Riechardt AI, et al. Antiangiogenic or corticosteroid treatment in patients with radiation maculopathy after proton beam therapy for uveal melanoma. *Am J Ophthalmol* 2016;168:31–39.
- Shah NV, Houston SK, Markoe AM, et al. Early SD-OCT diagnosis followed by prompt treatment of radiation maculopathy using intravitreal bevacizumab maintains functional visual acuity. *Clin Ophthalmol* 2012;6:1739–1748.
- Shah SU, Shields CL, Bianciotto CG, et al. Intravitreal bevacizumab at 4-month intervals for prevention of macular edema after plaque radiotherapy of uveal melanoma. *Ophthalmology* 2014;121:269–275.
- Shields CL, Dalvin LA, Chang M, et al. Visual outcome at 4 years following plaque radiotherapy and prophylactic intravitreal bevacizumab (every 4 months for 2 years) for uveal melanoma. Comparison with nonrandomized historical control individuals. *JAMA Ophthalmol* 2020;138:136–146.
- Veverka KK, AbouChehade JE, Iezzi RJ, Pulido JS. Noninvasive grading of radiation retinopathy: the use of optical coherence tomography angiography. *Retina* 2015;35:2400–2410.
- Shields CL, Say EA, Samara WA, et al. Optical coherence tomography angiography of the macula after plaque radiotherapy of choroidal melanoma: comparison of irradiated versus non-irradiated eyes in 65 patients. *Retina* 2016;36:1493–1505.
- Mantel I, Schalenbourg A, Bergin C, et al. Prophylactic use of bevacizumab to avoid anterior segment neovascularization following proton therapy for uveal melanoma. *Am J Ophthalmol* 2014;158:693–701.
- Sun Z, Tang F, Wong R, et al. OCT Angiography metrics predict progression of diabetic retinopathy and development of diabetic macular edema: a prospective study. *Ophthalmology* 2019;126:1675–1684.
- Horgan N, Shields CL, Mashayekhi A, Shields JA. Classification and treatment of radiation maculopathy. *Curr Opin Ophthalmol* 2010;21:233–238.
- Archer DB, Gardiner TA. Ionizing radiation and the retina. *Curr Opin Ophthalmol* 1994;5:59–65.
- Rusovici R, Patel CJ, Chalam KV. Bevacizumab inhibits proliferation of choroidal endothelial cells by regulation of the cell cycle. *Clin Ophthalmol* 2013;7:321–327.
- Nordal RA, Nagy A, Pintilie M, Wong CS. Hypoxia and hypoxia-inducible factor-1 target genes in central nervous system radiation injury: a role for vascular endothelial growth factor. *Clin Cancer Res* 2004;10:3342–3353.
- Li YQ, Ballinger JR, Nordal RA, et al. Hypoxia in radiation-induced blood-spinal cord barrier breakdown. *Cancer Res* 2001;61:3348–3354.
- Busch C, Wakabayashi T, Sato T, et al. Retinal microvasculature and visual acuity after intravitreal aflibercept in diabetic macular edema: an optical coherence tomography angiography study. *Sci Rep* 2019;9:1561.

24. Miyamoto K, Khosrof S, Bursell SE, et al. Vascular endothelial growth factor (VEGF)-induced retinal vascular permeability is mediated by intercellular adhesion molecule-1 (ICAM-1). *Am J Pathol* 2000;156:1733–1739.
25. Jousseaume AM, Poulaki V, Qin W, et al. Retinal vascular endothelial growth factor induces intercellular adhesion molecule-1 and endothelial nitric oxide synthase expression and initiates early diabetic retinal leukocyte adhesion in vivo. *Am J Pathol* 2002;160:501–509.
26. Ishida S, Yamashiro K, Usui T, et al. Leukocytes mediate retinal vascular remodeling during development and vasoobliteration in disease. *Nat Med* 2003;9:781–788.