

# Original articles

## Understanding scuba diving fatalities: carbon dioxide concentrations in intra-cardiac gas

Vincent Varlet<sup>1</sup>, Alejandro Dominguez<sup>2</sup>, Marc Augsburger<sup>1</sup>, Maisy Lossois<sup>3</sup>, Coraline Egger<sup>2,3</sup>, Cristian Palmiere<sup>3</sup>, Raquel Vilarino<sup>2,3</sup>, Silke Grabherr<sup>2,3</sup>

<sup>1</sup> Forensic Chemistry and Toxicology Unit, University Centre of Legal Medicine Lausanne – Geneva, Switzerland

<sup>2</sup> Forensic Imaging Unit, University Centre of Legal Medicine Lausanne – Geneva, Switzerland

<sup>3</sup> Forensic Medicine Unit, University Center of Legal Medicine Lausanne – Geneva, Switzerland

**Corresponding author:** Vincent Varlet, Forensic Chemistry and Toxicology Unit, University Centre of Legal Medicine Lausanne – Geneva, CH-1011 Lausanne, Switzerland  
vincent.varlet@chuv.ch

### Abstract

(Varlet V, Dominguez A, Augsburger M, Lossois M, Egger C, Palmiere C, Vilarino R, Grabherr S. Understanding scuba diving fatalities: carbon dioxide concentrations in intra-cardiac gas. *Diving and Hyperbaric Medicine*. 2017 June;47(2):76-82.)

**Introduction:** Important developments in the diagnosis of scuba diving fatalities have been made thanks to forensic imaging tool improvements. Multi-detector computed tomography (MDCT) permits reliable interpretation of the overall gaseous distribution in the cadaver. However, due to post-mortem delay, the radiological interpretation is often doubtful because the distinction between gas related to the dive and post-mortem decomposition artifactual gases becomes less obvious.

**Methods:** We present six cases of fatal scuba diving showing gas in the heart and other vasculature. Carbon dioxide (CO<sub>2</sub>) in cardiac gas measured by gas chromatography coupled to thermal conductivity detection were employed to distinguish decomposition from embolism based on the detection of decomposition gases (hydrogen, hydrogen sulfide and methane) and to confirm arterial gas embolism (AGE) or post-mortem offgassing diagnoses. A Radiological Alteration Index (RAI) was calculated from the scan.

**Results:** Based on the dive history, the intra-cadaveric gas was diagnosed as deriving from decomposition (1 case, minimal RAI of 61), post-mortem decompression artifacts (two cases, intermediate RAI between 60 and 85) and barotrauma/AGE (three cases, maximal RAI between 85 and 100), illustrating a large distribution inside the bodies.

**Conclusion:** MDCT scans should be interpreted simultaneously with compositional analysis of intra-cadaveric gases. Intra-cadaveric gas sampling and analysis may become useful tools for understanding and diagnosing scuba diving fatalities. In cases with short post-mortem delays, the CO<sub>2</sub> concentration of the cardiac gas provides relevant information about the circumstances and cause of death when this parameter is interpreted in combination with the diving profile.

### Key words

Gases; Diving deaths; Drowning; Decompression sickness; Air embolism; Arterial gas embolism

---

### Introduction

Decompression stops during scuba diving ascent are recommended to avoid desaturation of the diving gas initially dissolved in the tissue during the dive. If this equilibration time is not respected, dissolved gases are released, causing decompression sickness (DCS). Pulmonary barotrauma may also result in arterial gas embolism (AGE) that could be fatal if the diver is not rapidly placed under hyperbaric conditions. As a result, the intra-cadaveric gas distribution is an important parameter for medical examination of scuba diving fatalities. Gas release can be noticeable in the intravascular system and soft tissues but must be interpreted in regards to the diving profile, macroscopic signs observed during the autopsy and the post-mortem delay.

Indeed, intra-cadaveric gases in scuba diving fatalities can originate from five distinct sources: AGE; DCS, which can also lead to fatal gas embolism according to the magnitude of decompression (even if marginal); post-mortem decompression (off-gassing); resuscitation procedures and decomposition.<sup>1</sup> Barotrauma followed by gas embolism represent the primary cause of scuba diving fatalities where intra-cadaveric gases are present. As loss of consciousness often occurs, signs of drowning are also frequently diagnosed.<sup>2</sup> Severe neurological DCS, which can cause drowsiness and loss of consciousness, can lead to drowning, a scuba diving fatality caused by DCS is difficult to diagnose because of post-mortem decompression, decomposition and resuscitation procedures that cause artifactual intra-cadaveric gases. Post-mortem decompression occurs when the diver dies during the dive and begins right after death; the magnitude of the phenomenon

could increase when the body is brought to the surface quickly.<sup>3</sup> This process produces both intravascular and soft-tissue gas and theoretically should be distinguishable from AGE by the presence of gas in the muscles and joints. Resuscitation procedures can also introduce artefactual gases into the body. With an endotracheal tube and positive pressure ventilation, resuscitation gases (air and oxygen) are frequently noticed in the body. Finally, according to the post-mortem delay, microorganisms in the body can generate decomposition gases. Environmental parameters, such as water and ambient temperatures, the diving suit and body storage conditions are important for the interpretation of the distribution and composition of intra-cadaveric gases.

Before the development of forensic imaging, autopsies of divers were performed following specific protocols, such as underwater dissection, to gather evidence about the release of gas.<sup>1</sup> Other sampling tools such as aspirimeters were used but were not precise, and they were valid only for significant amounts of gas. Today, forensic imaging tools such as multi-detector computed tomography (MDCT) are helpful for detecting the presence of gas in cadavers.<sup>4</sup> MDCT has been employed to investigate gas distribution after scuba diving fatalities.<sup>5</sup> Reliable distribution patterns have been proposed and should confirm the results of the autopsy.<sup>6</sup> In parallel, other studies have developed the Radiological Alteration Index (RAI) based on the volume and distribution of post-mortem gases in the body to estimate its decomposition state.<sup>7,8</sup> However, with scan images only, it is impossible to attribute definitively the presence of gas to scuba diving accidents or to decomposition due to the post-mortem delay. Moreover, if post-mortem decompression and resuscitation procedures are taken into account, the medicolegal diagnosis becomes even more complex. Consequently, the analysis of the composition of intra-cadaveric gases becomes essential for accurate diagnosis of fatal dives and is required to exclude decomposition as a potential source of gas generation.

We aimed to present a useful protocol for intra-cadaveric gas sampling and analysis and to evaluate the relevance of gaseous intracardiac carbon dioxide (CO<sub>2</sub>) concentrations in six fatal dive cases. To our knowledge, intracardiac CO<sub>2</sub> concentrations related to the diving profile for the diagnosis of diving fatalities is reported here for the first time.

### Case reports

The bodies of six deceased scuba divers were studied as part of prosecutor investigations. All underwent a full-body CT scan followed by a complete external exam and all but one (Case 1) of them had an autopsy. Table 1 summarises some of the findings and the attributed cause of death.

#### CASE 1

The body (fresh state) of an experienced, 37-year-old (y.o.) male diver was found at a depth of 28 metres' fresh

water (mfw) in a lake. Air was used as the diving gas. The victim was testing new material for a scuba diving drysuit. The maximum depth reached was 33.5 mfw for a bottom time of 15 minutes (min). At the eighteenth minute, at 26 mfw, an alarm indicating a dangerously rapid ascent was registered by the diving computer. One minute later, the victim reached 17 mfw before an immediate descent. After a total diving time of 20 min, the body depth stabilized at 29 mfw. No activity was registered from this moment until being recovered 2 hours (h) 18 min later. No resuscitation was performed. The death was attributed to drowning because of the characteristic foam cone exuding from the mouth. An autopsy was not required by the prosecutor. However, a post-mortem CT examination was carried out and water in the lungs, compatible with drowning, and the presence of gas in all the vessels and organs, including the heart cavity, compatible with a scuba diving fatality, were entered as evidence. The intra-cadaveric gaseous composition was 32.7  $\mu\text{mol}\cdot\text{ml}^{-1}$  of nitrogen (N<sub>2</sub>) and 9.0  $\mu\text{mol}\cdot\text{ml}^{-1}$  of CO<sub>2</sub> (mean of concentrations measured in left and right ventricles) without the presence of decomposition gases) (Table 2).

#### CASE 2

The body (fresh state) of a 71 y.o., experienced, male diver was found at 4 mfw in a lake. Air and nitrox49 (49% O<sub>2</sub>, 51% N<sub>2</sub>) were used as diving gases and no resuscitation was performed. According to his diving computer, a maximum depth of 42 mfw was reached after 23 min, followed by an ascent to 25 mfw, reached after 37 min, followed by a rapid ascent to the surface where the victim showed signs of dizziness, followed by a descent to 14 mfw. The victim was hauled up to 4 mfw by his diving partner, who then finished his decompression stops when the victim was no longer responding. The body was brought to the surface by a police diving team. Autopsy was carried out at our institute. A post-mortem CT examination showed gas present in all the vessels and organs, including the heart cavity, and was entered as evidence. Cause of death was not determined at the autopsy but signs of pulmonary barotrauma, gas embolism and ante-mortem pathologies (moderate obstructive pulmonary disease and mild atherosclerosis of the coronary arteries) were identified. The intra-cadaveric gaseous composition was 30.1  $\mu\text{mol}\cdot\text{ml}^{-1}$  of N<sub>2</sub> and 11.6  $\mu\text{mol}\cdot\text{ml}^{-1}$  of CO<sub>2</sub> without the presence of decomposition gases (Table 2).

#### CASE 3

The body (fresh state) was of a 58 y.o. male diver who died on the beach after scuba diving in a lake. Air was used as the diving gas and a descent of 15 mfw over 20 min was planned. At 9 mfw, the victim felt signs of drowsiness and began an ascent with his partner. Once at the surface, the victim lost consciousness and was hauled out of the water. Basic life support (BLS) was performed without success. An autopsy was carried out at our institute. Natural death with

**Table 1**  
Case summaries (all male)

Case	Age (y)	Postmortem delay before sampling (h)	Radiological alteration index	Diving/embolism gas	Cardiac sampling site	Cause of death
1	37	< 12	85	Air	R and L ventricles	Drowning
2	71	< 24	100	Air + Nitrox49	R ventricle	Undetermined (barotrauma/AGE + other pathology); drowning excluded
3	58	40	61	Air	R atrium	Natural death (body stored at + 4°C); + cardiac pathology
4	44	30	60	Nitrox32 + Trimix	R heart	Drowning
5	53	12	100	Air + Nitrox32	R atrium	Drowning + DCS + barotrauma/AGE
6	42	38	85	Nitrox23	Heart	Drowning (body stored at +4°C) + barotrauma/AGE + DCS

cardiac pathologies (cardiac hypertrophy, atherosclerotic disease of aorta and its branches, coronary atherosclerosis) was diagnosed as the cause of the death. The intra-cadaveric gaseous composition was  $1.2 \mu\text{mol}\cdot\text{ml}^{-1}$  of  $\text{O}_2$ ,  $30.6 \mu\text{mol}\cdot\text{ml}^{-1}$  of  $\text{N}_2$ ,  $9.2 \mu\text{mol}\cdot\text{ml}^{-1}$  of  $\text{CO}_2$  and  $0.6 \mu\text{mol}\cdot\text{ml}^{-1}$  of hydrogen ( $\text{H}_2$ ) (Table 2). The presence of  $\text{H}_2$  indicated decomposition in conformity with the post-mortem delay of approx. 40 h.

#### CASE 4

The body (fresh state) of a 44 y.o. male diver was found at 95 mfw in a lake. The diving equipment included a rebreather and cylinders of air, nitrox32 (32%  $\text{O}_2$ , 68%  $\text{N}_2$ ), trimix (helium, nitrogen and oxygen) and  $\text{O}_2$ . The diving computer recorded a maximum depth of 80 mfw after 20 min, followed by an ascent to 70 mfw after 5 more min, and then a descent to 90 mfw at approximately 30 min. An ascent to 70 mfw over 5 min was registered, followed by stabilization around 65 mfw and a rapid descent to 95 mfw, the depth recorded after a diving time of 40 min. The  $\text{O}_2$  monitoring during the dive showed a hyperoxic period during the last 10 min of the dive, which was hypothesized to be a factor in the drowsiness and loss of consciousness leading to drowning. The post-mortem CT examination and autopsy were carried out at our institute where we diagnosed the absence of barotrauma, but confirmed the presence of water in the lungs and gas in all the vessels and organs, including the heart cavity. The death was attributed to drowning, and the gas presence was attributed to post-mortem decompression. The intra-cadaveric gaseous composition was  $29.3 \mu\text{mol}\cdot\text{ml}^{-1}$  of  $\text{N}_2$  and  $11.7 \mu\text{mol}\cdot\text{ml}^{-1}$  of  $\text{CO}_2$  without the presence of decomposition gases despite a post-mortem delay of 36 h (with 20 h at 95 mfw at 6°C) (Table 2).

#### CASE 5

The body (fresh state) of a 53 y.o. male diver was found 100 m off the beach floating at the surface of a lake. Twin

cylinders, one of air and one of nitrox32 and a cylinder of  $\text{O}_2$  were used as the breathing mixtures. Nitrox32 was used during the descent between 6 and 40 mfw, followed by air between 40 and 80 mfw. The diving computer recorded an ascent after less than one minute to 65 mfw, followed by a first stop for 4 min between 65 and 68 mfw, a second stop of approximately 1 min at 21 mfw, followed by surfacing. According to the police dive team, 39 min of decompression were needed to avoid a decompression accident. The body was found 75 min after the beginning of the dive and BLS and defibrillation were unsuccessful. The post-mortem CT examination and autopsy were carried out 12 h later at our institute where we diagnosed the absence of massive barotrauma, but confirmed the presence of liquid in the lungs and gas in all the vessels and organs, including the heart cavity. The death was attributed to drowning in the context of barotrauma followed by AGE and DCS. The intracardiac gaseous  $\text{CO}_2$  concentration was  $16 \mu\text{mol}\cdot\text{ml}^{-1}$  without the presence of decomposition gases (Table 2).

#### CASE 6

The body (fresh state) of a 42 y.o. male diver was found floating at the surface of a lake. Two cylinders of nitrox23 were used as the diving gas and a descent to 45 mfw for 32 min, followed by a rapid ascent with alarm, were recorded by his diving computer. The body was found 45 min after the beginning of the dive. BLS and defibrillation were unsuccessful. The post-mortem CT examination and the autopsy were carried out at our institute where we diagnosed the absence of massive barotrauma, but confirmed the presence of liquid in the lungs and gas in all the vessels and organs, including the heart cavity. The death was attributed to drowning in the context of barotrauma followed by AGE and DCS. The intra-cadaveric gaseous composition was  $1.2 \mu\text{mol}\cdot\text{ml}^{-1}$  of  $\text{O}_2$ ,  $30.2 \mu\text{mol}\cdot\text{ml}^{-1}$  of  $\text{N}_2$  and  $10.2 \mu\text{mol}\cdot\text{ml}^{-1}$  of  $\text{CO}_2$  without the presence of decomposition gases (Table 2).

## Materials and methods

### COLLECTION OF GAS SAMPLES FROM THE BODIES

Gas sampling was performed percutaneously with MDCT following a standardized protocol recently developed at our centre.<sup>8,9</sup> Gas bubbles were detected by MDCT on a native CT scan and the RAI was calculated for each case. By using the biopsy mode, which corresponds to radiological guidance, it was possible to target the gaseous region to be punctured. A three-way tap in the closed position was mounted on a needle and introduced into the gaseous cavity using the three-dimensional coordinates. A second CT scan was performed to check the position of the needle. A Luer-lock PTFE syringe was then mounted on the tap which was slowly opened and gas was sampled. Then, the three-way tap was closed and the system (syringe + tap + needle) removed from the body. Gas volumes were sampled from various anatomical sites of interest (Table 3). The gas samples were individually transferred into a headspace (HS) glass vial of 20 ml, preliminarily filled with stabilized (de-gassed) water heated for 3 h at 60°C, then kept in the fridge (+4°C) until analysis, i.e., not less than 48 h for all cases although the in-vial stability of gases was satisfactory for up to eight weeks. Two needles were inserted through the septum: the system needle (syringe + tap + needle) and another simple needle. The transferred gas displaced the water, which could be evacuated through the second needle. The residual water had to be removed to permit complete airtightness. The vials were stored upside down in the fridge until analysis.

### REAGENTS

All the analytical gases used were from Carbagas (Lausanne, Switzerland), including certified CO<sub>2</sub>, hydrogen sulphide, carbon monoxide, nitrous oxide and methane. Atmospheric air was used as the source for O<sub>2</sub> and N<sub>2</sub> calibration.

### GAS CHROMATOGRAPHY-THERMAL CONDUCTIVITY DETECTION/MASS SPECTROMETRY ANALYSIS (GC-MS/TCD)

An Agilent 6890N GC (Agilent Technologies, Palo Alto, CA) combined with a headspace gas autosampler and equipped with an Agilent Select Permanent Gases column arrangement was used. This column arrangement is specially designed for gas analysis and contains two capillary columns in parallel: a molecular sieve 5 Å PLOT capillary column (10 m x 0.32 mm i.d.) and a Porabond Q (50 m x 0.53 mm i.d.), allowing for the separation of CO<sub>2</sub>. A three-way valve was mounted at the end of the capillary column into the gas chromatograph, enabling the analysates to be directed to a thermal conductivity detector (TCD) or to an Agilent 5973 mass spectrometer (MS) (Agilent Technologies, Palo Alto, CA). The temperature was set to isothermal (45°C) and was held for 8 min and the injector (splitless mode) was set to 100°C. Helium was employed as the carrier gas (8 ml·min<sup>-1</sup> constant flow). The gas identification was

performed by the injection of gas standards and mass spectra. The MS was operating in the electron ionization mode (EI) at 70 eV with an ion source temperature of 230°C. The analyzer temperature was set to 150°C and the interface MS temperature to 250°C. Signals were acquired in full scan mode (2–100 amu). The gas quantification was performed with the TCD at 150°C, calibrated for each gas with standard gases.<sup>9</sup> Thus, intra-cadaveric CO<sub>2</sub> measurements are expressed in μmol·ml<sup>-1</sup> HS. The other gases, such as methane, oxygen, nitrogen, hydrogen sulfide and hydrogen, are weakly dissolved in water and do not affect the quantification.

### RADIOLOGICAL ALTERATION INDEX

The RAI is derived from post-mortem MDCT data from more than 100 non-traumatically deceased people and was validated by 100 additional scanned bodies retrospectively examined by two independent observers.<sup>7</sup> The RAI was developed to document the internal gas presence in cadavers and is based on the amount of gas present in seven defined anatomical sites (the left innominate vein, subcutaneous pectoral tissue, heart, liver, kidneys, abdominal aorta and the third lumbar vertebra).<sup>9</sup> Gas quantity was assessed by a scoring system using four grades ranging from 0 to III: 0 for no gas, I for one to a few bubbles of gas, II for a structure partially filled with gas and III for a structure completely filled with gas. Using the statistical method of linear regression, each anatomical site was weighted using regression coefficients with an adjustment to a maximum of 100. The RAI value, therefore, ranges from no gas (0) to the extensive presence of gas in all tissues (100).

## Results

The origin of intra-cadaveric gases in our case series is attributed to decomposition in one case (Case 3), post-mortem decompression artifacts in two cases (Cases 1 and 4) and barotrauma/AGE in three cases (Cases 2, 5 and 6). The RAI of Case 3 was minimal (61), those of Cases 1 and 4 were intermediate (between 60 and 85) whereas the RAI of Cases 2, 5 and 6 were maximal (between 85 and 100), showing a large distribution of gases within the bodies.

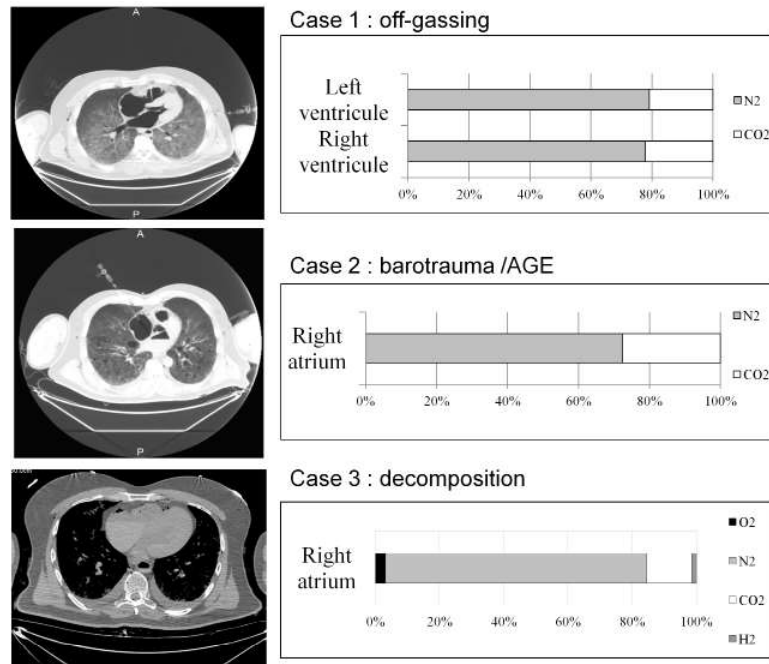
The gas compositions measured at intra-cadaveric sampling sites are shown in Tables 2 and 3. For cases with high RAI, CO<sub>2</sub> was also noticeable in various anatomical sites (Table 3). Lower CO<sub>2</sub> concentrations were found in the femoral artery in Case 3 and femoral vein in Case 4. The concentration of gaseous CO<sub>2</sub> in other sites appears related to the RAI; however, this is variable and the CO<sub>2</sub> concentrations seem somewhat randomly distributed through the body. Example CT-scan cardiac images and intra-cardiac gas compositions are shown for three cases in Figure 1.

## Discussion

The current challenge in evaluating deceased divers is distinguishing between intravascular/intracardiac gas that

**Figure 1**

CT-scan images and cardiac gas composition of three of the cases to illustrate the differences seen in divers at post-mortem



**Table 2**

Intracardiac gas composition in six divers following fatal diving incidents; gas concentration in  $\mu\text{mol}\cdot\text{ml}^{-1}$ ; \* av. of two readings

Diver	Oxygen	Nitrogen	Carbon dioxide	Hydrogen
1	?	32.7	9.0*	nil
2	?	30.1	11.6	nil
3	1.2	30.6	9.2	0.6
4	?	29.3	11.7	nil
5	?	?	16.0	nil
6	1.2	30.2	10.2	nil

is the result of true pulmonary barotrauma/AGE versus post-mortem off-gassing of the inert gas that dissolved in the diver's tissues during the dive. Decomposition gases are another challenge for the forensic radiologist evaluating CT scans and can lead to false interpretations.

**DECOMPOSITION**

The literature is scarce concerning this topic. Several animal studies have been conducted, while only a few have included

human divers.<sup>10-13</sup> One study dealt with the intravascular gas composition occurrence in non-diving and diving autopsies in relation to the resuscitation operations and decomposition processes.<sup>14</sup> Another study focused on the diagnosis of massive gas embolism in the cerebral and spinal arteries using CT and MRI investigations.<sup>15</sup>

The cardiac gas composition and CT scan results for Case 3 are displayed in Figure 1. The cardiac bubble volume was small and the cause of death was diagnosed as natural due to cardiac pathologies (thrombosis). The RAI of 61 is rather moderate in the context of scuba diving, indicating that the intra-cadaveric gas occurrence was not generalized. The presence of H<sub>2</sub>, as an indicator of decomposition, indicates that the CT scan cannot be taken into account when studying the relationship between the presence of intra-cadaveric gas and the dive. This result is also supported by a post-mortem delay of 40 h, even though the body was stored at a cold temperature. As the decomposition process can occur very rapidly after death, following the protocol for intra-cadaveric gas sampling and analysis, it is easy to distinguish embolism gases from those caused by early decomposition.

**Table 3**

CO<sub>2</sub> concentrations ( $\mu\text{mol}\cdot\text{ml}^{-1}$ ) in gases sampled from cardiac cavities and various veins and arteries in six deceased divers

	Right atrium	Right ventricle	Left ventricle	Heart	Jugular vein	Femoral artery	Femoral vein	Subclavian vein
Case 1		9.2	8.7					
Case 2	11.6				17.1			20.4
Case 3	9.2						5.7	
Case 4				11.7		9.1		7.4
Case 5	16.0					12.0	24.0	
Case 6				10.2		7.2		10.5

## BAROTRAUMA/AGE VERSUS OFF-GASING

The cardiac gas composition and cardiac bubble volumes are important (>10 ml) in ascribing the cause of death in Cases 1 and 4 as drowning. The origin of intra-cadaveric gases in these cases was attributed to off-gassing because the bodies were found at 29 mfw and 95 mfw, respectively. No decomposition gas was detected but the cardiac CO<sub>2</sub> concentrations differed, possibly showing the effect of depth and diving time on the off-gassing magnitude – in long and deep dives, the amount of dissolved gases in the blood is higher relative to shorter, shallower depths. As a result, the CO<sub>2</sub> concentration in the cardiac gas of Case 1 (20 min at -30 mfw max.) is lower than that of Case 4 (40 min at 95 mfw max.) (Table 2). It should be noted that the RAI, initially developed to rank decomposition states of the body, is important but not maximal. As decomposition is excluded, this parameter illustrates the presence and distribution of intra-cadaveric gases. In these cases, off-gassing cases the fact that the RAI was not maximal shows a heterogeneous distribution relative to decomposition. Indeed, decomposition occurs first in specific areas such as the abdominal cavity.

The origin of intra-cadaveric gases in Cases 5 and 6 was attributed to drowning in the context of barotrauma followed by AGE/DCS since autopsy evidence clearly indicated both aetiologies. The diving profiles showed rapid ascents to the surface. For Case 2, no signs of drowning were noted but signs of pulmonary barotrauma were observed. No decomposition gases were detected. The cardiac CO<sub>2</sub> concentrations in Case 2 (11.6 µmol·ml<sup>-1</sup>), Case 5 (16 µmol·ml<sup>-1</sup>) and Case 6 (10.2 µmol·ml<sup>-1</sup>) may show the effect of depth and the ascent speed on the magnitude of barotrauma/AGE. A rapid ascent from a deep depth will likely result in the release of more gas (and consequent injuries) than would ascent from shallower, even though the greatest proportional pressure/volume changes occur close to the surface. Cases 2 and 6 had ascents from intermediate depths over approximately 2–4 min, whereas Case 5 ascended from 70 msw in 2 min.

However, the RAI scores in these three divers ranged from 85 to 100 (maximum), showing that, in the absence of decomposition, the intra-cadaveric gases were widely distributed inside the body. If we compare the RAI calculated in both categories (barotrauma/AGE and off-gassing groups), the RAI scores are higher for the barotrauma/AGE group. After excluding decomposition as the eventual source of intra-cadaveric gas origin, this parameter may be very useful for differentiating barotrauma/AGE and off-gassing fatalities, especially in the case of deep dives. Indeed, the distribution and volume of intra-cadaveric gas bubbles in deep diving seems to be higher for a rapid ascent leading to barotrauma/AGE compared to cases of off-gassing.

Cardiac gaseous CO<sub>2</sub> cannot constitute a diagnostic parameter by itself because the values are similar for cases of important off-gassing and barotrauma/AGE in shallow

to medium depth dives (10 to 12 µmol·ml<sup>-1</sup>; Table 2). More cases are needed to improve its predictive power in scuba diving fatalities. Indeed, several sources could explain the CO<sub>2</sub> variation, such as sampling delay and potential diffusion from the tissues after death. However, once the origin of intra-cadaveric gases is determined, the concentration of cardiac CO<sub>2</sub> increases with the depth and duration of the dive.

## THE INFLUENCE OF RESUSCITATION

It is of crucial importance to document the conditions and the occurrence of resuscitation.<sup>3</sup> The more active the resuscitation, the higher the risk of actively releasing dissolved gases. However, resuscitation can also cause the elimination of gas released through the lungs and exhaled. Mechanical ventilation with either air or oxygen and the duration of cardiopulmonary resuscitation could also influence the intracardiac gas composition.<sup>16</sup> Moreover, even if no resuscitation occurs, body handling can also generate gas release artifacts. As a result, each scuba diving fatality should be interpreted with regards to the specific resuscitation protocol and diving conditions, such as dive computer information and diving gas.

## THE INFLUENCE OF THE SAMPLING SITE

The previously published studies performed on animals were not focused on the cardiac region but took into consideration the whole body or intestinal zones, especially to differentiate gas embolism from putrefaction.<sup>12,13</sup> Among the research using human data, none of the published studies assessed the anatomical precision of gas sampling.<sup>14,15</sup> However, according to the sampling site, the embolism gas composition can differ. The different biochemical properties of the tissues in which the diving gas is dissolved can be responsible for differences in the gas composition (the volume of gas released, elasticity and diameter of vessels and the amount of blood, etc.). In the diving context, the magnitude and nature of the embolic gas, its composition sampled from different intravascular sites varies, as was seen in these cases. However, the CO<sub>2</sub> concentrations seem not to be well correlated to the circumstances of the gas embolism.

## THE NATURE OF THE DIVING GAS

The intracardiac gaseous CO<sub>2</sub> concentrations appear to be independent of the nature of the embolism gas. In the cases presented herein, the diving gases were all different: variously nitrox (23, 32, 49% O<sub>2</sub>), air and oxygen. As a result, CO<sub>2</sub> concentrations in the intracardiac gas are more closely linked to the desaturation kinetics and the volume of embolism gas than to its nature.<sup>16</sup> However, the analytical methodology used in the gas analysis protocol can also be employed to detect other gases such as argon or helium.<sup>17,18</sup> Helium is used in trimix whereas argon is used by some divers for thermal insulation in the drysuit. According to the diving gas, the presented approach could be useful for assessing the presence of helium or argon even in cases of

noble gas poisoning; another specific sampling protocol focused on pulmonary and gastric gas without CT scan support has been developed.<sup>18</sup> However, alternative sites such as gastric gas should be more easily and precisely sampled under CT scan and laser guidance.

#### LIMITATIONS AND PERSPECTIVES

Even if other sites could be of potential interest, the cardiac cavity remains the organ of choice for this sampling because it constitutes an airtight organ directly linked to vital functions. According to the post-mortem delay, peripheral sites could be subjected to more redistribution, gas release from body handling and putrefaction. Sampling sites such as the femoral artery/vein or jugular vein could be used for confirmatory samplings of gas embolism but should not be considered as diagnostic sampling. It is preferable to sample gas in areas independent of the endogenous formation of gases such as the stomach or intestines because the origin of CO<sub>2</sub> is made more difficult to identify.

#### Conclusion

Intra-cadaveric gas sampling and analyses may constitute a useful protocol to help in the investigation of scuba diving fatalities. This should be mandatory from a radiological point of view in order to avoid misinterpretation of the images. Indeed, as diagnoses can be assigned based on CT scans, the forensic radiologist/pathologist must be sure that the intra-cadaveric gas occurrence is not due to decomposition. Moreover, the cardiac gaseous CO<sub>2</sub> concentration and the RAI should be interpreted with the diving profile in order to differentiate between the occurrence of intra-cadaveric gases in barotrauma/AGE/DCS cases and off-gassing. To confirm these findings, additional cases of fatal gas embolism must be analyzed; this confirmatory work is currently in progress.

#### References

- 1 Lawrence C, Cooke C. Autopsy and the investigation of scuba diving fatalities. *Diving Hyperb Med.* 2006;36:2-8.
- 2 Türkmen N, Akan O, Cetin S, Eren B, Gürses MS, Gündoğmus UN. Scuba diver deaths due to air embolism: two case reports. *Soud Lek.* 2013;58(2):26-8.
- 3 Edmonds C, Bennett M, Lippmann J, Mitchell S, editors. *Diving and subaquatic medicine*, 5th ed. Boca Raton (FL): CRC Press; 2016.
- 4 Laurent PE, Coulange M, Bartoli C, Boussuges A, Rostain JC, Luciano M, et al. Appearance of gas collections after scuba diving death: a computed tomography study in a porcine model. *Int J Legal Med.* 2013;127:177-84.
- 5 Dedouit F, Otal P, Loubes-Lacroix F, Rousseau H, Costagliola R, Telmon N, et al. Post-traumatic venous and systemic air embolism associated with spinal epidural emphysema : multi-slice computed tomography diagnosis. *Forensic Sci Int.* 2006;158:190-4.
- 6 Laurent PE, Coulange M, Mancini J, Bartoli C, Desfeux J, Perich P, et al. CT appearance of gas collections can predict the cause of death in scuba diving accidents. *J Forensic Radiol Imaging.* 2013;1:80-7.

- 7 Egger C, Bize P, Vaucher P, Mosimann P, Schneider B, Dominguez A, et al. Distribution of artifactual gas on post-mortem multidetector computed tomography (MDCT). *Int J Legal Med.* 2012;126: 3-12.
- 8 Varlet V, Bruguier C, Grabherr S, Augsburger M, Mangin P, Uldin T. Gas analysis of exhumed cadavers buried for 30 years: a case report about a long time alteration. *Int J Legal Med.* 2013;128:719-24.
- 9 Varlet V, Smith F, Giuliani N, Egger C, Rinaldi A, Dominguez A, et al. When gas analysis assists with postmortem imaging to diagnose causes of death. *Forensic Sci Int.* 2015;24-25:1-10.
- 10 Bernaldo de Quiros Y, Gonzalez-Diaz O, Arbelo M, Sierra E, Sacchini S, Fernandez A. Decompression vs. decomposition: distribution, amount, and gas composition of bubbles in stranded mammals. *Front Physiol.* 2012; 3:177, doi: 10.3389/fphys.2012.00177.
- 11 Bernaldo de Quiros Y, Gonzalez-Diaz O, Mollerlokken A, Brubakk AO, Hjelde A, et al. Differentiation at autopsy between in vivo gas embolism and alteration using gas composition analysis. *Int J Legal Med.* 2013;127:437-45.
- 12 Pierucci G, Gherson G. Studio sperimentale sull'embolia gassosa con particolare riguardo alla differenziazione fra gas embolic e gas putrefattivo. *Zacchia.* 1968;43:347-73. Italian.
- 13 Pierucci G, Gherson G. Ulteriore contributo alla diagnosi chimica di embolia gassosa. *Zacchia.* 1969;5(4):595-603. Italian.
- 14 Lawrence C. Interpretation of gas in diving autopsies. *SPUMS Journal.* 1997;27:228-30.
- 15 Ozdoba C, Weis J, Plattner T, Dirnhofer R, Yen K. Fatal scuba diving incident with massive gas embolism in cerebral and spinal arteries. *Neuroradiol.* 2005;47:411-6.
- 16 Varlet V, Smith F, De Froidmont S, Dominguez A, Rinaldi A, et al. Innovative method for carbon dioxide determination in human postmortem cardiac gas samples using headspace-gas chromatography-mass spectrometry and stable labeled isotope as internal standard. *Anal Chem Acta.* 2013;784:42-6.
- 17 Pedal I, Moosmayer A, Mallach HJ, Oehmichen M. Luftembolie oder fäulnis ? Gasanalytische befunde und ihre interpretation. *Z Rechtsmed.* 1987;99:151-67. German.
- 18 Edmonds C, Caruso J. Recent modifications to the investigation of diving related deaths. *Forensic Sci Med Pathol.* 2014;10:83-90.
- 19 Malbranque S, Mauillon D, Turcant A, Rougé-Maillart C, Mangin P, Varlet V. Quantification of fatal helium exposure following self-administration. *Int J Legal Med.* 2016. doi:10.1007/s00414-016-1364-x.
- 20 Varlet V, Bouvet A, Augsburger M. L'argon: utilisations, toxicité et stratégie analytique en toxicologie médico-légale. *Annal Toxicol Anal.* 2012;24:185-92. French.

**Conflicts of interest:** nil

**Funding:** SG has personal research funding from the Fondation Leenaards, Lausanne, Switzerland.

**Acknowledgements:** We thank the Units of Forensic Toxicology and Chemistry and of Forensic Medicine for their kind assistance on this study.

**Submitted:** 29 January 2016; revised 27 September and 12 December 2016 and 11 April 2017

**Accepted:** 11 April 2017