

Decision making and management of gliomas: practical considerations

A. F. Hottinger^{1,2}, K. Homicsko², L. Negretti³, B. Lhermitte⁴ & R. Stupp^{1*}

¹Departments of Clinical Neurosciences; ²Oncology; ³Radiation Therapy; ⁴Department & Institute of Pathology, Centre Hospitalier Universitaire Vaudois and University of Lausanne, Switzerland

Over the last decade, diagnostic options and introduction of novel treatments have expanded the armamentarium in the management of malignant glioma. Combined chemoradiotherapy has become the standard of care in glioblastoma up to the age of 70 years, while treatment in elderly patients or with lower grade glioma is less well defined. Molecular markers define different disease subtypes and allow for adapted treatment selection. This review focuses on simple questions arising in the daily management of patients.

Key words: anaplastic astrocytoma, chemotherapy, glioblastoma, IDH1, MGMT, oligodendroglioma

introduction

The management of gliomas has changed in the last decade. In 2005, combined modality therapy with temozolomide (TMZ) and radiation therapy has become the standard first-line treatment in glioblastoma (GBM). Numerous new agents, including targeted and antiangiogenic agents are under investigation for the treatment of newly diagnosed or recurrent glioma. Molecular markers, such as isocitrate dehydrogenase 1 (IDH1) in low-grade gliomas, loss of heterozygosity 1p/19q (LOH 1p/19q) in oligodendrogliomas or promoter methylation status of the methyl-guanine methyl transferase (MGMT) gene may help identifying distinct subtypes of gliomas and may help predict response to treatment and outcome. We, here, aim on answering 10 practical questions in the medical management of malignant glioma.

questions

1. should the temozolomide (TMZ) maintenance be prolonged for patients with GBM?

In the pilot and in the randomized European Organization for Research and Treatment of Cancer/National Cancer Institute of Canada (EORTC/NCIC) landmark phase III trial, the 6-month duration of the adjuvant/maintenance TMZ chemotherapy had been chosen arbitrarily on the basis of experience with adjuvant chemotherapy in colon and breast cancer [1]. Given the good tolerance of TMZ and the fact that in GBM, residual macroscopic disease often remains after surgery, some neurooncologists extend the duration of maintenance therapy to 12 months and longer (e.g. for as long as tumor regression is visible on serial magnetic resonance imagings or until tumor progression). Continued tumor

regression on imaging has also been observed after discontinuation of therapy. There are no data suggesting an improved outcome with prolonged maintenance chemotherapy. The recently completed Radiation Therapy Oncology Group (RTOG) 0525/North Central Cancer Treatment Group (NCCTG)/European Organization for the Research and Treatment of Cancer (EORTC) Intergroup trial investigated intensified adjuvant/maintenance therapy. Although in the experimental arm twice the dose intensity of TMZ was delivered, no improvement in any of the outcome parameters was observed. This trial allowed for prolonged administration of adjuvant therapy in responding patients for up to 12 months, a practice widely adopted in the United States. However, no difference in outcome was detected between the American and the European patients. Despite treatment intensification and more aggressive salvage treatment, the median survival from trial registration (soon after surgery) is only 16 months, with a 2-year survival rate of 28%, comparable to the results of the EORTC/National Cancer Institute of Canada (NCIC) trial conducted 6 years earlier.

A number of other reasons speak against prolongation of treatment duration. As with all alkylating agents, there is a risk of development of secondary leukemia and myelodysplastic syndromes. Even though TMZ is usually well tolerated, it is associated with mild-to-moderate asthenia and fatigue, symptoms often appreciated only when treatment has been discontinued. A treatment pause may result in the improved quality of life. Chronic chemotherapy leads to cumulative bone marrow toxicity, thus limiting treatment options for salvage chemotherapy. Chemotherapy resistance may also be decreased with intermittent treatment.

2. should all GBM patients be tested for MGMT?

The randomized EORTC/NCIC phase III trial established concomitant and adjuvant (maintenance) TMZ chemotherapy with and after irradiation (TMZ/RT→TMZ) as the standard of

*Correspondence to: Prof. R. Stupp, Department of Clinical Neurosciences, Neurosurgery, University Hospital CHUV, Rue du Bugnon 46, 1011 Lausanne/Switzerland. Tel: +41-21-314-0156; Fax: +41-21-314-0737; E-mail: roger.stupp@chuv.ch

care. Median survival was improved from 12.1 months with initial RT alone, to 14.6 months when TMZ was added. Significantly, the 2-year survival rates increased from 10% to 27%. The silencing of DNA repair protein MGMT has been associated with benefit from alkylating agent chemotherapy, as this enzyme repairs the toxic injuries inflicted to tumor cells by alkylating chemotherapeutic agents [2]. This hypothesis was confirmed retrospectively in the randomized trial. The benefit of the addition of TMZ chemotherapy was shown to be mainly restricted to patients whose tumors have a methylated MGMT gene promoter, and have, therefore, a limited capacity to repair some of the alkylating agent chemotherapy-induced DNA damages [3, 4]. The recently reported RTOG0525/NCCTG/EORTC Intergroup study prospectively validated MGMT gene promoter testing and its association with outcome. This study included mandatory central MGMT methylation status determination, as stratification factor before randomization.

It is reasonable to question whether all GBM patients should be tested for the methylation status of the promoter region of the MGMT gene. However, information on a predictive marker is useful only if it will permit to adapt the treatment strategy to improve the outcome and/or the quality of life in patients. In the RTOG study, dose intensification failed to overcome TMZ-mediated resistance or to further improve outcome in patients with a methylated MGMT promoter. Outside of clinical trials, there are currently no adequate alternative treatment strategies for patients without methylated MGMT promoter regions. Therefore, short of any promising alternative treatment, the practical value of MGMT testing remains largely prognostic and, thus, we do not assess the MGMT status routinely. Nevertheless, there are a number of situations, where knowledge of the MGMT status may be of practical use and influence patient management:

- In patients with a borderline performance status, where in the absence of an expected major response to chemotherapy, management may be limited to supportive care only. In an elderly population, it was shown that active treatment with TMZ might offer significant chances of a tumor response and improvement in performance and cognitive status, allowing some independence and enhancement of quality of life. And response was strongly correlated with the presence of MGMT promoter methylation in the tumor [5]. The specific situation of elderly patients will be discussed below.
- When in doubt of whether observed radiological progression is likely to be pseudoprogression. Here, patients with methylated MGMT are more likely to develop tumor necrosis and associated disruption of the blood–brain barrier, leading to increased contrast enhancement that could be falsely considered as tumor progression [6].
- When in doubt whether alkylating agent chemotherapy should be continued or reintroduced, the presence of MGMT promoter methylation may be a reason to favor alkylating agent chemotherapy.

3. what is the role of IDH1 in the management of glioma?

Isocitrate dehydrogenases are a group of enzymes involved in monocarbon metabolism, which catalyzes the conversion of

isocitrate to α -ketoglutarate. Mutations in IDH genes, particularly IDH1_{R132MUT} have been shown to be characteristic of low-grade gliomas and to represent one of the earliest mutations in gliomas and may initiate glioma formation. They have been identified in over 70% of grade II gliomas and ~50% of grade III lesions [7–9]. The overall rare secondary GBMs also have a high propensity to harbor IDH mutations. The patients whose GBM contained an IDH1 mutation showed a longer survival than those with wild-type IDH1. Actually these patients showed also better survival than patients with grade III gliomas that did not harbor the IDH1 mutation [10]. In low-grade gliomas, the prognostic or predictive role of IDH1 mutations remains however controversial in grade II gliomas [11]. IDH mutation status can be analyzed easily and reproducibly by simple PCR and sequence analysis. For the more frequent IDH1 mutation, a monoclonal antibody is available, allowing demonstration of the presence of the mutation by immunohistochemistry [12] (Figure 1).

In clinical practice, IDH1 is not only a prognostic marker for high-grade gliomas. IDH1 mutations may also be used as a diagnostic marker to identify diffuse tumor infiltration of astrocytoma or oligodendroglioma and distinguish diffuse tumor infiltration from reactive astrocytosis (IDH1 wild type). The presence of IDH1 mutation may help distinguish WHO grade I pilocytic astrocytoma (no IDH1 mutations) from diffuse astrocytomas [13]. Similarly, ependymomas do not harbor mutant IDH1 [14, 15]. Finally, mutant IDH1 may help the pathologist distinguish oligodendrogliomas from other glioneuronal tumors with clear-cell morphology.

4. how to treat elderly patients with GBM?

In the randomized EORTC/NCIC (landmark phase III trial, only patients up to the age of 70 years were included (Table 1). Age is a major prognostic factor for poorer outcome, and it was not felt appropriate to propose a combined modality and lengthy treatment to patients with a short life expectancy [16]. Consistently, outcome in patients over the age of 50 years was worse than for younger patients in the EORTC/NCIC trial.

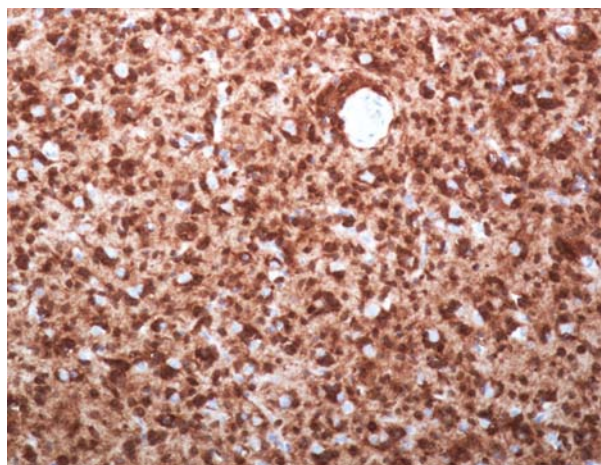


Figure 1. Expression of mutated IDH1 protein in glioblastoma. Immunohistochemistry using a mouse monoclonal antibody targeting the IDH1 R132H mutation.

Table 1: Randomized multicenter trials for high grade gliomas.

Name of trial	Indication	Phase	Primary end point	Design	Number of patients	Outcome		Comments
						Median PFS (months)	Median OS (months)	
EORTC 26981 [1]	First-line GBM	III	OS	Arm 1: RT60 Gy Arm 2: RT60 Gy/ TMZ75 mg/m ² /day ⇒ TMZ150-200 mg/ m ² /days 1-5	260 260	5.0 6.9	12.1 14.6	Patients: 18-70 years old/PFS: HR: 0.54 (95% CI 0.45-0.64), <i>P</i> < 0.001/OS: HR: 0.62 (95% CI 0.51-0.75), <i>P</i> < 0.001
RTOG0525	First-line GBM	III	OS	Arm 1: RT60 Gy/ TMZ75 mg/m ² /day ⇒ TMZ150-200 mg/ m ² /days 1-5 RT versus	411	5.5	16.6	Patients: 18-70 years old/data from ASCO 2011/OS: HR: 1.03 (0.88-1.20), <i>P</i> = 0.63/PFS: HR: 0.87 (0.75-1.00), <i>P</i> = 0.06
				Arm 2: 60 Gy/TMZ75 mg/m ² /day ⇒ TMZ100 mg/m ² /days 1-21	420	6.7	14.9	
Nordic trial	First-line GBM in elderly	III	OS	Arm 1: RT60 Gy/30 f (6 weeks)	100	NA	6.0	Data from ASCO 2011
				Arm 2: RT34 Gy/10 f (2 weeks)	123	NA	7.5	
				Arm 3: TMZ150 mg/m ² /days 1-5	119	NA	8.3	
NOA-08	First-line GBM in elderly	III	OS	Arm 1: RT 60 Gy	179	NA	9.6	Data from ASCO 2011/OS: HR: 1.09 (0.84-1.42)
				Arm 2: TMZ100 mg/m ² /days 1-7 every 14 days	194	NA	8.6	
NOA-04 [44]	First-line grade III gliomas	III	TTF	Arm 1: RT60 Gy ⇒ PCV or TMZ at PD	139	30.6 (TTF)	NR	TTF: HR: 1.2 (95% CI 0.8-1.8), <i>P</i> = 0.28
				Arm 2: PCV or TMZ ⇒ RT at PD	135	31.9 (TTF)	NR	
EORTC 26951 [42]	First-line grade III oligodendroglioma	III	OS	Arm 1: RT 45 Gy	183	13	30.6	OS: HR: 0.85 (95% CI 0.53-0.87), <i>P</i> = 0.23/PFS: HR: 0.68 (95% CI 0.53-0.87), <i>P</i> = 0.018
				Arm 2: RT 45 Gy ⇒ PCV	185	23	40.3	
RTOG9402 [43]	First-line grade III oligodendroglioma	III	OS	Arm 1: PCV/RT	147	NR	NR	OS: HR: 0.9 (0.66-1.24), <i>P</i> = 0.26/PFS: HR: 0.69 (95% CI 0.52-0.91), <i>P</i> = 0.04
				Arm 2: RT	142	31.2	79.2	

95% CI, 95% confidence interval; f, fraction; Gy, gray; HR, hazard ratio; OS, overall survival; PCV, procarbazine, lomustine, vincristine; PFS, progression free survival; RT, radiotherapy; TMZ, temozolomide; TTF, time-to-treatment failure at 2nd progression; NA, not available; NR, not reached.

Nevertheless, the hazard ratio in patients between 60 and 65 years [0.64 (0.43-0.94), *P* = 0.02] and 65-70 years [0.78 (0.50-1.24), *P* = 0.29] favored combined modality therapy in these subgroups. In a general nonprotocol population, the median age of GBM patients is >65 years (compared with 50-55 years in clinical trials), and the study results cannot be simply extrapolated to the elderly. A number of factors may explain the inferior outcome in elderly GBM patients: comorbidities and a frail general condition, and consequently inferior tolerance to combined modality therapy, or a less aggressive attitude to active therapy by both physicians and patients alike. Palliative treatments extending over several weeks may not be justified in patients with a short life expectancy. A small randomized Canadian trial on 100 subjects showed that for

elderly patients with a Karnofsky performance status (KPS) between 60 and 80, hypofractionated RT to a total dose of 40 Gy in 15 fractions given over 3 weeks resulted in similar overall survival (OS) than the standard 60 Gy given in 30 fractions over 6 weeks with a median OS of 5.6 months in both groups [17]. The results of two randomized phase III trials were recently published [18, 19]. The Nordic trial randomized patients into receiving either (i) TMZ alone (150 mg/m²/days 1-5 every 28 days for up to 12 cycles versus (ii) RT to 60 Gy in 30 fractions of 2 Gy over 6 weeks versus (iii) RT to 34 Gy in 10 fraction over 2 weeks. This trial enrolled 342 patients over the age of 60 years (median 70 years) and with a KPS of at least 60. There were no significant differences in OS when all patients were considered (intent to treat); median OS was 8.3,

6.0 and 7.5 months, for TMZ, RT60 and RT34, respectively. The difference between patients receiving 34 Gy or TMZ was not statistically significant. However, elderly patients older than 70 years ($n = 123$) derived significantly more benefit from receiving TMZ alone than 60 Gy of RT. The high dropout rate and particularly poor outcome in patients treated with standard fractionated 6-weeks course of radiotherapy suggests that this strategy may be too burdensome for elderly patients. On multivariate analysis, younger age (60–70 versus 70+), better performance status, more extensive resection and steroid independence could be identified as independent prognostic factors for a better outcome. The German Neuro-Onkologische Arbeitsgruppe (NOA)-08 phase III trial included patients with both GBM and anaplastic astrocytoma aged over 65 years and a KPS of at least 60. Patients were randomized to receive either standard fractionated RT (54–60 Gy in fractions of 1.8–2 Gy over 6 weeks) versus dose-dense TMZ (100 mg/m²/day 1 week on/1 week off). There was no significant difference in OS between both groups. Interestingly, in both studies, patients with a methylated MGMT promoter derived significantly more benefit from receiving TMZ. The NCIC and EORTC are conducting a joint phase III trial evaluating a short course of RT alone administered over 3 weeks versus the combination of the same course of RT combined with TMZ in patients over 65 years of age that are not candidates to receive standard RT/TMZ→TMZ (clinicaltrials.gov: NCT00482677).

We conclude that, in daily practice, treatment of elderly should be tailored individually. In elderly patients with a good performance status and few comorbidities, we often recommend the standard TMZ/RT→TMZ protocol [1]. In the patients older than 70 years, we usually administer hypofractionated RT and concomitant TMZ. If the patient has a KPS below 70–80, and MGMT promoter region is methylated, we recommend treatment with TMZ alone [5]. If the tumor is unmethylated, hypofractionated RT alone or exclusive supportive care should be considered.

5. what is the value of alternative dose-dense temozolomide dosing regimens?

TMZ (Temodal®, Temodar®, Merck & Co., Whitehouse Station, NJ) was initially approved for recurrent glioma with a 5 consecutive days dosing scheme every 28 days at a dose of 150–200 mg/m². This regimen was selected based on preclinical data. Subsequently, alternative continuous and intensive dose-dense intermittent dosing regimens were tested in phase I clinical trials [20, 21]. These dosing schedules allowed for increasing the dose intensity, and at maximally tolerated doses a doubling of the cumulative monthly dose was achieved, without increase in severe toxicity. Continuous exposure to TMZ will deplete the DNA repair protein MGMT in peripheral blood mononuclear cells [21]. It was postulated that this may be a way to overcome MGMT mediated resistance by exhausting the cellular repair protein reservoir [21]. Furthermore, continuous ‘metronomic’ exposure to low doses of TMZ might be toxic to endothelial cells and exhibit antiangiogenic properties. A number of uncontrolled (!) phase II studies then suggested that intensifying the exposure to TMZ may indeed increase the response rate, progression free survival

and OS [22–26]. Based on these assumptions, the RTOG0525/Intergroup randomized phase III trial compared standard dose adjuvant TMZ (150–200 mg/m² daily for 5 days in 28-day cycles) with a dose-dense regimen (75–100 mg/m² daily for 21 days in 28-day cycles). No difference in any of the outcome parameters was shown, and disappointingly, the treatment intensification did neither allow to overcoming resistance to TMZ in patients with unmethylated tumors, nor to improving further the outcome in patients benefitting from the addition of TMZ. Similarly, a British trial comparing dose intensification (21/28 days versus 5/28 days) in chemo-naïve glioma patients with recurrent disease also failed to demonstrate a benefit for the dose-dense regimen. Actually, survival was slightly, but not significantly improved with the daily × five standard regimen [27]. An ongoing trial (Director Study, PI: Michael Weller, clinicaltrials.gov: NCT00941460) is comparing the week-on/week-off regime with the 21/28 days regimen in GBM patients who recurred after prior TMZ/RT→TMZ standard therapy. A special focus will be on molecular markers and predictive factors. The trial aims for histological confirmation of the recurrence and determination of MGMT in the majority of patients.

The currently available data does not support the common practice of TMZ dose intensification at recurrence, but such a strategy has also not been formally disproven.

6. should bevacizumab be added to the standard first-line treatment of glioblastoma?

Bevacizumab (BEV, Avastin®, Roche, Basel, Switzerland), a humanized monoclonal antibody directed against the vascular endothelial growth factor, has received provisional approval by the US Food and Drug Administration for recurrent GBM, while this indication was rejected by the European Medicines Agency due to the lack of controlled data [28, 29]. Given the fact that BEV can easily be combined with cytotoxic chemotherapy, introduction of this antiangiogenic therapy in the upfront setting has gained interest. Feasibility and safety have been shown in a small phase I trial [30]. Two phase II studies evaluated the addition of BEV (10 mg/kg every other week) to standard TMZ/RT starting within 3–6 weeks after surgery. After completion of TMZ/RT, patients resumed TMZ for 5 days every 4 weeks while continuing biweekly BEV. This combination treatment was well tolerated with toxicity similar to standard TMZ/RT alone. In their single institution experience, Narayana et al. reported on 51 patients with a promising progression-free survival (PFS) of 13 months and OS of 23 months [confidence intervals (CI) not reported, study immature at the time of the report] [31]. An analysis of patients treated at Kaiser Permanente and University of California in Los Angeles (UCLA), reported an OS of 16.9 months (95% CI 16.1–23.3). Although this compares favorably to the results of the EORTC-NCIC trial (14.6 months, 95% CI 13.2–16.8), the outcome was not different from a series of patients treated at the same institutions with standard first-line treatment TMZ/RT→TMZ, and BEV administered at the first recurrence (median survival 21.1 months (95% CI 18.9–25.2) [32]. Two similar randomized phase III trials have been launched. In RTOG0825 (clinicaltrials.gov: NCT 00884741)

BEV (10 mg/kg) is being introduced only after 3 weeks of TMZ/RT, BEV is given every other week from the beginning of irradiation in the Roche/Genentech sponsored AvaGlio trial (clinicaltrials.gov: NCT 00943826). Both trials have completed accrual of > 900 patients each; first results are expected in 2013. Until then, the available data does not justify the use of BEV in the first-line treatment of high-grade gliomas. Preclinical data even suggest a potentially detrimental effect [33, 34]. The optimal dose of BEV has never been investigated, and lower doses may well result in a similar effect and less toxicity.

7. do all patients need pneumocystis prophylaxis?

Continuous TMZ administration has been associated with profound lymphocytopenia, cellular immunosuppression and opportunistic infections. The most common infectious agent identified is *Pneumocystis jirovecii* (formerly known as *pneumocystis carini*), but *candida* and *listeria* have also been reported. The common use of corticosteroids further exacerbates the immuno-deficient state. *Pneumocystis pneumonia* (PcP) prophylaxis with either pentamidine or trimetoprim/sulfamethoxazol or dapsone [35] has been introduced after observation of 2 patients with PcP out of the first 15 treated with TMZ/RT [36]. Similar observations of opportunistic infections were also reported elsewhere [37, 38]. In the randomized GBM trial, primary PcP prophylaxis was mandatory, a recommendation that has also been included in the official approval label for concomitant TMZ chemoradiotherapy. In practice, prophylaxis may be approached in different ways: Most commonly and considered simple and safe, sulfa-drugs are prescribed to all patients (e.g. Bactrim forte administered 3 times per week or dapsone 100 mg/day). However, these antibiotics are associated with a risk of myelosuppression, that may be severe in conjunction with chemotherapy. We prefer once monthly pentamidine inhalations (Pentacarinat 300 mg q28d). With the appropriate infrastructure, pentamidine inhalations are easy to perform, well tolerated and do not add to the patients long list of oral medications. Usually, two administrations are sufficient, as lymphocyte counts recover after the end of concomitant TMZ/RT. Alternatively, one may consider surveillance of absolute lymphocyte or CD4 counts. Prophylactic treatment should be introduced if the absolute lymphocytes drops below 500/mm³ (μl) or the CD4 below 200/mm³.

8. how to treat pure oligodendroglioma?

Oligodendroglioma have been recognized as a distinct histological and molecularly defined entity. Oligodendrogliomas with LOH 1p/19q have been shown to have a better outcome and better response to both chemotherapy and to radiotherapy than oligodendrogliomas without LOH 1p/19q [39–41]. Two large randomized trials by EORTC and RTOG demonstrated median survival rates beyond 7 years in patients with oligodendroglioma that carry a translocation 1p/19q, compared with <3 years for patients with absence of 1p/19q LOH [42, 43]. In a recent update of these trials that enrolled patients over 10 years ago, a survival benefit for early PCV-chemotherapy (procarbazine, lomustine, vincristine) has been suggested in the subgroup of patients

with an LOH 1p/19q (Cairncross et al., Proc ASCO 2012, van den Bent et al. Proc ASCO 2012). These findings suggest that early treatment with chemotherapy in addition to RT may result in long-term control of LOH 1p/19q oligodendrogliomas. Since the widespread availability and acceptance of TMZ chemotherapy, this agent has largely replaced the formerly popular PCV regimen. In a randomized trial comparing directly PCV chemotherapy (224 patients) with TMZ administered either over 5 days (200 mg/m² for 5 days, 112 patients) or TMZ-21 (100 mg/m² for 21 days) in recurring high-grade gliomas, no significant difference in outcome between patients treated with PCV and TMZ was found [27]. Similarly, a German study on anaplastic glioma showed that outcome in patients treated with PCV or TMZ was comparable [44]. More importantly, this same study also demonstrated, that the sequence of treatment administration (radiotherapy first, chemotherapy at recurrence/progression or chemotherapy as initial treatment and RT as salvage therapy) did not substantially influence outcome [44]. For patients with long survival time, the major objective is also to limit acute and late treatment-related toxicity to a minimum. Given the favorable toxicity profile of TMZ compared with PCV and the demonstration of efficacy of TMZ in GBM patients, TMZ nowadays is the preferred first choice of chemotherapy.

While for a small tumor a 6-week course of fractionated radiotherapy remains the treatment of choice, primary chemotherapy with TMZ may be preferred in larger tumors requiring an extensive radiation field. Data on the concomitant use of chemo- and radiotherapy in analogy to GBM are not available.

9. what is the standard of care of anaplastic astrocytoma?

In contrast to patients suffering from anaplastic oligodendroglioma with LOH 1p/19q, the situation is very different for patients that do not exhibit 1p/19q LOH. Those patients have an expected median survival of only ~2 years, and almost invariably present with recurrence or progressive disease [45]. For these patients, the historic first-line standard of care treatment has been RT, based on randomized data when anaplastic glioma was treated within the same protocols as GBM [46]. The NOA-04 trial included 274 patients and showed that PFS and OS were similar regardless of whether these patients were treated with RT as a first line of treatment followed by chemotherapy (PCV or TMZ) or by initial chemotherapy followed by RT at recurrence [44]. It remains however to be shown whether these patients may benefit from a combined first-line treatment with a combination of RT and TMZ. This is currently being evaluated in the phase III CATNON trial, led by the EORTC, together with the German NOA, the British Medical Research Council, the US RTOG, NCCTG and Eastern Cooperative Oncology Group. This study is investigating concomitant versus adjuvant TMZ chemotherapy in a 2 × 2 design. Patients will be randomized to either RT alone or the combination of TMZ/RT in a first step and then to either adjuvant TMZ (standard schedule, 150–200 mg/m² daily for 5 days in a 28-day cycle) for 12 cycles (!) or observation after RT alone. Currently, approximately one-third of the planned 748 patients have been randomized.

10. what is the role of radiosurgery in the management of gliomas

Radiotherapy has been the mainstay for treatment of malignant glioma for over 30 years [46, 47]. Although improved survival has been demonstrated with RT doses of 60 Gy compared with 50 Gy [48], further attempts to dose escalate by using accelerated or hyperfractionated schedules did not translate into further improvement [49]. Local failure remained the primary site of disease recurrence, and has been seen with predominance in the areas of dose escalation [50–52]. To try to intensify radiotherapy dose, while keeping the normal brain toxicity to acceptable levels, more focal methods, such as stereotactic radiosurgery (SRS), have been added to conventional fractionated external beam radiation therapy. Radiosurgery is a technique that delivers a highly conformal high dose to a precise target by using multiple focused beams from multiple directions thanks to image guidance (stereotactic system) in the three dimensions. It is able to minimize the dose distribution to normal tissue. Several uncontrolled retrospective and prospective studies suggested improved survival when a SRS-boost was added to the conventional radiotherapy in newly diagnosed gliomas [53–57]. These data could, however, not be confirmed by other studies [58]. In a prospective multi-institutional, phase III randomized trial (RTOG 93-05), SRS was added to standard external beam RT and carmustine chemotherapy [59]. A total of 203 patients with small (≤ 4 cm) supratentorial GBM were randomized to receive or not a stereotactic boost to the contrast-enhancing residual tumor for a dose of up to 24 Gy depending on the size of the lesion. Median OS was 13.5 and 13.6 months in the SRS and control groups, respectively ($P = 0.57$). Also, there were no significant differences in 2- and 3-year survival rates. Subsequent efforts focused on accurate delineation of high-risk regions that are more aggressive and may benefit from additional directed dose by magnetic resonance spectroscopy, positron emission tomography using radiolabeled glucose as well as methionine, fluoro-ethyl tyrosine or similar tracers, and magnetic resonance tumor perfusion imaging. In a phase II trial using magnetic resonance spectroscopy-targeted SRS in the treatment of patients with GBM, 35 patients underwent surgical resection or biopsy, followed by SRS directed toward areas of spectroscopically high biological activity within 2 cm of the postoperative enhancing surgical bed. All patients subsequently received conformal radiotherapy (60 Gy), 16 of 35 patients received concurrent TMZ. For these patients, the median survival was a promising 20.8 months [60] but short of a controlled study, no conclusions can be drawn.

At the time of GBM recurrence, retreatment with standard RT often exposes the brain to an unacceptable risk of radiation injury and necrosis. In this context, SRS may represent a treatment option allowing to sparing surrounding brain volume from re-irradiation and try to achieve control of rapidly growing areas. Several studies pointed out the potential utility of adjuvant SRS at recurrence, with median survival time after SRS varying from 4.6 to 16 months [61–63]. The value of these results is difficult to establish given the fact that patients are highly selected for very localized recurrences amenable to radiosurgery.

disclosure

AFH has served on advisory board and speakers bureau for MSD/Merck & Co. RS served as an advisor and on speakers bureau to Merck Serono and MSD/Merck & Co, and on advisory boards for Roche. All other authors have declared no conflicts of interest.

references

1. Stupp R, Mason WP, van den Bent MJ et al. Radiotherapy plus concomitant and adjuvant temozolomide for glioblastoma. *N Engl J Med* 2005; 352: 987–996.
2. Jaeckle KA, Eyre HJ, Townsend JJ et al. Correlation of tumor O6 methylguanine-DNA methyltransferase levels with survival of malignant astrocytoma patients treated with bis-chloroethylnitrosourea: a Southwest Oncology Group study. *J Clin Oncol* 1998; 16: 3310–3315.
3. Hegi ME, Diserens AC, Gorlia T et al. MGMT gene silencing and benefit from temozolomide in glioblastoma. *N Engl J Med* 2005; 352: 997–1003.
4. Hegi ME, Diserens AC, Godard S et al. Clinical trial substantiates the predictive value of O-6-methylguanine-DNA methyltransferase promoter methylation in glioblastoma patients treated with temozolomide. *Clin Cancer Res* 2004; 10: 1871–1874.
5. Gallego Perez-Larraya J, Ducray F, Chinot O et al. Temozolomide in elderly patients with newly diagnosed glioblastoma and poor performance status: an ANOCEF phase II trial. *J Clin Oncol* 2011; 29: 3050–3055.
6. Brandes AA, Franceschi E, Tosoni A et al. MGMT promoter methylation status can predict the incidence and outcome of pseudoprogression after concomitant radiochemotherapy in newly diagnosed glioblastoma patients. *J Clin Oncol* 2008; 26: 2192–2197.
7. Lai A, Kharbanda S, Pope WB et al. Evidence for sequenced molecular evolution of *IDH1* mutant glioblastoma from a distinct cell of origin. *J Clin Oncol* 2011; 29: 4482–4490.
8. Parsons DW, Jones S, Zhang X et al. An integrated genomic analysis of human glioblastoma multiforme. *Science* 2008; 321: 1807–1812.
9. Sanson M, Marie Y, Paris S et al. Isocitrate dehydrogenase 1 codon 132 mutation is an important prognostic biomarker in gliomas. *J Clin Oncol* 2009; 27: 4150–4154.
10. Yan H, Parsons DW, Jin G et al. *IDH1* and *IDH2* mutations in gliomas. *N Engl J Med* 2009; 360: 765–773.
11. Ahmadi R, Stockhammer F, Becker N et al. No prognostic value of *IDH1* mutations in a series of 100 WHO grade II astrocytomas. *J Neurooncol* 2012; 109: 15–22.
12. Capper D, Zentgraf H, Bals J et al. Monoclonal antibody specific for *IDH1* R132H mutation. *Acta Neuropathol* 2009; 118: 599–601.
13. Korshunov A, Meyer J, Capper D et al. Combined molecular analysis of BRAF and *IDH1* distinguishes pilocytic astrocytoma from diffuse astrocytoma. *Acta Neuropathol* 2009; 118: 401–405.
14. Bals J, Meyer J, Mueller W et al. Analysis of the *IDH1* codon 132 mutation in brain tumors. *Acta Neuropathol* 2008; 116: 597–602.
15. Watanabe T, Vital A, Nobusawa S et al. Selective acquisition of *IDH1* R132C mutations in astrocytomas associated with Li-Fraumeni syndrome. *Acta Neuropathol* 2009; 117: 653–656.
16. Brada M, Stenning SP. Radiotherapy for malignant gliomas in the elderly. *Semin Oncol* 2003; 30: 63–67.
17. Roa W, Brasher PM, Bauman G et al. Abbreviated course of radiation therapy in older patients with glioblastoma multiforme: a prospective randomized clinical trial. *J Clin Oncol* 2004; 22: 1583–1588.
18. Malmstrom A, Gronberg BH, Marosi C et al. Temozolomide versus standard 6-week radiotherapy versus hypofractionated radiotherapy for patients aged over 60 years with glioblastoma: a randomised phase 3 trial. *Lancet Oncol* 2012, in press.
19. Wick W, Platten M, Meisner C et al. Temozolomide chemotherapy alone versus radiotherapy alone for malignant astrocytoma in the elderly: the NOA-08 randomised phase III trial. *Lancet Oncol* 2012; 13: 707–715.

20. Brock CS, Newlands ES, Wedge SR et al. Phase I trial of temozolomide using an extended continuous oral schedule. *Cancer Res* 1998; 58: 4363–4367.
21. Tolcher AW, Gerson SL, Denis L et al. Marked inactivation of O6-alkylguanine-DNA alkyltransferase activity with protracted temozolomide schedules. *Br J Cancer* 2003; 88: 1004–1011.
22. Clarke JL, Iwamoto FM, Sul J et al. Randomized phase II trial of chemoradiotherapy followed by either dose-dense or metronomic temozolomide for newly diagnosed glioblastoma. *J Clin Oncol* 2009; 27: 3861–3867.
23. Weiler M, Hartmann C, Wiewrodt D et al. Chemoradiotherapy of newly diagnosed glioblastoma with intensified temozolomide. *Int J Radiat Oncol Biol Phys* 2010; 77: 670–676.
24. Dall'oglio S, D'Amico A, Pioli F et al. Dose-intensity temozolomide after concurrent chemoradiotherapy in operated high-grade gliomas. *J Neurooncol* 2008; 90: 315–319.
25. Wick A, Felsberg J, Steinbach JP et al. Efficacy and tolerability of temozolomide in an alternating weekly regimen in patients with recurrent glioma. *J Clin Oncol* 2007; 25: 3357–3361.
26. Perry JR, Belanger K, Mason WP et al. Phase II trial of continuous dose-intense temozolomide in recurrent malignant glioma: RESCUE study. *J Clin Oncol* 2010; 28: 2051–2057.
27. Brada M, Stenning S, Gabe R et al. Temozolomide versus procarbazine, lomustine, and vincristine in recurrent high-grade glioma. *J Clin Oncol* 2010; 28: 4601–4608.
28. Friedman HS, Prados MD, Wen PY et al. Bevacizumab alone and in combination with irinotecan in recurrent glioblastoma. *J Clin Oncol* 2009; 27: 4733–4740.
29. Kreisl TN, Kim L, Moore K et al. Phase II trial of single-agent bevacizumab followed by bevacizumab plus irinotecan at tumor progression in recurrent glioblastoma. *J Clin Oncol* 2009; 27: 740–745.
30. Vredenburgh JJ, Desjardins A, Kirkpatrick JP et al. Addition of bevacizumab to standard radiation therapy and daily temozolomide is associated with minimal toxicity in newly diagnosed glioblastoma multiforme. *Int J Radiat Oncol Biol Phys* 2012; 82: 58–66.
31. Narayana A, Gruber D, Kunnakkat S et al. A clinical trial of bevacizumab, temozolomide, and radiation for newly diagnosed glioblastoma. *J Neurosurg* 2012; 116: 341–345.
32. Lai A, Tran A, Nghiemphu PL et al. Phase II study of bevacizumab plus temozolomide during and after radiation therapy for patients with newly diagnosed glioblastoma multiforme. *J Clin Oncol* 2011; 29: 142–148.
33. Paez-Ribes M, Allen E, Hudock J et al. Antiangiogenic therapy elicits malignant progression of tumors to increased local invasion and distant metastasis. *Cancer Cell* 2009; 15: 220–231.
34. Xu L, Duda DG, di Tomaso E et al. Direct evidence that bevacizumab, an anti-VEGF antibody, up-regulates SDF1 α , CXCR4, CXCL6, and neuropilin 1 in tumors from patients with rectal cancer. *Cancer Res* 2009; 69: 7905–7910.
35. Kovacs JA, Gill VJ, Meshnick S et al. New insights into transmission, diagnosis, and drug treatment of *Pneumocystis carinii* pneumonia. *JAMA* 2001; 286: 2450–2460.
36. Stupp R, Dietrich PY, Ostermann Kraljevic S et al. Promising survival for patients with newly diagnosed glioblastoma multiforme treated with concomitant radiation plus temozolomide followed by adjuvant temozolomide. *J Clin Oncol* 2002; 20: 1375–1382.
37. Ganiere V, Christen G, Bally F et al. *Listeria* brain abscess, *Pneumocystis* pneumonia and Kaposi's sarcoma after temozolomide. *Nat Clin Pract Oncol* 2006; 3: 339–343.
38. Su YB, Sohn S, Krown SE et al. Selective CD4+ lymphopenia in melanoma patients treated with temozolomide: a toxicity with therapeutic implications. *J Clin Oncol* 2004; 22: 610–616.
39. Jenkins RB, Blair H, Ballman KV et al. A t(1;19)(q10;p10) mediates the combined deletions of 1p and 19q and predicts a better prognosis of patients with oligodendroglioma. *Cancer Res* 2006; 66: 9852–9861.
40. Griffin CA, Burger P, Morsberger L et al. Identification of der(1;19)(q10;p10) in five oligodendrogliomas suggests mechanism of concurrent 1p and 19q loss. *J Neuropathol Exp Neurol* 2006; 65: 988–994.
41. Ino Y, Betensky RA, Zlatescu MC et al. Molecular subtypes of anaplastic oligodendroglioma: implications for patient management at diagnosis. *Clin Cancer Res* 2001; 7: 839–845.
42. van den Bent MJ, Carpentier AF, Brandes AA et al. Adjuvant procarbazine, lomustine, and vincristine improves progression-free survival but not overall survival in newly diagnosed anaplastic oligodendrogliomas and oligoastrocytomas: a randomized European Organisation for Research and Treatment of Cancer phase III trial. *J Clin Oncol* 2006; 24: 2715–2722. (updated ASCO 2012, abstract #2).
43. Cairncross G, Berkey B, Shaw E et al. Phase III trial of chemotherapy plus radiotherapy compared with radiotherapy alone for pure and mixed anaplastic oligodendroglioma: Intergroup Radiation Therapy Oncology Group Trial 9402. *J Clin Oncol* 2006; 24: 2707–2714. (updated ASCO 2012, abstract #2008b)
44. Wick W, Hartmann C, Engel C et al. NOA-04 randomized phase III trial of sequential radiochemotherapy of anaplastic glioma with procarbazine, lomustine, and vincristine or temozolomide. *J Clin Oncol* 2009; 27: 5874–5880.
45. Hildebrand J, De Witte O, Sahmoud T. Response of recurrent glioblastoma and anaplastic astrocytoma to dibromodulcitol, BCNU and procarbazine—a phase-II study. *J Neurooncol* 1998; 37: 155–160.
46. Walker MD, Green SB, Byar DP et al. Randomized comparisons of radiotherapy and nitrosoureas for the treatment of malignant glioma after surgery. *N Engl J Med* 1980; 303: 1323–1329.
47. Green SB, Byar DP, Walker MD et al. Comparisons of carmustine, procarbazine, and high-dose methylprednisolone as additions to surgery and radiotherapy for the treatment of malignant glioma. *Cancer Treat Rep* 1983; 67: 121–132.
48. Bleehen NM, Stenning SP. A Medical Research Council trial of two radiotherapy doses in the treatment of grades 3 and 4 astrocytoma. The Medical Research Council Brain Tumour Working Party. *Br J Cancer* 1991; 64: 769–774.
49. Coughlin C, Scott C, Langer C et al. Phase II, two-arm RTOG trial (94-11) of bischloroethyl-nitrosourea plus accelerated hyperfractionated radiotherapy (64.0 or 70.4 Gy) based on tumor volume (> 20 or = 20 cm²), respectively) in the treatment of newly-diagnosed radiosurgery-ineligible glioblastoma multiforme patients. *Int J Radiat Oncol Biol Phys* 2000; 48: 1351–1358.
50. Lee SW, Fraass BA, Marsh LH et al. Patterns of failure following high-dose 3-D conformal radiotherapy for high-grade astrocytomas: a quantitative dosimetric study. *Int J Radiat Oncol Biol Phys* 1999; 43: 79–88.
51. Chan JL, Lee SW, Fraass BA et al. Survival and failure patterns of high-grade gliomas after three-dimensional conformal radiotherapy. *J Clin Oncol* 2002; 20: 1635–1642.
52. Gaspar LE, Fisher BJ, Macdonald DR et al. Supratentorial malignant glioma: patterns of recurrence and implications for external beam local treatment. *Int J Radiat Oncol Biol Phys* 1992; 24: 55–57.
53. Prisco FE, Weltman E, de Hanriot RM et al. Radiosurgical boost for primary high-grade gliomas. *J Neurooncol* 2002; 57: 151–160.
54. Mehta MP, Masciopinto J, Rozental J et al. Stereotactic radiosurgery for glioblastoma multiforme: report of a prospective study evaluating prognostic factors and analyzing long-term survival advantage. *Int J Radiat Oncol Biol Phys* 1994; 30: 541–549.
55. Sarkaria JN, Mehta MP, Loeffler JS et al. Radiosurgery in the initial management of malignant gliomas: survival comparison with the RTOG recursive partitioning analysis. *Radiation Therapy Oncology Group. Int J Radiat Oncol Biol Phys* 1995; 32: 931–941.
56. Loeffler JS, Alexander E, 3rd, Shea WM et al. Radiosurgery as part of the initial management of patients with malignant gliomas. *J Clin Oncol* 1992; 10: 1379–1385.
57. Nwokedi EC, DiBiase SJ, Jabbour S et al. Gamma knife stereotactic radiosurgery for patients with glioblastoma multiforme. *Neurosurgery* 2002; 50: 41–46.
58. Gannett D, Stea B, Lulu B et al. Stereotactic radiosurgery as an adjunct to surgery and external beam radiotherapy in the treatment of patients with malignant gliomas. *Int J Radiat Oncol Biol Phys* 1995; 33: 461–468.
59. Souhami L, Seiferheld W, Brachman D et al. Randomized comparison of stereotactic radiosurgery followed by conventional radiotherapy with carmustine to conventional radiotherapy with carmustine for patients with glioblastoma multiforme: report of Radiation Therapy Oncology Group 93-05 protocol. *Int J Radiat Oncol Biol Phys* 2004; 60: 853–860.

60. Einstein DB, Wessels B, Bangert B et al. Phase II Trial of Radiosurgery to Magnetic Resonance Spectroscopy-Defined High-Risk Tumor Volumes in Patients with Glioblastoma Multiforme. *Int J Radiat Oncol Biol Phys* 2012; in press.
61. Chamberlain MC, Barba D, Kormanik P et al. Stereotactic radiosurgery for recurrent gliomas. *Cancer* 1994; 74: 1342–1347.
62. Kong DS, Lee JI, Park K et al. Efficacy of stereotactic radiosurgery as a salvage treatment for recurrent malignant gliomas. *Cancer* 2008; 112: 2046–2051.
63. Combs SE, Widmer V, Thilmann C et al. Stereotactic radiosurgery (SRS): treatment option for recurrent glioblastoma multiforme (GBM). *Cancer* 2005; 104: 2168–2173.