

RESEARCH LETTER

Dermobile: A cost-effective portable device for erythema evaluation

A common cause of skin erythema is the increased blood flow and angiogenesis associated with skin irritation. Visual assessment done by specialists is the gold standard for evaluating erythema.¹ Nevertheless, visual assessment alone has significant drawbacks since it depends heavily on the observer's experience and skills. Therefore, instrumental-based solutions were developed to overcome user subjectivity while providing an objective assessment of skin redness.

Narrow-band reflectance spectrophotometry devices are widely used devices in research studies for erythema evaluation.² This is probably due to their ease of use and quick data acquisition. One of the most well published devices is the spectrophotometer from Courage & Khazaka (Mexameter MX18, Courage Khazaka, Cologne, Germany). However, the evaluation of erythema using this device has several drawbacks. For example, its rather large head surface area ($\approx 4.5 \text{ cm}^2$) compared to the measuring surface area ($\approx 0.196 \text{ cm}^2$) hinders the precise selection of the area to be evaluated. Second, it is not possible to avoid, exclude, or compensate for any skin artifacts (i.e., hair, freckles or blemishes) which may affect the evaluations. These disadvantages and the device acquisition costs motivate to look for an inexpensive, accessible, and reliable alternative.

A dermatoscope assures a uniform and controlled illumination and fixed focal distance for skin examination.³ These illumination qualities of a dermatoscope in combination with the ubiquity of mobile phones and their sophisticated digital cameras create the possibility of having a low-cost, portable, analytical and diagnostic tool within every dermatologist's pocket.⁴ In this context we investigate in how far the combined use of a dermatoscope (Dermlite DL4, Dermlite, San Juan Capistrano, USA), a mobile phone (Samsung S10, Seoul, South Korea), and a universal smartphone adapter (Dermlite, San Juan Capistrano, USA) can be used as a tool for objective erythema measurements.

We conducted a prospective in-vivo, in human clinical trial to investigate the feasibility of using a combination of dermatoscope, adapter, and mobile phone—which we have named Dermobile—as an alternative to the Mexameter MX18 for objective skin erythema evaluation. The study was performed at the Geneva University Hospitals following the approval of the local ethical committee (BASEC2022-D0083) and the principles of the Declaration of Helsinki.⁵

Measurements were conducted on the volar forearm surface of twenty healthy adult volunteers between the ages of 19 and 47 years. All volunteers had a skin types II–IV, with no evidence of any relevant skin disease affecting the evaluation area (EA). Once the EA were defined and outlined, measurements were conducted inside that EA with the Mexameter MX18 and the Dermobile. For the Mexameter MX18 erythema index (EI) quantification values were automatically calculated by the device. For the Dermobile pictures were taken using cross-polarized light and manual photo mode (AE/AF lock, ISO 50, Shutter 1/350 F2.4 and white balance of 5500K; Figure 1A). Figure 1B illustrates the erythema value quantification procedure (measured as the a^* parameter)⁶ using FIJI software.

Despite the different measurement principles of the Mexameter MX18 (spectra-based assessment) and the Dermobile (image-based assessment), both rely on the evaluation of the colors red and green. These similarities would explain the high correlation observed between the measurements of both devices (Figure 1C; rho 0.87, adjusted R-squared 0.77), which is consistent with the "Guidelines for measurement of skin colour and erythema".⁷

Although the speed at which results are generated with the Mexameter MX18 remains unmatched, the Dermobile technique showed some major improvements. First, during the EA direct evaluation and image acquisition, or further processing of the images, it is easy to exclude skin artifacts from the erythema assessment. Second, image analysis is a precise, reliable, and automatic process with a measurement standard uncertainty of 0.4 (RSD 1.4; $n = 12$). A drawback of the Dermobile technique is a data acquisition variability due to increased pressure on the test site resulting in blanching of the skin. However, this can be corrected during the image acquisition process since the acquired image is visible at all times.

The combination of a dermatoscope (Dermlite DL4, San Juan Capistrano, USA) and a smartphone allowing for manual photo mode (Samsung S10, Samsung, Seoul, South Korea) can provide objective skin erythema assessments comparable to a well-established narrow-band reflectance spectrophotometer device (Mexameter MX18, Courage & Khazaka, Cologne, Germany).

This is an open access article under the terms of the [Creative Commons Attribution-NonCommercial-NoDerivs](https://creativecommons.org/licenses/by-nc-nd/4.0/) License, which permits use and distribution in any medium, provided the original work is properly cited, the use is non-commercial and no modifications or adaptations are made.

© 2024 The Authors. *Skin Research and Technology* published by John Wiley & Sons Ltd.

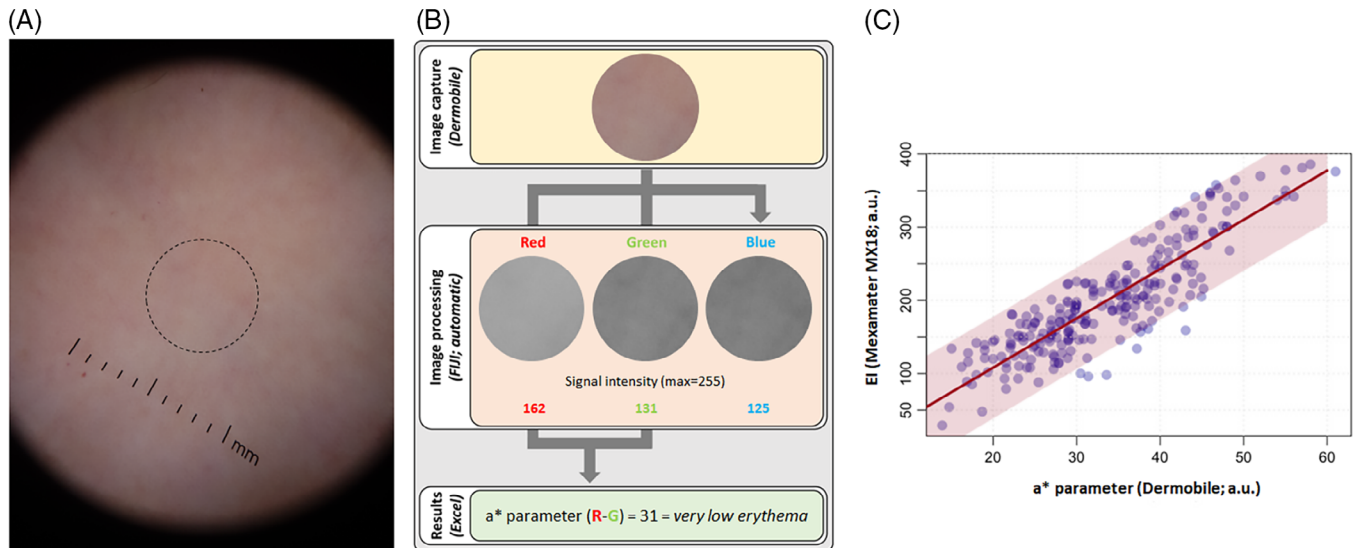


FIGURE 1 Illustration of the erythema evaluation procedure with the Dermobile and its relationship with Mexameter MX18 measurements. (A) Image of the skin as observed and captured by the device. The black dotted circle surrounds the area selected for evaluation. (B) Schematization of the a^* parameter assessment using Fiji software. (C) Assessment of the relationship between the measurements of the erythema intensity obtained with the Dermobile and the Mexameter MX18. Red line: linear regression. Light red zone: prediction interval with 95% confidence. A.U., arbitrary units; EI, erythema index.

ACKNOWLEDGMENTS

The research work presented in this manuscript was made possible through a research grant from Stratpharma Switzerland. The company was not involved in the investigation, investigation design, collection, analysis, interpretation of the data and/or writing of the report.

CONFLICT OF INTEREST STATEMENT

The authors declare they have no conflicts of Interest.

DATA AVAILABILITY STATEMENT

Data available on request from the authors.

ETHICS STATEMENT

The study was approved by the Local Ethics Committee (BASEC2022-D0083). All patients in this manuscript have given written informed consent for participation in the study and the use of their de-identified, anonymized, aggregated data and their case details for publication.

Sergio del Río-Sancho^{1,2}

David Alvarez Martinez¹

Jöri Pünchera¹

Stéphane Guerrier³

Hans Joachim Laubach^{1,2}

¹Laser Dermatology Consultation, Division of Dermatology and Venereology, Geneva University Hospitals, Geneva, Switzerland

²Pediatric Dermatology Unit, Departments of Dermatology & Venereology, University Hospital Lausanne, University of Lausanne, Lausanne, Switzerland

³GSEM & Faculty of Science, University of Geneva, Geneva, Switzerland

Correspondence

Hans Joachim Laubach, Laser Dermatology Consultation, Division of Dermatology and Venereology, Geneva University Hospitals, Geneva, Switzerland.

Email: hans-joachim.laubach@hcuge.ch

ORCID

Sergio del Río-Sancho <https://orcid.org/0000-0001-9353-9504>

Hans Joachim Laubach <https://orcid.org/0000-0002-6831-6517>

REFERENCES

- Angra K, Lipp MB, Sekhon S, Wu DC, Goldman MP. Review of post-laser-resurfacing Topical agents for improved healing and cosmesis. *J Clin Aesthet Dermatol*. 2021;14(8):24-32.
- Abdlaty R, Hayward J, Farrell T, Fang Q. Skin erythema and pigmentation: a review of optical assessment techniques. *Photodiagnosis Photodyn Ther*. 2021;33:102127.
- Marghoob AA, Usatine RP, Jaimes N. Dermoscopy for the family physician. *Am Fam Physician*. 2013;88(7):441-450.
- Switz NA, D'Ambrosio M V, Fletcher DA. Low-cost mobile phone microscopy with a reversed mobile phone camera lens. *PLoS One*. 2014;9(5):e95330-e95330.
- Rickham PP. Human Experimentation. Code of Ethics of the World Medical Association. Declaration of Helsinki. *Br Med J*. 1964;2(5402):177.
- Coelho SG, Miller SA, Zmudzka BZ, Beer JZ. Quantification of UV-induced erythema and pigmentation using computer-assisted digital image evaluation. *Photochem Photobiol*. 2006;82(3):651-655.
- Fullerton A, Fischer T, Lahti A, Wilhelm KP, Takiwaki H, Serup J. Guidelines for measurement of skin colour and erythema. A report from the Standardization Group of the European Society of Contact Dermatitis. *CD*. 1996;35(1):1-10.