


Synchronous or collision solid neoplasms and lymphomas

A systematic review of 308 case reports

Rafael Parra-Medina, MD, PhD^{a,b,c,*}, Franky Rocha, MD^a, Juan Pablo Castañeda-González, MD(st)^a , Paula Moreno-Lucero, MD^a, Luis Veloza, MD, PhD^d, Alfredo E. Romero-Rojas, MD^c

Abstract

Background: The presence of a lymphoma associated with a solid synchronous neoplasm or collision neoplasm has been rarely in the literature, and a detailed characterization of these cases is lacking to date.

Objective: To describe the main clinicopathological features of synchronous/collision tumors.

Methods: A systematic search in PubMed, Scielo, and Virtual Health Library literature databases for cases or case series of synchronous or collision lymphoma and other solid neoplasms reported up to March 2021 was performed. Three reviewers independently screened the literature, extracted data, and assessed the quality of the included studies. The systematic review was performed following the Preferred Reporting Items for Systematic Meta-Analyses guidelines.

Results: Mean age of patients was 62.9 years (52.9% men). A total of 308 cases were included (62% synchronous and 38% collision). The most frequent location of both synchronous and collision tumors was the gastrointestinal tract with the most common solid neoplasm being adenocarcinoma, and the most frequent lymphoma diffuse large B-cell lymphoma (21.7%) and mucosa-associated lymphoid tissue lymphoma (20.4%). Of the total number of mucosa-associated lymphoid tissue lymphomas and gastric adenocarcinomas, the presence of *Helicobacter pylori* infection was documented in 47.3% of them. Only 2% of all cases had a previous history of lymphoma. Thus, in most cases (98%), lymphoma was discovered incidentally. In addition, nodal lymphoma was associated with metastasis in 29 (9.4%) cases as collision tumor, most commonly (90%) in locoregional lymph nodes of the solid neoplasm.

Conclusions: The frequent association of some type of B-cell lymphoma and adenocarcinoma in synchronous/collision tumors of the gastrointestinal tract points to common pathogenic mechanisms in both neoplasia, particularly related to chronic inflammation in this location. In most cases, lymphoma identified in locoregional lymph nodes or distant of a carcinoma seems to represent an incidental finding during the carcinoma diagnostic/therapeutic approach. A synergy between carcinoma and lymphoma (involving inflammation and immunosuppression mechanisms) may favor tumor progression and dissemination. A better understanding of the interactions lymphoma/carcinoma in the setting of synchronous/collision tumors may help to improve patient management and prognosis.

Abbreviations: AITL = angioimmunoblastic T-cell lymphoma, ALCL = anaplastic large cell lymphoma, CHL = classic Hodgkin lymphoma, CLL/SLL = chronic lymphocytic leukemia/small cell lymphocytic lymphoma, CTCL = cutaneous T-cell lymphoma, DLBCL = diffuse large B-cell lymphoma, FL = follicular lymphoma, HL = Hodgkin's lymphoma, LPS-NOS = lymphoproliferative syndrome not otherwise specified, MALT = mucosa-associated lymphoid tissue, MCL = mantle cell lymphoma, MZL = marginal zone lymphoma, NHL = non-Hodgkin lymphoma, NHL-NOS = unspecified non-Hodgkin's lymphomas, NKTCL = natural killer T-cell lymphoma, NLPHL = nodular lymphocyte-predominant Hodgkin lymphoma, PCNSL = primary central nervous system lymphoma, PEL = pleural effusion lymphoma, PNL-NL = paranasal sinus lymphoma, PTCL = peripheral T-cell lymphoma, SCC = squamous cell carcinoma, SD = standard deviation, VHL = Virtual Health Library.

Keywords: adenocarcinoma, collision, lymphoma, synchronous

Compliance with Ethical Standards: Not applicable. The authors have no funding and conflicts of interest to disclose.

All data generated or analyzed during this study are included in this published article (and its supplementary information files).

Ethics committee: This article does not require an ethics approval as it does not collect any primary data from patients.

Supplemental Digital Content is available for this article.

^a Department of Pathology, Fundación Universitaria de Ciencias de la Salud, Hospital San José, Bogotá, Colombia, ^b Research Institute, Fundación Universitaria de Ciencias de la Salud, Bogotá, Colombia, ^c Department of Pathology, Instituto Nacional de Cancerología, Bogotá, Colombia, ^d Institute of Pathology, Lausanne University Hospital, Lausanne University, Lausanne, Switzerland.

*Correspondence: Rafael Parra-Medina, Department of Pathology, Fundación Universitaria de Ciencias de la Salud, Hospital San José, Calle 10N. 18-75, Bogotá, Colombia (e-mail: rafa.parram@gmail.com).

Copyright © 2022 the Author(s). Published by Wolters Kluwer Health, Inc. This is an open-access article distributed under the terms of the Creative Commons Attribution-Non Commercial License 4.0 (CCBY-NC), where it is permissible to download, share, remix, transform, and buildup the work provided it is properly cited. The work cannot be used commercially without permission from the journal.

How to cite this article: Parra-Medina R, Rocha F, Castañeda-González JP, Moreno-Lucero P, Veloza L, Romero-Rojas AE. Synchronous or collision solid neoplasms and lymphomas: A systematic review of 308 case reports. *Medicine* 2022;101:28(e28988).

Received: 2 November 2021 / Received in final form: 29 January 2022 / Accepted: 13 February 2022

<http://dx.doi.org/10.1097/MD.00000000000028988>

1. Introduction

Lymphomas represent a large group of malignant neoplasms arising from T or B cells. Based on the latest 2017 World Health Organization classification, there are more than 80 mature lymphoid neoplasms (B-cell and T-cell lymphomas [TCL]) that are defined by their clinical characteristics, location, morphology, immunophenotype, and genetic and molecular profiles.^[1] By 2020, there were an estimated 83,087 new cases of and 23,376 deaths from Hodgkin's lymphoma (HL) and an estimated 544,352 new cases of and 259,793 deaths from non-Hodgkin lymphoma (NHL) worldwide.^[2,3]

NHL mainly affects lymph nodes and can, less frequently, involve extranodal sites, especially the gastrointestinal system in up to 45% of cases (stomach 74%, small intestine 8.7%, and colon 6.5%), followed by the head and neck, 24% (Waldeyer ring 9.3%, nasal 8%, oral cavity 4%, thyroid 3.9%, salivary gland 3%, ocular and retroocular adnexa 2.6%, and paranasal sinuses 1.8%); skin, 15%; and organs such as lung, kidney, and breast, less frequently.^[4,5]

Isolated cases of lymphomas associated with other solid neoplasms have been reported in the scientific literature. Most cases correspond to carcinoma and lymphoma in gastrointestinal tract.^[6,7] However, there are no systematic reviews of the literature that characterize the clinicopathological features of synchronous or collision neoplasms. Therefore, the objective of this systematic review was to describe the main clinicopathological features of synchronous/collision tumors, particularly tumor location and histological subtypes and to propose possible explanations to the rare occurrence of lymphoma and carcinoma in the setting of synchronous/collision tumors.

2. Materials and Methods

2.1. Search strategy

A systematic literature review of clinical cases published in PubMed, Scielo, and Virtual Health Library was done. The search was done using the following terms: ("Adenocarcinoma" OR "Carcinoma" OR "Carcinoma, Squamous Cell" OR "Sarcoma" OR "Melanoma") AND ("Lymphoma") AND ("synchronous" OR "collision"). Preferred Reporting Items for Systematic Meta-Analyses guidelines were followed during data extraction, analysis, and reporting.^[8] Articles published up to March 2021 were included. Articles available in all languages were considered.

2.2. Study selection, data extraction, and quality assessment

The inclusion criteria for the systematic review were as follows: clinical cases with the presence of lymphoma and another malignant neoplasm in any solid organ that were published as "synchronous" or in "collision." All of the cases that did not mention the primary location of the solid tumor and/or lymphoma were excluded as were all those where there was prior chemotherapy treatment for other tumors.

Three reviewers examined all the titles and abstracts of the publications to assess their eligibility. The retrieved articles were rejected if the inclusion criteria were not met. A fourth reviewer was consulted when the eligibility criteria were not clear. Manual searches were done of articles that appeared to be relevant. The data extracted from each article were: personal information (name of lead author, year of publication, age, gender, follow-up, and survival), information on lymphoma (anatomical location, classification, and histopathological grade), and information on the accompanying solid neoplasm (anatomical location, histopathological classification, and number and location of metastases).

Synchronous tumor was defined as the presence of a lymphoma and that of another type of tumor diagnosed at the same

time or within a period of less than 6 months. A collision tumor was defined as the presence of 2 synchronous tumors in the same organ without the presence of nonneoplastic tissue between the primary tumors.^[9,10] The findings were organized by anatomical location. The tumors in the gastrointestinal tract were classified as synchronous or collision cases of the oral cavity, pharynx, esophagus, stomach, small intestine (duodenum, jejunum, and ileum), liver, gallbladder and biliary tract, colon (ileocecal valve, cecum, appendix, ascending, transverse, and descending colon), rectum, and anus. Tumors of the respiratory tract were classified as laryngeal, tracheal, bronchial, pulmonary parenchyma, and pleural tumors. The cases reported in the female reproductive system were classified as breast, vaginal, cervical, endometrial, and ovarian tumors. Male genital tumors were classified as prostate, penile, and testicular tumors, and urological tumors were divided into renal and bladder. The cases that presented in the endocrine organs were classified as thyroid, pancreatic, and adrenal gland tumors. Other tumors that were found were anatomically classified as ocular, bone marrow, skin, and cutaneous adnexal tumors.

The quality assessment of each published case report was done using a modified evaluation tool that has been used in other recent systematic reviews.^[11] Three researchers (F.R., J.P.C.-G., P.M.L.) evaluated each article independently based on 3 aspects: suitable description of each patient (medical history, laboratory, and radiological findings), accurate diagnoses were provided (diagnosis of lymphoma and solid organ tumor confirmed by histopathology), and sufficient and convincing evidence was presented for the diagnoses of the different neoplasms (the lymphoma and solid organ tumors were confirmed by immunohistochemistry, or the histopathological images were shown in the article, and the images were interpreted by a pathologist).

3. Results

3.1. Systematic review of the literature

A total of 430 articles were identified in the databases. Of these, 9 duplicates were identified and excluded, and 118 articles were rejected initially for title or abstract. Then, the 303 full-text or summary articles based on case reports or case series were evaluated for eligibility. Of these, 256 articles containing data that could be interpreted and meet the eligibility criteria were included (Fig. 1).^[12-262] The data were extracted from the abstract in 34 articles,^[17,37-39,64,75,76,78,81,94,97,103,129,134,151,162,166,170,174,176,192,195,212,221,222,229,232,234,251,252,256,260-262] of which 21 were in English, 5 in Japanese, 3 in Spanish, 2 in French, 2 in Chinese, and 1 in Czech.

The flowchart for the systematic literature review and the articles included in the analysis are shown in Figure 1. The detailed information is shown in Table S1, Supplemental Digital Content (<http://links.lww.com/MD/G862>).

3.2. Quality assessment

An accurate diagnosis was provided in 83.4%, and convincing evidence of the diagnosis was provided in 61.3%. The majority of the cases reported an appropriate description of the patient's medical history and laboratory or radiological findings (73.7%) (Table S2, Supplemental Digital Content, <http://links.lww.com/MD/G863>). Some cases did not show explicitly or robust immunohistochemistry evidence for the diagnosis; however, the histopathological images of these cases were further analyzed by all authors in order to confirm the diagnosis provided.

3.3. General characteristics

A total of 308 cases of lymphoma associated with another solid neoplasia in any organ were analyzed. They were classified as synchronous tumors in n = 191 (62%) cases and as collision

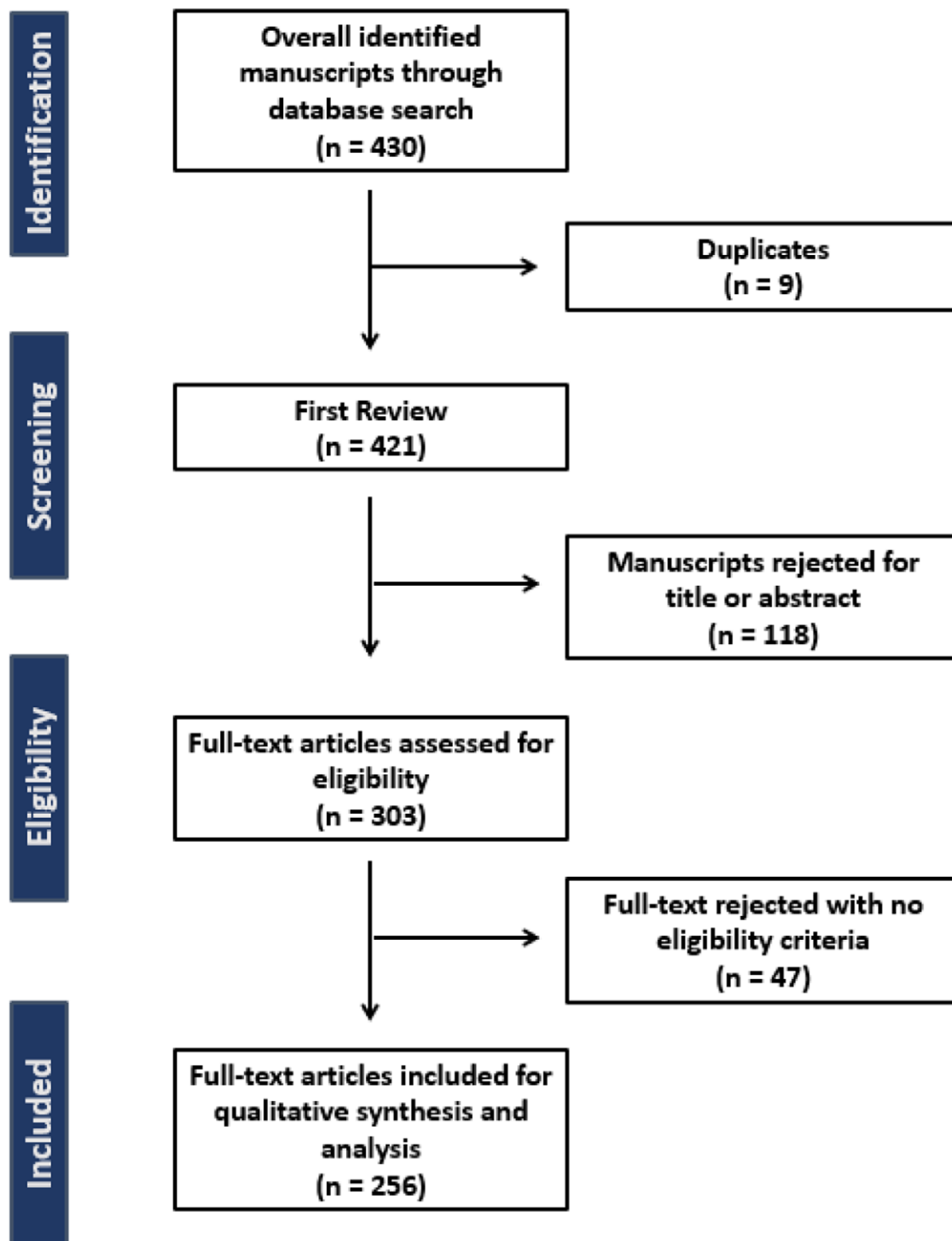


Figure 1. Systematic literature review flowchart.

tumors in $n = 117$ (38%). The mean age of the patients was 62.9 years (SD, 13.2 years) with 163 men, 137 women, and 9 cases with no data available (Table 1).

In 117 cases, the presence of solid neoplasm metastases was reported. The most frequent type of synchronous or coliding metastatic neoplasia was adenocarcinoma with 56 cases (18.1%), followed by breast carcinoma with 17 cases (5.5%), squamous cell carcinoma (SCC) with 14 cases (4.5%), and melanoma with 6 cases (1.9%), among others less frequent.

In 233 patients, the follow-up information was available. Survival from diagnosis/treatment was variable. Fifty-eight

(24.9%) patients dying (mean, 17.8 months; range, 2 days to 11 years) (Table S1, Supplemental Digital Content, <http://links.lww.com/MD/G862>).

3.4. Histological subtypes of lymphomas

Of the total number of lymphomas, 285 (92.5%) were NHL. Of these, the most frequent were diffuse large B-cell lymphoma (DLBCL) $n = 67$ (21.7%), mucosa-associated lymphoid tissue (MALT) $n = 63$ (20.4%), follicular lymphoma (FL) $n = 42$ (13.6%), chronic lymphocytic leukemia/small cell lymphocytic

Table 1

Characteristics of patients with lymphomas and synchronous or collision solid neoplasms

Solid neoplasm	Lymphoma																			Total				
	HL									NHL														
	CHL	NLPHL	DLBCL	MALT	FL	CLL/SLL	MCL	NHL-NOS	MZL	TCL-NOS	PCNSL	LBL	LPL	HS	PTCL	CTCL	BL	BIA-ALCL	PILL		PEL	AITL	NKTCL	LPS-NOS
Age (yr), mean	51	68	63	63	60	65	68	64	67	57	61	63	50	68	69	33	62	59	56	28	79	63	83	63
Gender																								
Male	11	2	34	28	20	15	20	12	3	3	2	2	1	2	2	1	1	0	1	1	0	1	1	1
Female	7	2	32	29	21	24	5	6	4	2	2	0	1	0	0	0	0	1	0	0	1	0	0	0
Non available	0	0	0	6	0	0	0	2	0	0	0	0	0	0	0	0	0	0	0	0	0	0	0	0
Localization																								
Stomach	5	1	18	38	4	2	2	5	0	1	1	0	0	2	0	0	0	0	0	0	0	0	0	0
Small intestine	1	0	0	1	0	0	0	0	0	0	0	0	0	0	0	0	0	0	0	0	0	0	0	0
Colon	2	1	12	4	8	3	4	2	1	1	1	1	0	0	0	0	0	1	0	1	0	1	0	0
Rectum	0	2	0	1	2	0	0	0	1	0	1	0	1	0	1	0	0	0	0	0	0	0	0	0
Breast	1	0	12	2	10	13	2	1	1	0	0	0	0	0	0	0	0	1	0	0	0	0	0	0
Lung	1	0	7	10	1	2	7	4	0	1	0	0	1	0	0	0	0	0	0	0	0	0	0	0
Kidney	1	0	5	1	2	6	2	2	0	1	1	0	0	0	0	0	1	0	0	0	0	0	0	0
Bladder	0	0	2	0	0	1	0	0	0	0	0	0	0	0	0	0	0	0	0	0	0	0	0	0
Skin and appendages	0	0	3	0	1	7	3	0	1	0	0	0	0	0	1	1	0	0	0	1	0	0	0	0
Ovary	1	0	1	0	0	0	0	1	0	0	0	0	0	0	0	0	0	0	0	0	0	0	0	0
Endometrium	0	0	1	0	2	0	0	0	0	0	0	0	0	0	0	0	0	0	0	0	0	0	0	0
Cervix	1	0	0	0	0	1	0	0	0	0	0	0	0	0	0	0	0	0	0	0	0	0	0	0
Thyroid	2	0	2	2	2	1	0	0	0	0	0	0	0	0	0	0	0	0	0	0	0	0	0	0
Palate, tongue	0	0	0	0	3	2	0	0	0	0	0	0	0	0	0	0	0	0	0	0	0	0	0	0
Tonsil	0	0	0	0	1	1	0	0	0	0	0	0	0	0	0	0	0	0	0	0	0	0	0	0
Salivary gland	1	0	0	0	0	0	1	0	1	0	0	0	0	0	0	0	0	0	0	0	0	0	0	0
Oropharynx/nasopharynx	1	0	1	1	0	0	0	0	0	0	0	0	0	0	0	0	0	0	0	0	0	0	0	0
Larynx	1	0	0	0	0	0	0	2	1	1	0	0	0	0	0	0	0	0	0	0	0	0	0	0
Esophagus	0	0	0	0	0	0	1	0	1	0	0	0	0	0	0	0	0	0	0	0	0	0	0	0
Liver	0	0	3	1	2	0	0	0	0	0	0	1	0	0	0	0	0	0	0	0	0	0	0	0
Gallbladder and bile duct	0	0	0	0	2	0	1	0	0	0	0	0	0	0	0	0	0	0	0	0	0	0	1	3
Pancreas	0	0	0	0	1	0	1	0	0	0	0	0	0	0	0	0	0	0	0	0	0	0	0	0
Prostate gland	0	0	0	2	0	0	1	0	0	0	0	0	0	0	0	0	0	0	0	0	0	0	0	0
Penis	0	0	0	0	0	0	1	0	0	0	0	0	0	0	0	0	0	0	0	0	0	0	0	0
Vagina	0	0	1	0	0	0	0	0	0	0	0	0	0	0	0	0	0	0	0	0	0	0	0	0
Peritoneum	0	0	0	0	1	0	0	0	0	0	0	0	0	0	0	0	0	0	0	0	0	0	0	0
Total	18	4	68	63	42	39	25	17	7	5	4	2	2	2	2	1	1	1	1	1	1	1	1	308

AITL = angioimmunoblastic T-cell lymphoma, BIA-ALCL = breast implant-associated anaplastic large cell lymphoma, BL = Burkitt lymphoma, CHL = classical Hodgkin lymphoma, CLL/SLL = chronic lymphocytic leukemia/small lymphocytic lymphoma, CTCL = cutaneous T cell lymphoma, DLBCL = diffuse large B-cell lymphoma, FL = follicular lymphoma, HL = Hodgkin's lymphoma, HS = histiocytic sarcoma, LBL = lymphoblastic sarcoma, LPL = lymphoplasmacytic lymphoma, LPS-NOS = low-grade nonclassifiable lymphoproliferative syndrome, MALT = mucosa-associated lymphoid tissue, MCL = mantle cell lymphoma, MZL = marginal zone lymphoma, NHL-NOS = non-Hodgkin lymphoma—not otherwise specified, NKTCL = natural killer/T-cell lymphoma, NLPHL = nodular lymphocyte predominant Hodgkin lymphoma, PCNSL = primary central nervous system lymphoma, PEL = primary effusion lymphoma, PILL = primary lung lymphoma, PTCL = peripheral T-cell lymphoma, TCL-NOS = T-cell lymphoma—not otherwise specified.

lymphoma (CLL/SLL) $n = 39$ (12.6%), mantle cell lymphoma (MCL) $n = 25$ (8.1%), unspecified non-Hodgkin's lymphomas not otherwise specified (NHL-NOS) $n = 18$ (5.8%), and a few others that were less frequent. Only 22 (7.1%) were HL, of which 18 cases (5.8%) were found to be classic Hodgkin lymphoma (CHL) (10 cases of nodular sclerosis CHL and 8 cases of mixed cellularity CHL) followed by nodular lymphocyte-predominant Hodgkin Lymphoma in 4 cases. One case (0.3%) was classified as lymphoproliferative syndrome not otherwise specified (Table 1).

The lymphomas most frequently found synchronous with a solid neoplasm were DLBCL in 41 (13.3%) cases followed by MALT lymphoma in 37 (12%), FL in 30 (9.7%), MCL in 17 (5.5%), CLL/SLL in 15 (4.8%), and NHL-NOS in 12 (3.8%) (Tables 1 and 2).

Among the lymphomas most frequently in collision with a solid neoplasm were DLBCL in 26 (8.4%) cases, MALT in 26 (9%), CLL/SLL in 24 (7.7%), FL in 12 (3.8%), MCL in 8 (2.5%), and NHL-NOS in 6 (1.9%) cases (Tables 1 and 2).

We found 6 cases (2%), in which the presence of lymphoma associated with synchronous carcinoma was documented in the context of a previous history of lymphoma.^[38,119,212,215,255,257] Of these, 3 cases were synchronous SLL/CLL associated with breast carcinoma, melanoma, and Merkel cell carcinoma. The rest of the cases corresponded to MALT-type lymphoma, MCL, and NOS-NHL, all of them associated with adenocarcinoma. In 3 of the 6 cases, the presence of metastases from the solid neoplasm was reported. The time period between diagnosis of the initial lymphoma and discovery of the collision and ranged from 12 months to 25 years, with a mean of 14.6 years. We found that, of the 6 cases described, 3 had a fatal outcome shortly after the start of treatment for colliding neoplasms.

3.5. Histological subtypes of solid neoplasia

The most common histological type of solid organ neoplasm was adenocarcinoma in 50% ($n = 154$) of the cases. Of these, the most frequent location was in the stomach, with 73 cases (23.7%) of which 41 were synchronous and 32 in collision. Second, colon and rectal adenocarcinomas were found with 50 cases (13.1%), of which 34 were synchronous and 16 were collision. Lung adenocarcinoma was found in third place, with 15 cases (4.8%) of which 8 were synchronous and 7 were collision. In second place, the SCC was found in 11.6% ($n = 36$) of the cases. Of these, 12 cases were found in the lung (3.8%) with 10 synchronous cases and 2 in collision. Five cases of SCC in the larynx were registered, all of them synchronous. Four skin SCCs (1.2%) were recorded, of which 3 cases were synchronous and only 1 collision case was found. In addition, 4 cases of tongue SCC (1.2%) were recorded with 3 synchronous cases and only 1 case in collision with a lymphoma. In third place, ductal breast carcinoma was found in 11% ($n = 34$) of the cases (Table S2, Supplemental Digital Content, <http://links.lww.com/MD/G863>).

3.6. Location of lymphomas

The most frequent location of NHL was nodal, with 92 cases (29.8%) of which 63 were synchronous and 29 were in collision. The most frequent extranodal location was gastric NHL with 64 cases (20.7%), of which 33 cases were found in collision and 31 cases were synchronous. Subsequently, lymphomas located in the breast and lung registered 17 cases each (5.5%); in lung, 9 synchronous cases and 8 NHL collision cases were recorded, while in breast, 9 collision cases and 8 NHL synchronous cases were found. Lymphomas of the duodenum, jejunum, and ileum registered 12 cases (3.8%), 10 cases of collision, and 2 synchronous. Lymphomas of the colon and ileocecal regions registered 11 cases (3.5%), of which 7 cases were in collision

and 4 cases were synchronous. NHLs occurred less frequently in other organs such as skin ($n = 7$), liver ($n = 6$), spleen ($n = 6$), and central nervous system ($n = 4$), among others.

The most frequent location of HL was nodal, with 19 cases (6.1%), of which 3 cases were in collision, and the rest were synchronous. Of the 3 remaining cases, 1 was a collision LH in the uterine cervix, another was a collision LH in the stomach, and the last case was a mediastinal synchronous LH (Table S1, Supplemental Digital Content, <http://links.lww.com/MD/G862>).

3.7. Location of synchronous and collision tumors

The organs where a synchronous tumor was most often seen were in the stomach in 43 (13.9%) cases followed by the colon in 29 (9.4%), the breast in 24 (7.7%), the lung in 23 (7.4%), and kidney in 19 (6.1%). And the organs where a collision tumor was most often seen were in the stomach in 36 (11.6%) cases followed by the breast in 19 (6.1%), the colon in 15 (4.8%), the lung in 11 (3.5%), and the skin in 11 (3.5%).

In 150 (48.7%) cases (Table 2), both neoplasms were found in the same organ and, of these, 86 (57.3%) were in collision (35 cases in the stomach, 11 in the colon, 9 in the breast, 8 in the lung, and a smaller proportion in other organs) and 64 (42.6%) synchronously (32 cases in the stomach, 10 in the breast, 8 in the lung, 7 in the colon, and to a lesser degree in other organs).

In 80 (25.9%) cases, lymphoma de novo synchronous with a solid neoplasm was found in a lymph node. Of these, 16 cases (20%) were HL, including 6 cases of mixed cellularity CHL, 6 cases of nodular sclerosis CHL, and 4 cases of NLPHL. The remaining 64 cases corresponded to NHL (81.2%) including 22 cases of FL, 11 cases of DLBCL, 9 cases of CLL/SLL, 8 cases of MCL, and 2 cases of marginal zone lymphoma (MZL), among others less frequent. Of these cases of nodal synchronous lymphomas, the lymph node was regional in 60 (75%) cases, and the lymph node was distant in 20 (25%) cases. In 29 (9.4%) cases, a collision tumor in a nodal lymphoma associated with the metastasis of a solid neoplasm was seen (10 breast carcinomas, 4 head and neck SCC, 4 skin melanomas, 2 colon adenocarcinomas, 2 gastric adenocarcinomas, and 2 lung carcinomas, among others), 26 were (CLL/SLL: 17, FL: 4, DLBCL: 2, MCL:2, MZL:1) in nodes regional to the solid neoplasm and 3 in a distant lymph node associated with CHL ($n:2$) and FL ($n:1$) (Table 3).

3.8. Tumors of the gastrointestinal tract

Tumors in the gastrointestinal tract were the most frequent. Of the total number of cases, 73 (23.7%) were found to be gastric adenocarcinomas, of which 38 (52%) were associated with a MALT lymphoma, 15 in collision. Of the total number of MALT lymphomas and gastric adenocarcinomas, the presence of *Helicobacter pylori* was documented in 47.3% of them. In 26 (17.6%) cases, DLBCL was associated with adenocarcinoma. Fourteen were in the stomach (6 in collision), 3 were regionally synchronous (small intestine, ileocecal region, and abdominal region), 1 synchronous and in a para-aortic lymph node, and 1 synchronous to the inguinal lymph node. Eight (5.4%) cases were associated with CHL, 1 was synchronous and in the supraclavicular lymph node, 2 synchronous and in the cervical lymph node, 1 in collision in the perigastric node, and 1 in collision in the supraclavicular node. Four (5.2%) cases were associated with CHL, 5 synchronous and in lymph nodes (mesenteric and inguinal) and 3 in collision, and 3 (2%) associated with NHL-NOS, 2 in collision in the stomach and 1 synchronous and in the stomach.

In the colon, 43 cases were adenocarcinomas. Of these, 12 (27%) were associated with DLBCL, 5 in collision, 6 synchronous in the small intestine, and 3 in the same organ, 1 synchronous, and in the cervical lymph node, 1 in collision in the small intestine and 1 in collision in the perirectal lymph node. Eight

Table 2

Lymphomas and synchronous or collision solid neoplasms in the same organ.

Organ	Solid neoplasm	Lymphoma	S	C	Total
Palate	Squamous cell carcinoma	Small lymphocytic lymphoma		1	1
Larynx	Squamous cell carcinoma	T-cell lymphoma (N/A)	1		1
Liver	Myeloid sarcoma	Diffuse large B-cell lymphoma		1	1
	Hepatocellular carcinoma	MALT lymphoma	1		1
	Kaposi's sarcoma	Diffuse large B-cell lymphoma		1	1
Gallbladder	Adenocarcinoma	Low-grade nonclassifiable lymphoproliferative syndrome		1	1
Ampulla of Vater	Adenocarcinoma	Follicular lymphoma		1	1
Stomach	Adenocarcinoma	MALT lymphoma	22	15	37
		Diffuse large B-cell lymphoma	5	6	11
		Follicular lymphoma		2	2
		Histiocytic sarcoma		2	2
		Lymphoplasmocytic lymphoma		1	1
		Mantle cell lymphoma	2		2
		Non-Hodgkin's lymphoma (N/A)	1	2	3
		Small lymphocytic lymphoma		2	2
		T-cell lymphoma (N/A)		1	1
		Non-Hodgkin's lymphoma (N/A)	1		1
	Carcinoma NOS	Diffuse large B-cell lymphoma		2	2
	Kaposi's sarcoma	Diffuse large B-cell lymphoma		1	1
	Histiocytic sarcoma	Diffuse large B-cell lymphoma		1	1
	Gastric GIST	Non-Hodgkin's lymphoma (N/A)	1		1
	Lymphoepithelioma-like carcinoma	Diffuse large B-cell lymphoma		1	1
Colon	Adenocarcinoma	Diffuse large B-cell lymphoma	3	3	6
		Follicular lymphoma		2	2
		MALT lymphoma	1	2	3
		Mantle cell lymphoma	1	1	2
		Marginal zone lymphoma		1	1
		Natural killer T-cell lymphoma	1		1
		Non-Hodgkin's lymphoma (N/A)		2	2
		Small lymphocytic lymphoma	1		1
Rectum	Adenocarcinoma	Peripheral T-cell lymphoma		1	1
Breast	Ductal breast carcinoma	Breast-implant associated anaplastic large cell lymphoma	1		1
		Diffuse large B-cell lymphoma	3	4	7
		MALT lymphoma		2	2
		Mantle cell lymphoma	2		2
		Non-Hodgkin's lymphoma (N/A)		1	1
		Small lymphocytic lymphoma		2	2
	Lobular breast carcinoma	Diffuse large B-cell lymphoma	1		1
		Follicular lymphoma	1		1
		Marginal zone lymphoma	1		1
	Mucinous breast carcinoma	Diffuse large B-cell lymphoma	1		1
Nasopharynx	Squamous cell carcinoma	MALT lymphoma		1	1
Lung	Adenocarcinoma	Diffuse large B-cell lymphoma	1		1
		MALT lymphoma	4	3	7
		Mantle cell lymphoma		2	2
	Neuroendocrine tumor	MALT lymphoma		1	1
	Squamous cell carcinoma	Lymphoplasmocytic lymphoma	1		1
		MALT lymphoma	2	1	3
		T-cell lymphoma (N/A)		1	1
Kidney	Clear cell renal cell carcinoma	Burkitt lymphoma		1	1
		Diffuse large B-cell lymphoma		1	1
		MALT lymphoma	1		1
		Non-Hodgkin's lymphoma (N/A)		1	1
Bladder	Squamous cell carcinoma	Diffuse large B-cell lymphoma		1	1
	Urothelial carcinoma NOS	Diffuse large B-cell lymphoma		1	1
Ovary	Adenocarcinoma	Non-Hodgkin's lymphoma (N/A)		1	1
Nasal root	Melanoma	Small lymphocytic lymphoma		1	1
Skin (neck)	Melanoma	Mantle cell lymphoma		1	1
Inguinal crease	Squamous cell carcinoma	Cutaneous T-cell lymphoma	1		1
Eyelid	Kaposi's sarcoma	Diffuse large B-cell lymphoma		1	1
Face	Kaposi's sarcoma	Diffuse large B-cell lymphoma		1	1
	Lymphoepithelioma-like carcinoma	Marginal zone lymphoma		1	1
	Merkel cell carcinoma	Small lymphocytic lymphoma		1	1
Eyelid	Endocrine mucin-producing sweat gland carcinoma	Mantle cell lymphoma		1	1
Thyroid	Papillary thyroid carcinoma	MALT lymphoma		1	1
		Diffuse large B-cell lymphoma	1		1
	Warthin-like papillary carcinoma	MALT lymphoma	1		1
Prostate	Adenocarcinoma	MALT lymphoma	1		1
Tonsil	Squamous cell carcinoma	Follicular lymphoma		1	1
		Total	64	85	149

AQ7 GIST = gastrointestinal stromal tumor, MALT = mucosa-associated lymphoid tissue, N/A = not available, NOS = not otherwise specified.

Table 3**Collision lymphomas observed in lymph nodes associated with metastases from solid tumors.**

Author	Year	Age	Gender	Solid neoplasm	Lymphoma	Localization of collision
Haynes, H	2019	N/A	F	Ductal breast carcinoma	Small lymphocytic lymphoma	Lymph node (axillary)
Wahner, D	2011	87	F	Ductal breast carcinoma	Small lymphocytic lymphoma	Lymph node (axillary)
Wahner, D	2011	62	F	Ductal breast carcinoma	Small lymphocytic lymphoma	Lymph node (axillary)
Wahner, D	2011	58	F	Ductal breast carcinoma	Small lymphocytic lymphoma	Lymph node (axillary)
Wahner, D	2011	67	F	Ductal breast carcinoma	Small lymphocytic lymphoma	Lymph node (axillary)
Wahner, D	2011	46	F	Ductal breast carcinoma	Small lymphocytic lymphoma	Lymph node (axillary)
Cuff, K	2010	74	F	Ductal breast carcinoma	Small lymphocytic lymphoma	Lymph node (axillary)
Cuff, K	2010	54	F	Ductal breast carcinoma	Small lymphocytic lymphoma	Lymph node (axillary)
Wahner, D	2011	69	F	Cribiform breast carcinoma	Small lymphocytic lymphoma	Lymph node (axillary)
Wahner, D	2011	69	F	Lobular breast carcinoma	Small lymphocytic lymphoma	Lymph node (axillary)
Fernández, B	2018	65	F	Breast carcinoma	Follicular lymphoma	Lymph node (axillary)
Kampalath, B	2003	58	F	Lung small cell carcinoma	Mantle cell lymphoma	Lymph nodes (hilar)
Ikemura, S	2018	67	M	Lung adenocarcinoma	Diffuse large B-cell lymphoma	Lymph nodes (mediastinum)
Tillawi, I	2007	59	M	Gastric adenocarcinoma	Hodgkin's lymphoma, classical	Lymph node (supraclavicular)
Fink, L	1990	74	M	Gastric adenocarcinoma	Small lymphocytic lymphoma	Lymph node (perigastric)
Acosta, A	2017	62	M	Colon adenocarcinoma	Follicular lymphoma	Lymph nodes (retroperitoneal)
Soto, A	2018	79	M	Colon adenocarcinoma	Diffuse large B-cell lymphoma	Lymph nodes (perirectal)
Sachdev, R	2017	55	M	Duodenum adenocarcinoma	Hodgkin's lymphoma, classical	Lymph node (cervical)
García, J	2009	52	F	Pancreas adenocarcinoma	Follicular lymphoma	Lymph node (supraclavicular)
Singhal, N	2009	60	F	Ovarium serous carcinoma	Hodgkin's lymphoma, classical	Lymph nodes (para-aortic)
Minca, E	2010	52	M	Tonsil squamous cell carcinoma	Small lymphocytic lymphoma	Lymph node (cervical)
McElroy, C	2009	57	M	Tongue squamous cell carcinoma	Small lymphocytic lymphoma	Lymph node (cervical)
Kakarala, K	2010	73	M	Salivary gland squamous cell carcinoma	Marginal zone lymphoma	Lymph node (cervical)
Popivanov, G	2018	48	F	Papillary thyroid carcinoma	Follicular lymphoma	Lymph node (paratracheal)
Dos Santos, H	2015	71	M	Malar region squamous cell carcinoma	Small lymphocytic lymphoma	Lymph node (cervical)
El Demellawy, D	2007	58	M	Back melanoma	Small lymphocytic lymphoma	Lymph node (axillary)
Cantor, A	2010	87	M	Scalp melanoma	Small lymphocytic lymphoma	Lymph node (cervical)
Addada, J	2010	73	M	Left thigh melanoma	Mantle cell lymphoma	Lymph nodes (pelvis)
Dueber, J	2013	39	M	Back melanoma	Small lymphocytic lymphoma	Lymph node (axillary)

N/A = not available.

(18.6%) cases were associated with FL, 2 in collision, 2 synchronous and in the small intestine, 1 synchronous and in the inguinal node, 1 synchronous and in the mesenteric node, 1 in collision in the duodenum, and 1 in collision in the retroperitoneal node. Five (11.6%) cases were associated with MALT, 1 of these was synchronous and in the small intestine, 1 synchronous and in the buccal mucosa, and 1 in collision in the same organ. Four (9.3%) cases were associated with MCL, 2 synchronous and in lymph nodes (mesocolic), 1 synchronous and in the duodenum, and 1 collision in the cecum.

In the rectum, there were 8 cases of adenocarcinomas, of which 2 were synchronously associated with FL in axillary and inguinal lymph nodes, and 2 were synchronously associated with nodular lymphocyte-predominant Hodgkin Lymphoma in axillary and retroperitoneal lymph nodes. One was associated with a synchronous MALT lymphoma in the jejunum, 1 with a synchronous MZL in the splenic lymph node, 1 associated with a synchronous primary central nervous system lymphoma, and 1 associated with peripheral T cell lymphoma (PTCL) in collision in the same organ. An adenocarcinoma was found in the small intestine associated with a synchronous CHL in the cervical lymph node. Other solid neoplasms associated with lymphomas were found less frequently.

3.9. Mammary gland tumors

Breast carcinomas were the second most common solid neoplasm. Ductal carcinoma was the most common subtype of tumor with 34 cases. Of these, 11 (32.3%) were associated with CLL/SLL, 10 of them in collision in the breast, 1 synchronous and in the axillary lymph node, and 10 in collision in the axillary lymph node. Ten (29.4%) were associated with DLBCL, 7 in the same organ (4 in collision), 2 synchronous and in the axillary ganglion, and 1 synchronous and in the tonsils. Seven (20.5%) were associated with FL in the axillary lymph node. Two were

associated with collision MALT lymphoma in the same organ, and 2 with synchronous MCL in the axillary lymph node.

Lobular carcinoma was found in 5 cases, of which 2 were associated with FL. One of these was synchronous and in the axillary lymph node, and 1 synchronous and in the submammary mass. One case was associated with synchronous DLBCL in the same organ. One case was associated with synchronous MZL in the same organ, and 1 case with CLL/SLL in collision in axillary lymph node.

Nonspecific breast carcinoma was found in 1 case, 1 associated with a synchronous mixed cellularity classic HL in the axillary lymph node and 1 associated with unspecified NHL in collision in the lymph node. Other solid neoplasms associated with lymphomas were found less frequently.

3.10. Lung tumors

Lung cancer was the third most frequent solid neoplasm. Seventeen adenocarcinomas were found, of which 7 (41.1%) were associated with MALT, all of them in the same organ (3 in collision). Four (23.5%) cases were associated with DLBCL, 1 synchronous and in the same organ, 2 synchronous and in the cervical lymph nodes, and 1 in collision in a regional lymph node. Four (23.5%) cases were associated with MCL, 2 of them in collision, 1 synchronous and in pleura, and 1 synchronous and in a distant lymph node. One case was associated with CLL/SLL as a collision in the bone marrow, and 1 case was synchronously associated with anaplastic large cell lymphoma in the stomach.

SCC was found in 13 cases. Of these, 3 were associated with MALT in the same organ (1 in collision). Three cases were synchronously associated with NHL-NOS. One of these was synchronous and in the regional lymph node, 1 synchronous and in the mediastinum, and 1 synchronous and in the liver. Two cases were synchronously associated with DLBCL in the cervical and mesenteric lymph nodes.

Small cell carcinoma was found in 5 cases, of which 1 was synchronously associated with CHL in the inguinal lymph node. One was associated with synchronous DLBCL in the stomach. One was associated with synchronous NHL-NOS in the inguinal lymph node. One was associated with MCL in collision in the hilar lymph node, and 1 with CLL/SLL in collision in the mediastinum lymph node. Other solid neoplasms associated with lymphomas were found less frequently.

3.11. Kidney tumors

Twenty-two renal carcinomas were found. Sixteen cases were clear cell carcinomas, 4 of which were associated with DLBCL, 1 in collision in the kidney, 1 synchronous and in the adrenal gland, and 1 synchronous and in the submandibular gland. Three cases were synchronously associated with FL in the inguinal lymph node, submandibular node, and parotid gland. Three cases were synchronously associated with CLL/SLL in the perirenal lymph node, the retroperitoneal lymph node, and spleen, and less frequently in others.

Unspecified renal carcinoma was found in 5 cases, of which 2 cases were synchronously associated with CLL/SLL in the breast and spleen. One case was associated with synchronous CHL in the mediastinal lymph node. One was synchronously associated with DLBCL in the breast and 1 synchronously associated with unspecified TCL in the cervical lymph node.

Chromophobe renal cell carcinoma was found in 2 cases, of which 1 was synchronously associated with CLL/SLL in the perirenal lymph node and in the cervical lymph node. Other solid neoplasms associated with lymphomas were found less frequently.

3.12. Sarcomas

Eleven (3.4%) extranodal sarcomas were found. There were 7 Kaposi sarcomas, 2 of them associated with DLBCL in collision in the stomach, 3 with DLBCL in collision in the skin, 1 with DLBCL in collision in the liver, 1 in the liver synchronously associated with DLBCL in the spleen, and 1 in the skin associated with primary pleural effusion lymphoma. There were 3 histiocytic sarcomas, 1 of them in the peritoneum associated with FL that was synchronous and in the abdominal lymph node, 1 in the liver associated with FL in collision in the bone marrow, 1 associated with DLBCL in collision in the stomach, and finally, a myeloid sarcoma associated with DLBCL in collision in the liver.

3.13. T-cell lymphomas

In 13 (4.22%) cases were found TCLs associated with a solid neoplasm. Ten of these were synchronous and 3 in collision. There was one lung adenocarcinoma synchronously associated with anaplastic large cell lymphoma in the stomach. One colon adenocarcinoma was associated with a synchronous angioimmunoblastic TCL in a pericolic lymph node. An SCC of the skin was associated with a synchronous cutaneous TCL in the inguinal region. A papillary urothelial carcinoma of the bladder was in synchronous association with cutaneous TCL in the skin. A colon adenocarcinoma was associated with a synchronous natural killer TCL in the colon. An SCC of the scrotum skin was associated with a synchronous PTCL in the inguinal lymph node. An SCC of the larynx was associated with a synchronous TCL-NOS in the larynx. An unspecified renal carcinoma was associated with a synchronous TCL-NOS in the cervical lymph node. A neuroendocrine tumor of the appendix was associated with a synchronous TCL-NOS in the small intestine. A hepatocellular carcinoma was associated with a synchronous T-cell lymphoblastic lymphoma in a

cervical lymph node. An adenocarcinoma of the rectum was associated with a collision PTCL in the rectum. A stomach adenocarcinoma was associated with a collision TCL-NOS in the same organ and a SCC of lung carcinoma with a collision TCL-NOS in the same organ.

4. Discussion

The association of lymphomas with synchronous or collision solid neoplasms has been rarely described. Coppola et al^[58] reported one of the first cases in the literature of a colliding pleomorphic lymphoma and gastric adenocarcinoma in a 45-year-old patient with monoclonal macroglobulinemia and amyloidosis in 1969. In our review, we observed 308 cases of lymphomas associated with other solid neoplasms. The most frequent location for a lymphoma and a solid neoplasm was in the gastrointestinal tract, which is in line with the most prevalent location of carcinoma and also extranodal lymphomas.^[22,227] Thus, the most frequent carcinoma was adenocarcinoma in half of the cases, and the NHL lymphomas most frequently found to be synchronous were of DLBCL, followed by MALT lymphoma and FL. Meanwhile, the most frequent lymphomas in collision with another solid neoplasm were DLBCL followed by MALT and CLL/SLL lymphoma.

In the present review, we found the presence of the 2 tumors in the same organ (collision or synchronous) in the 48.7% of the cases. In the histology, the 2 tumors may be observed in 3 ways. The first is where carcinoma and lymphoma are in the same tumor, and the 2 types of tumor cells are mixed and grow crosswise (collision). Second, carcinoma and lymphoma are in the same tumor, but the 2 tumor types are not mixed and grow relatively independently (collision). Third, the 2 tumor components are in separate tumors (synchronous).^[131,263]

The pathophysiologic mechanism that explains the presence of a synchronous or colliding solid neoplasm and lymphoma is unknown. The questions to consider are whether the 2 neoplasms arise independently or have the same triggering factors or if there is a synergy between one neoplasm and another, that is, one neoplasm influences the appearance of another. Authors have proposed certain mechanisms that can explain the presence of the 2 tumors such as somatic mutations acquired during fetal life that migrate to different sites, and later, these cells become malignant by triggering factors (endogenous or exogenous),^[264,265] or also a common genetic defect as mismatch repair systems,^[266] or positive family history of malignancy.^[62]

Among the theories proposed about the synergy between one neoplasm and another. It has been posited that lymphomas may cause lymphatic channels to be obliterated, which would favor the growth of synchronous solid neoplasms.^[267] In addition, it has been proposed that the malignant lymphocytes lost the suppression capacity, and this increases the risk of developing other types of primary malignancies.^[35,90] Lymphocytes play a key role in the antitumor response by inducing apoptosis and suppression of tumor cell proliferation.^[268,269] The antitumor lymphocytes are usually those that are located in the organs or those that come from regional lymph nodes. In the regional lymph nodes, the antitumor immune response is due to the presentation of tumor antigens to T lymphocytes by antigen presenting cells.^[270-272] T-lymphocytes are sensitized to initiate an antitumor cell response.^[273] Interestingly, the lymphomas were near at the solid tumor in 65%^[208] of the all cases. Both neoplasms were found in the same organ in 150 cases, the lymphoma was in the regional lymph node in 58 cases. This finding could be due to the antitumor process that occurs in the tumoral and peritumoral tissue or in the regional nodes whether this is through the presentation of antitumor antigens that can trigger the expression of protooncogenes and tumor suppressors^[274] or an aberrant somatic hypermutation.^[275,276]

One of the most accepted theories about the synergy between one neoplasm and another is the secondary chronic inflammatory process that solid neoplasms generate can trigger lymphoma.^[35,90] Chronic inflammatory processes such as infections (*H. Pylori*, Epstein-Barr, HIV, and hepatitis C) or autoimmune diseases (chronic thyroiditis, Sjogren's syndrome, celiac disease, and rheumatoid arthritis) are known to be associated with the development of B-cell lymphoma, mainly MALT type lymphoma.^[277,278] The mechanisms for this lymphoid transformation are not clear. Mutations such as in the B cell receptor and NF- κ B or the exaggerated increase of proinflammatory cytokines that could explain this mechanism have been described.^[277,279,280]

One of the risk factors that could have a direct influence on the development of the 2 neoplasms through the onset of adenocarcinoma and lymphoma is *H. Pylori* infection.^[277] The presence of this infection has been associated with the oncogenesis mechanism of gastric adenocarcinoma and with the presence of MALT lymphoma. Potential carcinogenic mechanisms of *H. pylori* are associated with DNA damage, inadequate genetic repair and inflammatory reactions, and cellular incorporation of *H. pylori* DNA and toxic effects of bacterial products, such as vacuolating toxin A, cytotoxin-associated gene A, and ulcer-associated gene restriction endonuclease.^[244,281] The growth of lymphoma cells has been shown to be stimulated by contact with T cells, which, in turn, show specific responses to the *H. pylori* strain.^[282,283] In our review, *H. pylori* infection was present in 48.7% of the cases of gastric adenocarcinoma and MALT lymphoma.^[39,43,86,90,95,112,130,165,221,242]

A remarkable finding summarized in the present review was the cases with the presence of solid tumor metastasis in lymph nodes with lymphomas. A total of 29 cases were seen^[12–14,40,61,70–72,78,84,92,102,114,115,154,159,191,197,207,208,226,233] (Table 3). In 21 cases, the tumor metastases were observed in the regional lymph nodes, and these cases were mainly low-grade B-cell lymphoma. This incidental finding may be a challenge to the pathologist because the main finding seeking in the lymph node is solid tumor metastasis, and the presence of lymphoma may be unnoted.

The treatment reported in these patients was diverse and depends of the location and the type of tumors. The option treatment varied between surgical resection, radiotherapy, chemotherapy, or immunotherapy. However, sometimes, the treatment has become a difficulty to the clinicians because one treatment may cause toxicity for treating the other tumor.^[62]

Finally, the identification of indolent low-grade B-cell lymphoma, such as MALT lymphoma, CLL, or FL, during staging or surgical resection for carcinoma may represent a manifestation of a previously diagnosed lymphoma. In this regard, we identified that in only 6 cases, a previous history of lymphoma was described: 3 cases were synchronous SLL/CLL associated with breast carcinoma, melanoma, and Merkel cell carcinoma. The rest of the cases corresponded to MALT-type lymphoma, MCL, and NOS-NHL, all of them associated with adenocarcinoma. Thus, in most instances of synchronous/collision tumors, lymphoma is detected in an incidental fashion, which indicates that the carcinoma component is the one that is clinically more obvious and significant, whereas the low-grade B-cell lymphoma would manifest otherwise in a more indolent manner.

We would like to recognize the limitations of our study. First of all, in some articles, the final diagnosis was not made based on immunohistochemistry. Secondly, due to the diagnostic characteristics of synchronous or collision cases, it is challenging to provide solid evidence on the chronological course of events, that is, to define whether the primary occurrence was lymphoma or solid neoplasm. Thirdly, in some articles, the patient follow-up was insufficient to determine the progression of the disease. Fourthly, although we used the latest World Health Organization lymphoma classification criteria, some old reports may have had other outdated

classification system. Nevertheless, we homogenized all our data based in the most recent and appropriate system available. Last of all, systematic reviews of case reports outline a number of challenges for research into rare and heterogeneous diseases. Nevertheless, we consider them important tools for the initial data sources that go beyond anecdote to evidence for such conditions.

5. Conclusion

Our systematic review provides a comprehensive review about case reports with the presence of lymphomas with synchronous or collision solid neoplasms. The case reports included in this review had a significant diagnostic and treatment dilemmas. With our data, we cannot conclude if there is an association. The frequent co-occurrence of some type of B-cell lymphoma and adenocarcinoma in synchronous/collision tumors of the gastrointestinal tract points to common pathogenic mechanisms, particularly chronic inflammation, to explain the development of these types of tumors. In most cases, lymphoma identified in locoregional lymph nodes or distant of a carcinoma seems represent an incidental finding, highlighting the more obvious and clinically relevant manifestations of carcinoma compared to lymphoma. In addition, a synergy between carcinoma and lymphoma (involving inflammation and immunosuppression mechanisms) may favor tumor progression and dissemination. A better understating of the interactions of both lymphoma and carcinoma in the setting of synchronous/collision tumors may help to improve patient management and prognosis. From what is discussed in the article, we consider that it is important to do molecular studies in order to find out clues on underlying mechanisms leading to solid tumors and lymphoma development.

Author contributions

Conceptualization: R. Parra-Medina.

Validation: R. Parra-Medina.

Writing—original draft preparation: R. Parra-Medina, F. Rocha, J. P. Castañeda-González, P. Moreno-Lucero, and L. Velloza.

Writing—review and editing: R. Parra-Medina, F. Rocha, J. P. Castañeda-González, P. Moreno-Lucero, L. Velloza, and A. E. Romero-Rojas.

Project administration: R. Parra-Medina.

References

- [1] de Leval L, Jaffe ES. Lymphoma classification. *Cancer J*. 2020;26:176–85.
- [2] World health organization IA for R on cancer. Non-Hodgkin lymphoma. World Health Organization. 2020; 1–2. Available at: <https://gco.iarc.fr/today/data/factsheets/cancers/34-Non-hodgkin-lymphoma-fact-sheet.pdf> [access date 7 July, 2021].
- [3] World health organization IA for R on cancer. Hodgkin lymphoma. World Health Organization. 2020; 1–2. Available at: <https://gco.iarc.fr/today/data/factsheets/cancers/33-Hodgkin-lymphoma-fact-sheet.pdf> [access date 7 July, 2021].
- [4] Zucca E, Roggero E, Bertoni F, et al. Primary extranodal non-Hodgkin's lymphomas. Part 1: gastrointestinal, cutaneous and genitourinary lymphomas. *Ann Oncol Off J Eur Soc Med Oncol*. 1997;8:727–37.
- [5] Peña C, Russo M, Martínez V, et al. Extranodal lymphomas in the public health system in Chile: analysis of 1251 patients from the national adult cancer program. *Hematol Oncol*. 2019;37:47–53.
- [6] Luo JM, Cao FL, Meng C, et al. Clinicopathological and molecular characteristics of synchronous gastric adenocarcinoma and gastrointestinal stromal tumors. *Sci Rep*. 2017;7:12890.
- [7] Meng J, Pan H, Li X, et al. Diagnosis and treatment of synchronous lymphoma and digestive system carcinoma: report of four cases and literature review. *Front Oncol*. 2019;9:1367.
- [8] Liberati A, Altman DG, Tetzlaff J, et al. The PRISMA statement for reporting systematic reviews and meta-analyses of studies that evaluate health care interventions: explanation and elaboration. *PLoS Med*. 2009;6:e1000100.

- [9] Vyas M, Menon S, Desai SB. Collision tumor of kidney: a case of renal cell carcinoma with metastases of prostatic adenocarcinoma. *Indian J Med Paediatr Oncol.* 2013;34:21–3.
- [10] Ud Din N, Ahmad Z, Minhas K, et al. Synchronous and metachronous malignant epithelial and lymphoid tumors: a clinicopathologic study of 10 patients from a major tertiary care center in Pakistan. *Asian Pac J Cancer Prev.* 2017;18:2067–72.
- [11] Parra-Medina R, Moreno-Lucero P, Jimenez-Moreno J, et al. Neuroendocrine neoplasms of gastrointestinal tract and secondary primary synchronous tumors: a systematic review of case reports. casualty or causality? *PLoS One.* 2019;14:e0216647.
- [12] Acosta AM, Sonawane S, Sharif A, et al. Metastatic intestinal adenocarcinoma to a lymph node involved by follicular lymphoma: the importance of looking beyond the apparent. *Pathol Res Pract.* 2017;213:713–6.
- [13] Addada J, Anoop P, Swansbury JG, et al. Synchronous mantle cell lymphoma, chronic lymphocytic leukaemia and melanoma in a single lymph node. *Acta Haematol.* 2010;123:194–6.
- [14] Afify A, Das S, Mingyi C. Two smalls in one: coincident small cell carcinoma and small lymphocytic lymphoma in a lymph node diagnosed by fine-needle aspiration biopsy. *Cytojournal.* 2012;9:5.
- [15] Akosa AB, Clark DM, Desa L. Synchronous adenocarcinoma and primary malignant lymphoma of the stomach. *Postgrad Med J.* 1990;66:778–80.
- [16] Alakeel F, Lee E, Baird-Howell M, et al. Synchronous ductal carcinoma in situ and intravascular large B-cell lymphoma of the breast. *Appl Immunohistochem Mol Morphol.* 2019;27:e91–2.
- [17] Al-Amri A, Al-Quorain AA. Coexisting malignant lymphoma of the duodenum and adenocarcinoma of the colon. *Saudi Med J.* 2007;28:463–4.
- [18] Albers AE, Hummel M, Keilholz U, et al. Simultanes plattenepithelkarzinom und follikuläres Lymphom der Tonsille. *HNO.* 2010;58:1192–6.
- [19] Alonso-Ruano M, López-Bonet E, Huerta-Anaya MV, et al. Synchronous solid neuroendocrine breast carcinoma and abdominal lymphoma: a case report and review of the literature. *Oncol Lett.* 2013;5:459–62.
- [20] Alongi F, Aniko MD, Ferreri AJM, et al. consolidation radiotherapy for a rare case of extranodal mucosa-associated lymphoid tissue non-Hodgkin's lymphoma synchronous with prostate adenocarcinoma. *Tumori J.* 2010;96:498–502.
- [21] Anavekar NS, Rozen WM, Rowe K, et al. synchronous carcinoma and lymphoma of the breast. *Clin Breast Cancer.* 2008;8:281–4.
- [22] Akiba J, Nakane T, Arakawa F, et al. Collision of EBV-associated gastric carcinoma and primary gastric extranodal marginal zone lymphoma of mucosa-associated lymphoid tissue in the remnant stomach. *Pathol Int.* 2010;60:102–6.
- [23] Santos-Antunes J, Lopes S, Fonseca E, et al. Coexistence of Kaposi sarcoma and gastric diffuse large B-cell lymphoma in a HIV-infected patient. *Rev Esp Enferm Dig.* 2015;107:438–9.
- [24] Aqeel M, Uysal-Biggs N, Fenske TS, et al. One pulmonary lesion, 2 synchronous malignancies. *J Investig Med High Impact Case Reports.* 2018;6:232470961878593.
- [25] Arlen M, Freiman JJ, Ionescu M. Infiltrating ductal carcinoma of the breast associated with primary breast lymphoma. *J Cancer.* 2011;2:186–92.
- [26] Ashman D, Pantanowitz L. Kaposi sarcoma with coexisting intravascular lymphoma. *Int J Surg Pathol.* 2019;27:62–3.
- [27] Badrinath M, Tambe A, Ramadas P, et al. Melanoma and mantle cell lymphoma in a single collision tumor. *Baylor Univ Med Cent Proc.* 2019;32:584–6.
- [28] Barron BA, Localio SA. A statistical note on the association of colorectal cancer and lymphoma. *Am J Epidemiol.* 1976;104:517–22.
- [29] Beaumont Bell RD, Moriarty KJ. Synchronous colonic lymphoma and adenocarcinoma in a patient with Crohn's disease, treated with thiopurine therapy and a TNF α inhibitor: a challenge to Occam's razor. *BMJ Case Rep.* 2016;16:bcr2015212464.
- [30] Bernie JE, Albers L, Baird S, et al. Synchronous ipsilateral renal adenocarcinoma, transitional cell carcinoma of the renal pelvis and metastatic renal lymphoma. *J Urol.* 2000;164(3 Part 1):773–4.
- [31] Bernshteyn M, Smith-Hannah A, Dharmoon AS. Synchronous chronic lymphocytic leukemia/small lymphocytic lymphoma and metastatic squamous cell carcinoma of the cervix involving the coronary arteries leading to acute myocardial infarction. *Case Rep Oncol Med.* 2020;2020:1–4.
- [32] Berroa de la Rosa E, Casadiego Matarranz L, Aparicio Duque R, et al. Linfoma MALT y tumor carcinoide sincrónicos de íleon. *Gastroenterol Hepatol.* 2014;37:95–6.
- [33] Bhattacharya A, Saha R, Biswas J, et al. Collision tumors in the gastrointestinal tract: a rare case series. *Int Med Case Rep J.* 2012;73:73–7.
- [34] Braddy A, Mogal RJ, Maddox AJ, et al. Pulmonary maltoma synchronous with metastatic prostate adenocarcinoma: a diagnostic challenge. *Eur J case reports Intern Med.* 2020;7:001711.
- [35] Braham E, Zarrouk M, Mlika M, et al. Synchronous mantle cell lymphoma and pulmonary adenocarcinoma: a case report with literature review. *Clin Respir J.* 2017;11:430–2.
- [36] Branco C, Veiga C, Carneiro T, et al. Synchronous presentation of a gastric adenocarcinoma and gastric lymphoma? Case report of a rare association. *Rev Port Cir.* 2016;1:37.
- [37] Brochériou I, Nahon S, Coffin B, et al. Association of a low-grade MALT lymphoma and a slightly differentiated adenocarcinoma of the stomach. *Ann Pathol.* 1997;17:109–12.
- [38] Bu W, Pei H, Li L, et al. Synchronous adenocarcinoma and mucosal-associated lymphoid tissue lymphoma of the stomach. *Chin Med J (Engl).* 2014;127:1388–9.
- [39] Cammarota G, Larocca LM, D'Ugo D, et al. Synchronous gastric adenocarcinoma and MALT lymphoma in a patient with H. pylori infection. Could the two neoplasms share a common pathogenesis? *Hepatogastroenterology.* 2001;48:104–6.
- [40] Cantor AS, Moschos S, Jukic DM. A principal case of multiple lymphoid collision tumors involving both B-cell chronic lymphocytic leukemia and metastatic malignant melanoma. *Dermatol Online J.* 2010;16:6.
- [41] Carboni F, Diodoro MG, Valle M. Synchronous primary diffuse large B cell lymphoma and adenocarcinoma of the stomach: a clinical dilemma. *Indian J Surg Oncol.* 2020;11(Suppl 2):223–5.
- [42] Cavalcanti E, Armentano R, Lolli I. Crohn's disease following rituximab treatment for follicular lymphoma in a patient with synchronous gastric signet ring cells carcinoma: a case report and literature review. *Cancer Res Treat.* 2020;2:1291–1295.
- [43] Chan AO-O, Chu K-M, Yuen S-T, et al. Synchronous gastric adenocarcinoma and mucosa-associated lymphoid tissue lymphoma in association with Helicobacter pylori infection: comparing reported cases between the East and West. *Am J Gastroenterol.* 2001;96:1922–4.
- [44] Chanel S, Burke L, Fiche M, Molina T, Lerchais JP, Icard P, et al. Synchronous pulmonary adenocarcinoma and extranodal marginal zone/low-grade B-cell lymphoma of MALT type. *Hum Pathol.* 2001;32:129–32.
- [45] Chang H, Chuang WY, Shih LY, et al. Collision in the colon: concurrent adenocarcinoma and diffuse large B-cell lymphoma in the same tumour. *Acta Clin Belg.* 2011;66:302–4.
- [46] Chang M-Y, Chen Y-M, Chen Y-C, et al. Concurrent renal cell carcinoma and central nervous system lymphoma in a patient with autosomal dominant polycystic kidney disease. *Med Princ Pract.* 2009;18:486–9.
- [47] Chawla J, Selhi PK, Narang V, et al. Synchronous high-grade bladder carcinoma associated with chronic lymphocytic leukemia: A rare entity in Indian literature. *J Cancer Res Ther.* 2020;16:180–2.
- [48] Chen D-W. Laparoscopic resection of synchronous gastric cancer and primary small intestinal lymphoma: a case report. *World J Gastroenterol.* 2014;20:6353.
- [49] Cheung KJ, Tam W, Chuang E, et al. Concurrent invasive ductal carcinoma and chronic lymphocytic leukemia manifesting as a collision tumor in breast. *Breast J.* 2007;13:413–7.
- [50] Choi KW, Joo M, Kim HS, et al. Synchronous triple occurrence of MALT lymphoma, schwannoma, and adenocarcinoma of the stomach. *World J Gastroenterol.* 2017;23:4127.
- [51] Chong VH, Idros A, Telisinghe PU. Triple synchronous gastrointestinal malignancies: a rare occurrence. *Singapore Med J.* 2010;51:e176–7.
- [52] Chong Y, Shin JJ, Cho M-Y, et al. Synchronous primary gastric mantle cell lymphoma and early gastric carcinoma: a case report. *Pathol Res Pract.* 2008;204:407–11.
- [53] Chung S-D, Huang K-H, Lai Y-H, et al. Synchronous advanced scrotal verrucous carcinoma with peripheral T-CELL Lymphoma. *Urology.* 2007;69:184.e5-7.
- [54] Ciobanu D, Meşină C, Streba L, et al. The role of immunohistochemistry in diagnosing a synchronous colon tumor. *Rom J Morphol Embryol.* 2014;55(3 Suppl):1209–13.
- [55] Comez G, Pehlivan Y, Kalender ME, et al. Synchronous Hodgkin's disease and gastric adenocarcinoma. *Oncology.* 2007;73:422–5.
- [56] Congyang L, Xinggui W, Hao L, Weihua H. Synchronous histiocytic sarcoma and diffuse large B cell lymphoma involving the stomach: a case report and review of the literature. *Int J Hematol.* 2011;93:247–52.
- [57] Contreras-Ibáñez JA, Díaz-Gómez L, Muriel-Cueto P. [Renal synchronous carcinoma of clear cells with non-Hodgkin lymphoma of phenotype b of type MALT]. *Actas Urol Esp.* 2010;34:818–9.

- [58] Coppola A, Yermakov V, Caggiano V. Pleomorphic lymphoma and gastric adenocarcinoma (collision neoplasm) associated with monoclonal macroglobulinemia and amyloidosis: A case report. *Cancer*. 1969;23:576–85.
- [59] Kopsidas K, Ford R, Ahmed I, et al. Concomitant orbital tumours: small lymphocytic lymphoma involving the lacrimal gland of a patient with clinical diagnoses of Muir-Torre syndrome and extensive sebaceous gland carcinoma of the ipsilateral eyelid. *Ocul Oncol Pathol*. 2020;6:15–9.
- [60] Cox J, Lunt L, Webb L. Synchronous presentation of breast carcinoma and lymphoma in the axillary nodes. *Breast*. 2006;15:246–52.
- [61] Cuff KE, Detrick AJ, Chern B. Synchronous breast cancer and lymphoma: a case series and a review of the literature. *J Clin Pathol*. 2010;63:555–7.
- [62] Cui Y, Liu T, Zhou Y, et al. Five cases report of solid tumor synchronously with hematologic malignancy. *Cancer Res Treat*. 2012;44:63–8.
- [63] Cupp JS, Wrede JE, Cherry AM, et al. Chromosomal aberrations in a case of synchronous extranodal marginal zone B-cell lymphoma of mucosa-associated lymphoid tissue type and bronchogenic adenocarcinoma. *Appl Immunohistochem Mol Morphol*. 2008;16:296–300.
- [64] Shah DS, Homer NA, Epstein A, et al. Simultaneous presentation of orbital mantle cell lymphoma and endocrine mucin-producing sweat gland carcinoma. *Orbit*. 2021;1:5.
- [65] Dasanu CA, Shimanovsky A, Rotundo EK, et al. Collision tumors: pancreatic adenocarcinoma and mantle cell lymphoma. *JOP*. 2013;14:458–62.
- [66] Demirci U, Büyükkberber S, Yılmaz G, et al. Coexistence Hodgkin's lymphoma and colonic adenocarcinoma: a case report. *Med Oncol*. 2010;27:62–4.
- [67] Pattanayak L, Samantaray S, Devi P. Synchronous adenocarcinoma and mucosa-associated lymphoid tissue lymphoma of the colon. *Saudi J Gastroenterol*. 2011;17:69.
- [68] Dirilenoglu F, Yukselen OO, Mocan G. Spindle cell melanoma coexisting with chronic lymphocytic leukemia/small lymphocytic lymphoma: a rare collision tumor in multiple sites. *J Cutan Pathol*. 2020;47:1215–9.
- [69] Dabrowski D, Silva RF, Constantinescu M, et al. Synchronous occurrence of splenic pleomorphic mantle cell lymphoma and esophageal adenocarcinoma with overexpression of BCL1 protein. *Case Rep Oncol Med*. 2020;2020:8888829.
- [70] dos Santos H, Benevenuto B, Filho E, et al. Synchronous metastatic cutaneous squamous cell carcinoma and chronic lymphocytic leukaemia/small lymphocytic lymphoma in a cervical lymph node: case report of an unusual event. *J Clin Exp Dent*. 2015;7:660–4.
- [71] Dueber JC, Coffin CM. Collision of chronic lymphocytic leukemia/small lymphocytic lymphoma and melanoma. *Blood*. 2013;121:4819.
- [72] El Demellawy D, Ross C, Sur M, et al. Synchronously diagnosed lymph nodal collision tumor of malignant melanoma and chronic lymphocytic leukemia/small lymphocytic lymphoma: case report. *Diagn Pathol*. 2007;2:34.
- [73] Elsaid MY, Gill KG, Gosain A, et al. Synchronous presentation of renal cell carcinoma and Hodgkin lymphoma in an adolescent. *J Pediatr Hematol Oncol*. 2017;39:e399–402.
- [74] Eshra A, Al-Hendal A, Al Enezi M, et al. One patient, two lymphomas, three primaries. *Gulf J Oncolog*. 2010;8:39–43.
- [75] Fekih M, Sassi A, Matri S, et al. Synchronous tumor of the stomach: association of mucosa-associated lymphoid tissue lymphoma and adenocarcinoma. About two cases. *Tunis Med*. 2008;86:398–9.
- [76] Feng X, He Y, Yu B, et al. Synchronous squamous cell carcinoma of lung and B-cell lymphoma of peritumoural lymph nodes: report of a case. *Zhonghua Bing Li Xue Za Xhi*. 2018;47:215–6.
- [77] Fernandez-Pol S, Bangs CD, Cherry A, et al. Two cases of histiocytic sarcoma with BCL2 translocations and occult or subsequent follicular lymphoma. *Hum Pathol*. 2016;55:39–43.
- [78] Fink LM, Bolan CD, Krishnan J, et al. Synchronous diffuse well-differentiated lymphocytic lymphoma and gastric adenocarcinoma presenting as splenomegaly and iron deficiency anemia. *Am J Gastroenterol*. 1990;85:1635–6.
- [79] Fonseca D, Musthyala B, Ahmed F, et al. A tale of synchronous lung carcinoma and diffuse large B-cell lymphoma of ileum: a rare combination. *Lung India*. 2015;32:398.
- [80] Fujii M, Shirai T, Asada K, et al. Synchronous diffuse large B-cell lymphoma and squamous cell lung carcinoma. *Respirol Case Reports*. 2014;2:33–5.
- [81] Fukaura A, Tazawa H, Fujii H, et al. Synchronous cancer of squamous cell carcinoma of the lung and lymphocytic leukemia (B-cell type): a case report. *Jpn J Clin Oncol*. 1992;22:210–5.
- [82] Gajendra S, Sharma R, Sahoo MK. Triple cancer: chronic lymphocytic leukemia with bladder and prostate carcinoma. *Malays J Pathol*. 2015;37:159–63.
- [83] Ganguly S, Cunningham MT. A case of synchronous lymphoplasmacytic lymphoma and rectal carcinoid. *Am J Clin Oncol*. 2006;29:104–5.
- [84] García J, Campos J, Abdulkader I, et al. Tumor de colisión: metástasis de adenocarcinoma y linfoma folicular en un mismo ganglio linfático. *Rev Med Chil*. 2009;137:83–7.
- [85] Gebauer N, Merz H, Ottmann KW, et al. Lymphoepithelioma-like carcinoma and simultaneous marginal zone lymphoma of the skin. *Am J Dermatopathol*. 2014;36:e26–9.
- [86] George SA, Junaid TA. Gastric marginal zone lymphoma of mucosa-associated lymphoid tissue and signet ring cell carcinoma, synchronous collision tumour of the stomach: a case report. *Med Princ Pract*. 2014;23:377–9.
- [87] Graziano F, Cellerino R, Menestrina F, et al. Synchronous primary hepatic lymphoma and epidermoid lung carcinoma treated with chemotherapy and surgery. *Am J Clin Oncol*. 1995;18:194–8.
- [88] Guo R, Chang L, Liu Z, et al. Canonical nuclear factor κ b pathway links tumorigenesis of synchronous mantle-cell lymphoma, clear-cell renal-cell carcinoma, and GI stromal tumor. *J Clin Oncol*. 2011;29:e257–61.
- [89] Hadjileontis CG, Kostopoulos IS, Kaloutsis VD, et al. An extremely rare case of synchronous occurrence in the larynx of intravascular lymphoma and in situ squamous cell carcinoma. *Leuk Lymphoma*. 2003;44:1053–7.
- [90] Hardman WJ, Gal AA, Pascal RR. Gastric adenocarcinoma and low-grade B-cell lymphoma of mucosa-associated lymphoid tissue. *South Med J*. 1997;90:426–30.
- [91] Hatzibougias D, Bobos M, Karayannopoulou G, et al. A rare tumoral combination, synchronous lung adenocarcinoma and mantle cell lymphoma of the pleura. *World J Surg Oncol*. 2008;6:137.
- [92] Haynes HR, Rose DSC. Synchronous small lymphocytic lymphoma and metastatic breast carcinoma in axillary lymph nodes: preservation of follicular architecture only in the portions of affected lymph nodes involved by metastatic carcinoma. *Breast J*. 2020;26:245–6.
- [93] Heidemann LN, Johansen J, Larsen SR, et al. Four synchronous cancers in a patient with tongue pain as the only symptom. *BMJ Case Rep*. 2016;2016:bcr2015214047.
- [94] Heitzman J, Stachura J, Galazka K, et al. Synchronous carcinoma and primary MALT-lymphoma of the stomach. A report of two cases. *Pol J Pathol*. 1997;48:57–62.
- [95] Herreros-Villanueva M, Bujanda L, Gil I, et al. Triple synchronous gastric tumors: a rare combination diffuse adenocarcinoma, B-cell MALT lymphoma and large cell neuroendocrine carcinoma. *Gastroenterol Hepatol*. 2017;40:675–7.
- [96] Ho CWG, Mantoo S, Lim CH, et al. Synchronous invasive ductal carcinoma and intravascular large B-cell lymphoma of the breast: a case report and review of the literature. *World J Surg Oncol*. 2014;12:88.
- [97] Hrudka J, Eis V, Lisý P, et al. Synchronous colorectal carcinoma and non-Hodgkin lymphoma - two case reports. *Rozhl Chir*. 2016;95:369–72.
- [98] Hu X, Hu Y, Fu H, et al. Diffuse large B-cell lymphoma with concurrent gastric adenocarcinoma: case report and literature review. *J Int Med Res*. 2011;39:2051–8.
- [99] Ibrahim U, Saqib A, Pant M, et al. Synchronous pulmonary neoplasms: a chance occurrence or is there more than meets the eye? *Cureus*. 2018;10:e2162.
- [100] Ichihara E, Tabata M, Takigawa N, et al. Synchronous pulmonary MALT lymphoma and pulmonary adenocarcinoma after metachronous gastric MALT lymphoma and gastric adenocarcinoma. *J Thorac Oncol*. 2008;3:1362–3.
- [101] Ichikawa K, Sugimoto K, Sato E, et al. 18F-Fluorodeoxyglucose positron emission tomography/computed tomography revealed the presence of simultaneous colon cancer in mucosa-associated lymphoid tissue lymphoma. *Geriatr Gerontol Int*. 2011;11:537–8.
- [102] Ikemura S, Moriyama M, Matsumoto K, et al. Lymph node collision tumor consisting of metastatic pulmonary adenocarcinoma and diffuse large B-cell lymphoma. *Intern Med*. 2018;57:1135–9.
- [103] Inoue K, Fujiwara Y, Kogata S. A case of collision tumor of gastric malignant lymphoma and gastric cancer. *Gan To Kagaku Ryoho*. 2016;43:1869–71.
- [104] Isaka T, Nakamura T, Tajika M, et al. API2-MALT1 chimeric transcript-positive gastroduodenal MALT lymphoma with subsequent development of adenocarcinoma as a collision tumour over a clinical course of 7 years. *Histopathology*. 2007;51:119–22.
- [105] Iwamuro M, Imagawa A, Kobayashi N, et al. Synchronous adenocarcinoma and follicular lymphoma of the stomach. *Intern Med*. 2013;52:907–12.

- [106] Jafarian N, Kuppler K, Rosa M, et al. Chronic lymphocytic leukemia and invasive ductal carcinoma presenting as a collision breast tumor. *Clin Breast Cancer*. 2015;15:e209–12.
- [107] Jamal E, El-Ashwah S, Ebrahim MA, et al. Case report; meta-synchronous triple malignancy in primary diagnosed CML patient. *Am J Blood Res*. 2020;10:22–5.
- [108] Joo Y-H, Jung C-K, Sun D-I, et al. Synchronous laryngeal squamous cell carcinoma and Hodgkin lymphoma of the head and neck region. *Auris Nasus Larynx*. 2009;36:501–4.
- [109] Li J-J, Chen B-C, Dong J, et al. Synchronous colonic mucosa-associated lymphoid tissue lymphoma found after surgery for adenocarcinoma: a case report and review of literature. *World J Clin Cases*. 2020;8:6456–64.
- [110] Juettner FM, Fellbaum C, Popper H, et al. Synchronous pulmonary carcinoid tumour and non-Hodgkin's lymphoma: report of two cases. *Thorax*. 1989;44:516–8.
- [111] Jung CY, Kwon KY. A case of synchronous lung adenocarcinoma and extranodal marginal zone B-cell lymphoma of mucosa-associated lymphoid tissue (MALT) type. *Tuberc Respir Dis (Seoul)*. 2012;73:61.
- [112] Kaffes A, Hughes L, Hollinshead J, et al. Synchronous primary adenocarcinoma, mucosa-associated lymphoid tissue lymphoma and a stromal tumor in a *Helicobacter pylori*-infected stomach. *J Gastroenterol Hepatol*. 2002;17:1033–6.
- [113] Kai K, Ryu Y, Kamochi K, et al. Synchronous mantle cell lymphoma and lung adenocarcinoma presenting in a pleural effusion: a rare tumour combination and a potential pitfall of cytodiagnosis. *Cytopathology*. 2018;29:400–2.
- [114] Kakarala K, Sadow PM, Emerick KS. Cervical lymph node collision tumor consisting of metastatic squamous cell carcinoma and B-cell lymphoma. *Laryngoscope*. 2010;120:S156–S156.
- [115] Kampalath B, Abed N, Chitambar CR, et al. Mantle cell lymphoma in lymph nodes with metastatic small cell carcinoma of lung: a diagnostic and treatment dilemma. *Leuk Lymphoma*. 2004;45:409–14.
- [116] Kawashima O, Sakata S, Kamiyoshihara M, et al. Primary pulmonary collision tumor including squamous cell carcinoma and T-cell lymphoma. *Lung Cancer*. 1999;23:67–70.
- [117] Khadilkar U, Prasad K, Gupta S, et al. Synchronous RCC with NHL: a case report. *Kathmandu Univ Med J (KUMJ)*. 2007;5:417–20.
- [118] Kidd LR, Evans MD, Williams NW, et al. Synchronous diagnosis of colorectal malignancy and lymphoma. *Color Dis*. 2011;13:1107–9.
- [119] Kim Y Il, Koo MY. Synchronous adenocarcinoma and mantle cell lymphoma of the stomach. *Yonsei Med J*. 2007;48:1061.
- [120] Kocher NJ, Leung S, Sarwani NE, et al. Synchronous primary renal lymphoma and renal cell carcinoma: collision tumors in the same kidney. *J Endourol case reports*. 2017;3:87–9.
- [121] Koletsis T, Petrakis G, Karayannopoulou G, et al. Synchronous presence of nasopharyngeal carcinoma and marginal zone (MALT-Type) B-cell lymphoma in the pharynx. *Patholog Res Int*. 2011;2011:1–5.
- [122] Coupland SE, Dodson A, Liu H, et al. Intraocular collision tumour: case report and literature review. *Graefes Arch Clin Exp Ophthalmol*. 2013;251:1383–8.
- [123] Kostopoulos IS, Barbani SB, Kaloutsis VD, et al. Synchronous occurrence of multiple malignant neoplasms in the uterus (adenocarcinoma of the endometrium, large B-cell lymphoma of the cervix). *Pathol Res Pract*. 2000;196:573–5.
- [124] Kus T, Aktas G, Kalender ME, et al. Collision tumor consisting of primary follicular lymphoma and adenocarcinoma in the cecum: a case report and literature review. *Oncol Lett*. 2016;11:2801–5.
- [125] Kycler W, Teresiak M, Śliwiński A. An unusual case of synchronous lymphoma and adenocarcinoma occurring as a collision tumour in the stomach – a case report. *Reports Pract Oncol Radiother*. 2008;13:96–100.
- [126] Laudenschlager MD, Tyler KL, Geis MC, et al. A rare case of synchronous invasive ductal carcinoma of the breast and follicular lymphoma. *S D Med*. 2010;63:123–5.
- [127] Martinez L, Torregrosa J, Estela JJ, et al. Simultaneous B-cell lymphoma and Merkel cell carcinoma: coincidence or connection? *J Am Acad Dermatol*. 2015;72:AB192.
- [128] Lee DY, Hong SW, Chang YG, et al. Synchronous T-cell lymphoma in patient with colon cancer: a case report. *J Korean Surg Soc*. 2012;83:60.
- [129] Lee HB, Park JC, Lee YS, et al. Unexpected synchronous follicular lymphoma of paraaortic and pelvic lymph nodes in a patient with endometrial carcinoma: a case report. *Eur J Gynaecol Oncol*. 2011;32:334–5.
- [130] Lee S-Y, Kim JJ, Lee JH, et al. Synchronous adenocarcinoma and mucosa-associated lymphoid tissue (MALT) lymphoma in a single stomach. *Jpn J Clin Oncol*. 2005;35:591–4.
- [131] Bao L, Feng X, Wang T, et al. Collision tumor of carcinoma and lymphoma in the cecum: case report and review of literature. *Int J Clin Exp Pathol*. 2020;13:2907–15.
- [132] Li J, Zhou C, Liu W, et al. Synchronous diffuse large B-cell lymphoma of the stomach and small cell lung carcinoma. *Medicine (Baltimore)*. 2017;96:e8873.
- [133] Li Z, Yang J-J, Wu M. Collision tumor of primary Merkel cell carcinoma and chronic lymphocytic leukemia/small lymphocytic lymphoma, diagnosed on ultrasound-guided fine-needle aspiration biopsy: a unique case report and review of literature. *Diagn Cytopathol*. 2015;43:66–71.
- [134] Lian J, Li J, Ma HX, et al. Synchronous invasive ductal carcinoma and primary lymphoma of breast: report of a case. *Zhonghua bing li xue za zhi*. 2019;48:899–901.
- [135] Liao M-T, Cheng M-F, Chang W-C, et al. Duodenal mantle cell lymphoma in a patient with advanced sigmoid adenocarcinoma. *South Med J*. 2009;102:429–31.
- [136] Lin H-H, Jiang J-K, Lin J-K. Collision tumor of low-grade B-cell lymphoma and adenocarcinoma with tuberculosis in the colon: a case report and literature review. *World J Surg Oncol*. 2014;12:147.
- [137] Lind SE. Malignant lymphoma presenting as Kaposi's sarcoma in a homosexual man with the acquired immunodeficiency syndrome. *Ann Intern Med*. 1985;102:338.
- [138] Lindboe CF, Holm SE, Lie AK. Synchronous occurrence of carcinoid tumour of the appendix and T-cell lymphoma of the ileum. *APMIS*. 1999;107:523–8.
- [139] de Melo Lira MM, Moreira LR, Ruano T, et al. Concomitant detection of hematological neoplasm and carcinoma: report on seven cases. *Sao Paulo Med J*. 2008;126:245–7.
- [140] Liu L, Zhao H, Sheng L, et al. Collision of lymphoepithelioma-like carcinoma with diffuse large B-cell lymphoma of the stomach: a case report. *Anticancer Res*. 2017;37:4569–73.
- [141] Liu S, Zhao Y, Li M, et al. Simultaneous Hodgkin lymphoma and BRAF V600E -positive papillary thyroid carcinoma. *Medicine (Baltimore)*. 2019;98:e14180.
- [142] Liu W, Zhu H, Zhou X. Synchronous bilateral non-Hodgkin's diffuse large B-cell lymphoma of the breast and left breast invasive ductal carcinoma: a case report and review of literature. *Int J Clin Exp Pathol*. 2014;7:7042–8.
- [143] Lorber J, Zalom M. A Lymphoma almost overlooked. *Cureus*. 2018;10:e2110.
- [144] Lovell MO, Valente PT. Unique collision of Hodgkin lymphoma and adenocarcinoma in the uterine cervix: synchronous malignant neoplasms of the cervix. *J Low Genit Tract Dis*. 2003;7:307–10.
- [145] Ma TM, Kang H, Rowe SP, et al. Response to R-CHOP in HPV-related squamous cell carcinoma of base of tongue: a case report. *Cancers head neck*. 2018;3:2.
- [146] Makis W, Hickeys M, Novales-Diaz J-A. Unsuspected synchronous thyroid carcinoma revealed on a post-therapy F-18 FDG PET/CT, in a patient with follicular lymphoma. *Clin Nucl Med*. 2010;35:879–81.
- [147] Manabe T, Nishihara K, Kurokawa Y, et al. A collision tumor composed of adenocarcinoma and malignant lymphoma in the remnant stomach after pancreatoduodenectomy: report of a case. *Surg Today*. 2001;31:450–3.
- [148] Manier J. Collision tumor of the stomach. *Gastroenterol*. 1974;67:1011–5.
- [149] Mannweiler S, Dinges HP, Beham-Schmid C, et al. Colliding/concomitant tumors of the intestine: Report of 3 cases. *Pathol Oncol Res*. 2003;9:188–92.
- [150] Basso MP, Christiano AB, Guerrer LV, et al. Non-Hodgkin lymphoma as a cause of acute intestinal obstruction/perforation in patients with adenocarcinoma of the sigmoidcolon: a case report. *J Coloproctol (Rio Janeiro)*. 2011;31:378–81.
- [151] Márquez Moreno AJ, Mañas Uxó J, Amores Ramírez F, et al. Synchronous chromophobe renal carcinoma and centrocytic lymphoma. *Arch Esp Urol*. 2003;56:415–7.
- [152] Marra A, Martino G, Scarpelli N, et al. Collision diffuse large B cell lymphoma and myeloid sarcoma in the liver. *Ann Hematol*. 2020;100:2649–51.
- [153] Masha L, Zinchuk A, Boosalis V. Synchronous pulmonary malignancies: atypical presentation of mantle cell lymphoma masking a lung malignancy. *Rare Tumors*. 2015;7:5929.
- [154] McElroy C, Velilla R, Chaudhary H, et al. Fine-needle aspiration diagnosis of squamous cell carcinoma in a lymph node involved with small lymphocytic lymphoma: case report and review of the literature. *Diagn Cytopathol*. 2009;37:48–50.
- [155] Medrado JSF, Dittrich MR, Sousa JM, et al. Case report of a meta-synchronous multiple tumor: mantle cell lymphoma in the orbital region associated with epithelial malignancies at other sites. *Arq Bras Oftalmol*. 2014;77:54–6.

- [156] Michalinos A, Vassilakopoulos T, Levidou G, et al. Multifocal bilateral breast cancer and breast follicular lymphoma: a simple coincidence? *J Breast Cancer*. 2015;18:296.
- [157] Miles EF, Jacimore LL. Synchronous bilateral breast carcinoma and axillary non-Hodgkin lymphoma: a case report and review of the literature. *Case Rep Oncol Med*. 2012;2012:685919.
- [158] Millet A, Singh S, Gittens-Backus G, et al. An unusual case of invasive Kaposi's sarcoma with primary effusion lymphoma in an HIV positive patient: case report and literature review. *Case Rep Oncol Med*. 2015;2015:789616.
- [159] Minca EC, Popat SR, Chadha MK, et al. Small lymphocytic lymphoma obscuring microscopic tonsillar squamous cell carcinoma: an unknown occurrence with a known primary. *Head Neck Pathol*. 2012;6:125–9.
- [160] Mirkheshti N, Mohebtash M. A rare case of bilateral breast lobular carcinoma coexisting with primary breast follicular lymphoma. *J Community Hosp Intern Med Perspect*. 2019;9:155–8.
- [161] Melo GM, de Sguilar DA, Petiti CMF, et al. Concomitant thyroid Malt lymphoma and papillary thyroid carcinoma. *Arq Bras Endocrinol Metabol*. 2010;54:425–8.
- [162] Moriya Y, Koyama Y, Minato K, et al. Coexisting malignant lymphoma and advanced adenocarcinoma of the colon—a case report. *Gan No Rinsho*. 1985;31:894–9.
- [163] Mukhtar RA, Holland M, Sieber DA, et al. Synchronous breast implant-associated anaplastic large cell lymphoma and invasive carcinoma: genomic profiling and management implications. *Plast Reconstr Surg Glob Open*. 2019;7:e2188.
- [164] Müller D, Tomasović-Lončarić C, Galeić-Iljubašević D, et al. Renal cell carcinoma with concurrent urothelial carcinoma of urinary bladder and non-Hodgkin lymphoma. *Coll Antropol*. 2012;36:1049–52.
- [165] Murakami T, Shoji T, Suzuki K, et al. Simultaneous occurrence of early gastric carcinoma and mucosa-associated lymphoid tissue lymphoma of the omentum. *Case Rep Gastroenterol*. 2014;8:101–6.
- [166] Nakagawa K, Sakaki S, Fujita H, et al. A case of primary intracranial malignant lymphoma associated with gastric carcinoma. *Gan No Rinsho*. 1987;33:937–42.
- [167] Namikawa T, Kobayashi M, Hanazaki K. Synchronous superficial spreading lesions of the stomach. *Gut*. 2014;63:1194.
- [168] Nishikawa A, Kasai H, Koyama Y, et al. Synchronous ipsilateral carcinoma of the accessory mammary gland and primary lymphoma of the breast with subsequent rectal carcinoma: report of a case. *World J Surg Oncol*. 2014;12:286.
- [169] Nishino N, Konno H, Baba S, et al. Synchronous lymphoma and adenocarcinoma occurring as a collision tumor in the stomach: report of a case. *Surg Today*. 1996;26:508–12.
- [170] Noda T, Akashi H, Matsueda S, et al. Collision of malignant lymphoma and multiple early adenocarcinomas of the stomach. *Arch Pathol Lab Med*. 1989;113:419–22.
- [171] Nozawa K, Kaneko H, Itoh T, et al. Synchronous malignant B-cell lymphoma and gastric tubular adenocarcinoma associated with paraneoplastic cutaneous vasculitis: hypereosinophilic syndrome with mixed cryoglobulinemia is an important sign of paraneoplastic syndrome. *Rare Tumors*. 2009;1:128–31.
- [172] Ohno Z, Tamaki H, Ohsuga T, et al. Primary lung cancer complicated by malignant lymphoma in two cases of Epstein-Barr virus infection. *Case Rep Oncol*. 2012;5:367–72.
- [173] Oikonomou A, Astrinakis E, Kotsianidis I, et al. Synchronous BALT lymphoma and squamous cell carcinoma of the lung: coincidence or linkage? *Case Rep Oncol Med*. 2013;2013:1–3.
- [174] Okumura K, Kato K, Furuhashi K, et al. A collision cancer between urothelial carcinoma and malignant lymphoma of the urinary bladder: a case report. *Hinyokika Kyo*. 2007;53:649–51.
- [175] Osman MM, Altinyay ME, Abdelmalik AG, et al. FDG PET/CT incidental diagnosis of a synchronous bladder cancer as a fourth malignancy in a patient with head and neck cancer. *Clin Nucl Med*. 2011;36:496–7.
- [176] Padmanabhan V, Trainer TD. Synchronous adenocarcinoma and mantle cell lymphoma of the colon. *Arch Pathol Lab Med*. 2003;127:E64–6.
- [177] Gwiti P, Jenkins M, Sutak J, et al. Two cases of rare HHV8-driven intravascular lymphoma with synchronous Kaposi sarcoma, both diagnosed at autopsy in renal transplant recipients. *Autops Case Reports*. 2020;10:e2020206.
- [178] Pamukçuoğlu M, Budakoğlu B, Han O, et al. An extraordinary case in whom gastrointestinal stromal tumor and low-grade malignant lymphoma are seen together in the stomach. *Med Oncol*. 2007;24:351–3.
- [179] Athanasopoulos PG, Arkadopoulos N, Stafyla V, et al. A rare combination of an endocrine tumour of the common bile duct and a follicular lymphoma of the ampulla of Vater: a case report and review of the literature. *World J Surg Oncol*. 2011;9:4.
- [180] Panayiotides IG, Foukas PG, Meristoudis C, et al. Simultaneous occurrence of Warthin-like papillary carcinoma and lymphoma of the mucosa associated lymphoid tissue in Hashimoto thyroiditis. *J Clin Pathol*. 2010;63:662–3.
- [181] Papaják T, Mysliveček M, Šedová Z, et al. Synchronous second primary neoplasms detected by initial staging F-18 FDG PET/CT examination in patients with non-Hodgkin lymphoma. *Clin Nucl Med*. 2011;36:509–12.
- [182] Parakh R, Cheng L, Tretiakova M. PAX8-positive B-cell lymphoma in adrenal gland masquerading as metastatic renal cell carcinoma. *Int J Surg Pathol*. 2018;26:721–4.
- [183] Park JH, Jang JY, Cho YD, et al. A case of synchronous early gastric cancer and diffuse large b cell lymphoma treated with endoscopic submucosal dissection and chemotherapy. *Korean J Gastroenterol*. 2012;59:377.
- [184] Park SH, Rha SY, Shim DK, et al. An unusual case of gastric carcinoma with synchronous non-Hodgkin's lymphoma. *Yonsei Med J*. 1998;39:463.
- [185] Parra-Medina R, López Correa P, Castro Quiroga P, et al. Synchronous adenocarcinoma and lymphoma of the gallbladder: a case report. *J Gastrointest Cancer*. 2016;47:474–7.
- [186] Parsons AC, Sheehan DJ, Sangüeza OP. Synchronous verrucous carcinoma and cutaneous T-cell lymphoma. *J Am Acad Dermatol*. 2008;58:S124–5.
- [187] Pascua J, Robaina G, Di Tullio F, et al. Synchronous pulmonary adenocarcinoma and primary lymphoma of lung mucosa-associated lymphoid tissue. *Medicina (B Aires)*. 2019;79:208–11.
- [188] Péricart S, Waysse C, Siegfried A, et al. Subsequent development of histiocytic sarcoma and follicular lymphoma: cytogenetics and next-generation sequencing analyses provide evidence for transdifferentiation of early common lymphoid precursor—a case report and review of literature. *Virchows Arch*. 2020;476:609–14.
- [189] Petković I, Stojnev S, Krstić M, et al. Synchronous mantle cell lymphoma and prostate adenocarcinoma—is it just a coincidence? *Vojnosanit Pregl*. 2016;73:1072–5.
- [190] Piccinini L, Luppi G, Zoboli A, et al. Occasional diagnosis of synchronous renal cell carcinoma during staging of other primary tumors. *Tumori J*. 1996;82:488–90.
- [191] Popivanov GI, Bochev P, Hristoskova R, et al. Synchronous papillary thyroid cancer and non-Hodgkin lymphoma. *Medicine (Baltimore)*. 2018;97:e9831.
- [192] Quilon JM, Gaskin TA, Ludwig AS, et al. Collision tumor: invasive ductal carcinoma in association with mucosa-associated lymphoid tissue (malt) lymphoma in the same breast. *South Med J*. 2006;99:164–7.
- [193] Radman I, Sucić M, Serventi-Seiwerth R, et al. Patient with immunoproliferative disease and lung carcinoma: a case report. *Diagn Cytopathol*. 2005;32:97–102.
- [194] Raldow AC, Brown JG, Chau N, et al. Synchronous squamous cell carcinoma and diffuse large B-cell lymphoma of the head and neck: the odd couple. *BJR Case Reports*. 2016;2:20150271.
- [195] Rosado P, Fernández S, Junquera L, et al. Synchronous squamous cell carcinoma and chronic lymphocytic leukemia of the palate. *J Craniofac Surg*. 2011;22:348–50.
- [196] Rubiales AS, Martínez G, Aller JL, et al. Diagnóstico simultáneo de carcinoma microcítico de pulmón y enfermedad de Hodgkin. *An Med Interna*. 2006;23:301–2.
- [197] Sachdev R, Goel S, Goel RK, et al. Synchronous nodal involvement by metastatic adenocarcinoma and classical Hodgkin's lymphoma. *Turkish J Hematol*. 2017;34:272–3.
- [198] Saqib A, Ibrahim U, Maroun R. Primary pulmonary lymphoma and synchronous cecal adenocarcinoma: a rare occurrence. *Cureus*. 2016;8:e944.
- [199] Sasaki S, Hatanaka K, Sahara N, et al. Collision tumor of primary malignant lymphoma and adenocarcinoma in the colon: report of a case. *Surg Today*. 2010;40:975–81.
- [200] Satoh T, Arai E, Kayano H, et al. Pulmonary intravascular large B-cell lymphoma accompanying synchronous primary pulmonary adenocarcinoma and benign interstitial lesions. *J Clin Exp Hematop*. 2019;59:140–4.
- [201] Savari O, Hastings H, Rayes R, et al. Neuroendocrine neoplasia in extranodal marginal zone lymphoma of mucosa-associated lymphoid tissue (MALT lymphoma) of the lung: a case report and immunohistochemistry analysis of eight pulmonary MALT lymphomas. *Int J Surg Pathol*. 2018;26:660–3.
- [202] Serrano AG, Elsner B, Cabral Lorenzo MC, et al. Intravascular large B-Cell lymphoma and renal clear cell carcinoma as collision tumor: a case report and review of the literature. *Int J Surg Pathol*. 2020;29:106689692098163.

- [203] Shigeno T, Fujimori K, Tsuruta F, et al. Ileocecal collision tumor composed of adenocarcinoma and primary malignant lymphoma. *Clin J Gastroenterol.* 2011;4:79–84.
- [204] Siddiqui FA, Maheshwari V, Alam K, et al. Coexistent non-Hodgkins lymphoma and ductal carcinoma breast: diagnosis on fine needle aspiration cytology. *Diagn Cytopathol.* 2011;39:767–9.
- [205] Silvestris N, Zito FA, Fiore MG, et al. Synchronous presentation of B-cell chronic lymphocytic leukemia/small-cell lymphoma and colon adenocarcinoma within the same mesenteric lymph nodes and a single liver metastasis. *J Clin Oncol.* 2011;29:e11–3.
- [206] Singh NJ, Tripathy N, Roy P, et al. Simultaneous triple primary head and neck malignancies: a rare case report. *Head Neck Pathol.* 2016;10:233–6.
- [207] Singhal N, Quilty S, George M, et al. A tale of two cancers: collision presentation of ovarian carcinoma and lymphoma. *Aust New Zeal J Obstet Gynaecol.* 2009;49:232–4.
- [208] Soto AR, Vazquez EG, Grigg-Gutierrez NM, et al. Conundrum of a large bowel neoplasm: collision tumor. *ACG Case Reports J.* 2018;5:e13.
- [209] Srikumar T, Markow M, Centeno B, et al. Synchronous rectal adenocarcinoma and splenic marginal zone lymphoma. *Curr Oncol.* 2016;23:70–4.
- [210] Stokken J, Manz RM, Flagg A, et al. Synchronous occurrence of nasopharyngeal carcinoma and Hodgkin lymphoma. *Int J Pediatr Otorhinolaryngol.* 2014;78:154–6.
- [211] Strofilas A, Dalianoudis IG, Lagoudianakis EE, et al. Collision tumour of the stomach with a cancer to cancer metastasis: a case report. *Cases J.* 2008;1:63.
- [212] Sugihara S, Yamaguchi A, Matsumura K, et al. Concurrent malignant lymphoma of the jejunum and multiple synchronous colon cancers. *Am J Gastroenterol.* 1983;78:341–5.
- [213] Sun L, Zhang B, Xuan K, et al. Synchronous primary pulmonary adenocarcinoma and extranodal marginal zone lymphoma of mucosa-associated lymphoid tissue. *Medicine (Baltimore).* 2020;99:e20865.
- [214] Sun Y, Shi Y-F, Zhou L-X, et al. Synchronous pulmonary squamous cell carcinoma and mantle cell lymphoma of the lymph node. *Case Rep Genet.* 2011;2011:1–5.
- [215] Susnik B, Jordi Rowe J, Redlich PN, et al. A unique collision tumor in breast: invasive ductal carcinoma and mucosa-associated lymphoid tissue lymphoma. *Arch Pathol Lab Med.* 2004;128:99–101.
- [216] Suzuki S, Tanioka F, Inaba K, et al. A rare collision tumor composed of follicular lymphoma and adenocarcinoma in the ampulla of Vater: a case report. *Case Rep Pathol.* 2014;2014:1–6.
- [217] Sztarkier I, Levy I, Walfisch S, et al. Mantle cell lymphoma in a tubular adenoma: unusual presentation with synchronous colonic carcinoma. *Ann Diagn Pathol.* 2009;13:47–9.
- [218] Szumera-Cieckiewicz A, Bikowska-Opalach B, Prochorec-Sobieszek M. Double trouble” – synchronous mantle cell lymphoma and metastatic squamous cell carcinoma in an inguinal lymph node. *Polish J Pathol.* 2017;68:270–4.
- [219] Takeshima F, Kunisaki M, Aritomi T, et al. Hepatic mucosa-associated lymphoid tissue lymphoma and hepatocellular carcinoma in a patient with hepatitis b virus infection. *J Clin Gastroenterol.* 2004;38:823–6.
- [220] Tamaoki M, Nio Y, Tsuboi K, et al. A rare case of non-invasive ductal carcinoma of the breast coexisting with follicular lymphoma: a case report with a review of the literature. *Oncol Lett.* 2014;7:1001–6.
- [221] Tang C-C, Shih L-Y, Chen P-C, et al. Simultaneous occurrence of gastric adenocarcinoma and low-grade gastric lymphoma of mucosa-associated lymphoid tissue. *Chang Gung Med J.* 2002;25:115–21.
- [222] Teh BC, Hsueh S. Collision tumor of the stomach--a case report. *Chang yi xue za zhi.* 1989;12:167–73.
- [223] Tezer MS, Tuncel U, Özlügedik S, et al. Coexistence of laryngeal squamous cell carcinoma and non-Hodgkin's lymphoma with nasopharyngeal involvement. *J Laryngol Otol.* 2006;120:e2.
- [224] Thway K, Freeman A, Woodhouse CRJ, et al. Epithelial-stromal tumor of seminal vesicle in a patient with chromophobe renal cell carcinoma and small lymphocytic lymphoma. *Ann Diagn Pathol.* 2008;12:433–9.
- [225] Tihan T, Filippa DA. Coexistence of renal cell carcinoma and malignant lymphoma. A causal relationship or coincidental occurrence? *Cancer.* 1996;77:2325–31.
- [226] Tillawi IS. Collision tumor-concurrent involvement of Virchow's lymph node by Hodgkin's disease and metastatic gastric adenocarcinoma. A Troisier's sign and more? *Saudi Med J.* 2007;28:778–82.
- [227] Tseng C-E. Synchronous adenocarcinoma and extranodal natural killer/T-cell lymphoma of the colon: a case report and literature review. *World J Gastroenterol.* 2013;19:1850.
- [228] Tunc M. Non-Hodgkin lymphoma and Kaposi sarcoma in an eyelid of a patient with acquired immunodeficiency syndrome. *Arch Ophthalmol.* 1997;115:1464.
- [229] Vaiphei K, Chopra R, Singh R, et al. Synchronous adenocarcinoma and MALT lymphoma of stomach. *Indian J Gastroenterol.* 1999;18:36–8.
- [230] Velu ARK. Colonic adenocarcinoma, mucosa associated lymphoid tissue lymphoma and tuberculosis in a segment of colon: a case report. *World J Gastrointest Oncol.* 2014;6:377.
- [231] Vicente Baz D, Contreras JA, Maestro E, et al. Tumor de colisión. Adenocarcinoma y linfoma MALT gástrico sincrónicos. *Med Clin (Barc).* 2005;124:318–9.
- [232] Wagle SD, Mohandas KM, Vazifdar KF, et al. Synchronous adenocarcinoma and lymphoma of the colon. *Indian J Gastroenterol.* 1997;16:28–9.
- [233] Wahner-Roedler DL, Reynolds CA, Boughey JC. Collision tumors with synchronous presentation of breast carcinoma and lymphoproliferative disorders in the axillary nodes of patients with newly diagnosed breast cancer: a case series. *Clin Breast Cancer.* 2011;11:61–6.
- [234] Wang BY, Strauchen JA, Rabinowitz D, et al. Renal cell carcinoma with intravascular lymphomatosis: a case report of unusual collision tumors with review of the literature. *Arch Pathol Lab Med.* 2001;125:1239–41.
- [235] Wang W, Li P. Coexistence of colon adenocarcinoma, diffuse large B-cell lymphoma, and myelodysplastic syndrome. *Medicine (Baltimore).* 2019;98:e16742.
- [236] Wang Z, Zhong M. Coexisting primary central nervous system non-Hodgkin's lymphoma and colorectal adenocarcinoma: a case report. *Oncol Lett.* 2014;7:994–6.
- [237] Watanabe N, Inohara H, Akahani S, et al. Synchronous squamous cell carcinoma and malignant lymphoma in the head and neck region. *Auris Nasus Larynx.* 2007;34:273–6.
- [238] Wedemeyer J, Gebel MJ, Lotz J, et al. Malignant lymphoma accompanied by renal cell carcinoma - a not so rare coincidence? *Ultraschall Med.* 2004;25:65–9.
- [239] Weng C-H, Wang R-C, Wu C-C, et al. Treatment of synchronous adenocarcinoma and lymphoma of the stomach: a case report. *Mol Clin Oncol.* 2016;5:783–5.
- [240] Williamson CW, Paravati A, Ghassemi M, et al. Five simultaneous primary tumors in a single patient: a case report and review of the literature. *Case Rep Oncol.* 2015;8:432–8.
- [241] Woo EJ, Baugh AD, Ching K. Synchronous presentation of invasive ductal carcinoma and mantle cell lymphoma: a diagnostic challenge in menopausal patients. *J Surg Case Reports.* 2016;2016:rjv153.
- [242] Wotherspoon AC, Isaacson PG. Synchronous adenocarcinoma and low grade B-cell lymphoma of mucosa associated lymphoid tissue (MALT) of the stomach. *Histopathology.* 1995;27:325–31.
- [243] Wu H, Wei L, Hao L, et al. Synchronous Hodgkin lymphoma and gastric adenocarcinoma. *Medicine (Baltim).* 2018;97:e9484.
- [244] Xue L-J, Yang J-H, Su Q-S, et al. Synchronous gastric carcinoma and nodal malignant lymphoma: a rare case report and literature review. *Case Rep Oncol.* 2010;3:223–30.
- [245] Yağcıntaş Arslan U, Öksüzöğlü B, Önder FO, et al. Concomitant Hodgkin's lymphoma and gastric adenocarcinoma: a rare coincidence. *Med Oncol.* 2011;28:251–4.
- [246] Yamasaki M, Takenaka T, Matsumoto N, et al. Primary pulmonary collision tumor comprising squamous cell carcinoma and mucosa-associated lymphoid tissue lymphoma. *Lung Cancer.* 2019;129:107–9.
- [247] Yamazaki H, Nakatogawa N, Ota Y, et al. Development of follicular lymphoma of the cervical lymph nodes in a postoperative patient with tongue cancer. *Oral Surg Oral Med Oral Pathol Oral Radiol.* 2012;113:e35–9.
- [248] Yanagawa N, Ogata S, Fukushima N, et al. Synchronous double malignant tumors consisting of stomach and Hodgkin's lymphoma with collision between gastric adenocarcinoma and Hodgkin's lymphoma in the stomach. *Case Rep Gastroenterol.* 2012;6:797–802.
- [249] Yang JH, Lee J, Kim SB, et al. Synchronous diffuse large B-cell lymphoma of the small intestine and adenocarcinoma of the colon. *Korean J Intern Med.* 2018;33:438–41.
- [250] Yap J, Soh A. Adenocarcinoma of the proximal rectum and synchronous non-Hodgkin's lymphoma. *J Gastrointest Oncol.* 2013;4:101–2.
- [251] Lin YS, Hamilton AER, Henderson C, et al. Tiny but mighty: collision tumor of a superficial adenocarcinoma arising from a tubulovillous adenoma with associated low-grade follicular lymphoma. *Int J Surg Pathol.* 2021;29:759–763.
- [252] Yildirim M, Belli S, Ozsoy S, et al. Primary triple head and neck tumors: laryngeal squamous cell carcinomas, Kaposi's sarcoma, and non-Hodgkin's lymphoma. *Indian J Pathol Microbiol.* 2019;62:454.

- [253] Yokota K, Namikawa T, Maeda M, et al. Synchronous duodenal mucosa-associated lymphoid tissue lymphoma and gastric cancer. *Clin J Gastroenterol.* 2021;14:109–14.
- [254] Yoshino A, Kobayashi E, Shiomi M, et al. A successful intraoperative diagnosis of coexisting lymphoma and endometrial cancer. *World J Surg Oncol.* 2019;17:166.
- [255] Zaimoku K, Aoki Y, Miwa Y, et al. A collision tumor between squamous cell carcinoma and malignant lymphoma of urinary bladder: a case report. *Hinyokika Kyo.* 1998;44:179–82.
- [256] Zhang Y, Li G, Zhuang H. Unsuspected synchronous lung cancer unveiled on FDG pet after chemotherapy for non-Hodgkin lymphoma. *Clin Nucl Med.* 2008;33:109–10.
- [257] Zhong J, Di L, Zheng W. Synchronous breast cancer and breast lymphoma: two case reports and literature review. *Chin J Cancer Res.* 2014;26:355–9.
- [258] Zhu D, Fang C, Chen H, et al. Synchronous breast carcinoma and chronic lymphocytic leukemia in a Chinese young female: a rare combination. *Int J Clin Exp Pathol.* 2015;8:5952–4.
- [259] Kir G, Sarbay B, Ozpek A. Cytodiagnosis of primary thyroid lymphoma coincident with unnoticed papillary thyroid carcinoma: a case report and review of the literature. *J Cytol.* 2018;35:187–9.
- [260] Fujii T, Ohno N, Matsui T, et al. A case of synchronous diffuse large B-cell lymphoma of the right breast and invasive ductal carcinoma of the left breast. *Gan To Kagaku Ryoho.* 2019;46:1775–8.
- [261] De Tomás Palacios J, Escat Cortés JL, Lago Oliver J. Linfoma folicular axilar sincrónico con carcinoma mamario. *Hallazgo Casual Realizar Biopsia Ganglio Centinela Oncol.* 2000;23:47–9.
- [262] Fernández Bermejo LA, Toral Revuelta JR, Rueda Rodríguez B, et al. Carcinoma de mama metastásico en ganglios axilares con linfoma no Hodgkin: Tumor de colisión. *Sanid Mil.* 2018;74:20–3.
- [263] Nakamura S, Aoyagi K, Iwanaga S, et al. Synchronous and metachronous primary gastric lymphoma and adenocarcinoma: a clinicopathological study of 12 patients. *Cancer.* 1997;79:1077–85.
- [264] Schwartz LH, Ozsahin M, Zhang GN, et al. Synchronous and metachronous head and neck carcinomas. *Cancer.* 1994;74:1933–8.
- [265] Bedi GC, Westra WH, Gabrielson E, et al. Multiple head and neck tumors: evidence for a common clonal origin. *Cancer Res.* 1996;56:2484–7.
- [266] Horii A, Han HJ, Shimada M, et al. Frequent replication errors at microsatellite loci in tumors of patients with multiple primary cancers. *Cancer Res.* 1994;54:3373–5.
- [267] Ambrosiani L, Bellone S, Declich P, et al. Breast carcinoma metastatic to a lymphoma: report of a case with review of literature. *Histopathology.* 1999;34:87–9.
- [268] Ray-Coquard I, Cropet C, Van Glabbeke M, et al. Lymphopenia as a prognostic factor for overall survival in advanced carcinomas, sarcomas, and lymphomas. *Cancer Res.* 2009;69:5383–91.
- [269] Chew V, Tow C, Teo M, et al. Inflammatory tumour microenvironment is associated with superior survival in hepatocellular carcinoma patients. *J Hepatol.* 2010;52:370–9.
- [270] Wilson NS, Villadangos JA. Regulation of antigen presentation and cross-presentation in the dendritic cell network: facts, hypothesis, and immunological implications. *Adv Immunol.* 2005;86:241–305.
- [271] Villadangos JA, Schnorrer P. Intrinsic and cooperative antigen-presenting functions of dendritic-cell subsets in vivo. *Nat Rev Immunol.* 2007;7:543–55.
- [272] Steinman RM, Hemmi H. Dendritic cells: translating innate to adaptive immunity. *Curr Top Microbiol Immunol* 2006;311:17–58.
- [273] Cahalan MD, Parker I. Imaging the choreography of lymphocyte trafficking and the immune response. *Curr Opin Immunol.* 2006;18:476–82.
- [274] Pasqualucci L. Molecular pathogenesis of germinal center-derived B cell lymphomas. *Immunol Rev.* 2019;288:240–61.
- [275] Nussenzweig A, Nussenzweig MC. Origin of chromosomal translocations in lymphoid cancer. *Cell.* 2010;141:27–38.
- [276] Hadj Khodabakhshi A, Morin RD, Fejes AP, et al. Recurrent targets of aberrant somatic hypermutation in lymphoma. *Oncotarget.* 2012;3:1308–19.
- [277] Suarez F, Lecuit M. Infection-associated non-Hodgkin lymphomas. *Clin Microbiol Infect.* 2015;21:991–7.
- [278] Smedby KE, Hjalgrim H, Askling J, et al. Autoimmune and chronic inflammatory disorders and risk of non-Hodgkin lymphoma by subtype. *JNCI J Natl Cancer Inst.* 2006;98:51–60.
- [279] Männel DN, Orosz P, Hafner M, et al. Mechanisms involved in metastasis enhanced by inflammatory mediators. *Circ Shock.* 1994;44:9–13.
- [280] Skinnider BE, Mak TW. The role of cytokines in classical Hodgkin lymphoma. *Blood.* 2002;99:4283–97.
- [281] Peter S, Beglinger C. Helicobacter pylori and gastric cancer: the causal relationship. *Digestion.* 2007;75:25–35.
- [282] Correa P, Piazuelo MB. Helicobacter pylori infection and gastric adenocarcinoma. *US Gastroenterol Hepatol Rev.* 2011;7:59–64.
- [283] Isaacson PG. Mucosa-associated lymphoid tissue lymphoma. *Semin Hematol.* 1999;36:139–47.