

VIEW POINT

Combined fissurectomy and botulinum toxin injection

A new therapeutic approach for chronic anal fissures

Fissurectomie couplée à l'injection de toxine botulique : une nouvelle thérapeutique pour les fissures anales chroniques

C. Soll, D. Dindo, D. Hahnloser*

Department of Visceral and Transplantation Surgery, University Hospital Zurich, Raemistrasse 100, 8091 Zurich, Switzerland

Available online 12 May 2008

Introduction

Anal fissures are tears or splits in the squamous epithelium of the anus just distal to the dentate line. The majority of anal fissures are found in the posterior midline with up to 13% in the anterior midline [1]. Acute and chronic anal fissures are differentiated chronologically and morphologically. Most surgeons define a fissure as chronic when it persists beyond six weeks and healing with conservative treatment seems unlikely [2]. Morphologically, chronic anal fissures, as opposed to acute fissures, are characterized by hypertrophy of the anal papilla, a sentinel skin tag, rolled skin edges and exposed internal sphincter muscle.

Patients with acute anal fissure rarely present to the surgeon, because they respond to conservative treatment for up to 90% [3]. The treatment of chronic anal fissures is still challenging. Conservative treatment with topical nitrates or calcium channel blockers is often dissatisfying. On the other hand, surgical treatment such as lateral internal sphincterotomy is accompanied with considerable postoperative incontinence. Temporary “chemical sphincterotomy” with botulinum toxin (botox) alone can achieve healing rates of 65% in chronic fissures; however, these results are not uniform [4]. Recently, botox has been combined with fissurectomy achieving healing rates for chronic fissures in up to 90% [5–7].

The aims of this point of view are to discuss indications, contraindications, technical aspects and the efficacy of botox treatment in combination with fissurectomy for chronic anal fissures. The therapy of acute fissures and the numerous other treatment strategies and practice para-

* Corresponding author.

E-mail address: dieter.hahnloser@usz.ch (D. Hahnloser).

meters for the management of chronic anal fissures are described elsewhere [8,9] and will not be discussed. For the comparison of the surgical techniques, we recommend Nelson's "Operative procedures for fissure in ano" [10].

Botulinum toxin (Botox)

Botulinum toxin type A is produced by *Clostridium botulinum* and is known to be one of the most lethal neurotoxins. *Clostridium botulinum* grows in inadequately sterilized canned foods. Its toxin blocks synaptic release of acetylcholine and causes a severe paralysis of respiratory and skeletal muscles (botulism). Botox became popular in cosmetic surgery for treatment of crinkles in the face. Medical uses for the toxin are blepharospasm, strabismus, spasmodic torticollis, spastic cerebral palsy. The use of the toxin was also reported for anismus and achalasia of the esophagus [11]. Jost and Schimrigk reported for the first time the treatment of anal fissures with botox [12].

Aetiology and pathogenesis of anal fissures

Traditionally, an anal fissure was thought to be due to constipation and passage of hard stool. But, history of constipation is elicited in fewer than 25% of patients with chronic anal fissures. Also, diarrhea is known as a predisposing factor in up to 7% of patients [8]. Today, an increased tonicity of the internal sphincter is blamed for anal fissures. Tonic contraction of the internal anal sphincter is mediated by sympathetic innervations, which stays in state of partial contraction and relaxation in response to rectal distension. Several reports have documented elevated resting anal pressures in fissure patients with values above 90 mmHg [13]. Additionally, the elevated anal pressure causes ischemia of the posterior commissure and reduces the anodermal blood flow [13]. The combined concept of sphincter spasm and reduced anodermal blood flow not only explains how surgical disruption of the internal anal sphincter allows the fissure to heal (anal pressures decreases with a rise of anal blood flow), but also gives the explanation on how botox works as treatment of anal fissures: botox relaxes the internal anal sphincter when injected into the muscle by causing temporary synaptic blockade and reversible denervation. This leads to a decrease of the anal pressure allowing the fissure to heal. The effect of botox is similar to surgical sphincterotomy without the disadvantage of an anatomical disruption of the internal anal sphincter.

However, it should be mentioned that the concept of sphincter spasm and reduced anal blood flow does not answer the question, whether sphincter spasm is the cause or effect of anal fissures. It is known that psychological stress produces sustained tonic rise in anal canal pressure and may be one factor in the aetiology of anal fissures [14–16]. In addition, fissures can also occur without sphincter spasm in underlying diseases, like human immunodeficiency virus infection, inflammatory bowel disease, perianal tuberculosis or sexual abuse, obstetric trauma, anorectal operations [1]. In these cases, fissures mostly present atypically being multiple and located on other sites than the 6 and 12 o'clock position.

Non-surgical treatment: the role of botox

Several studies have shown the efficacy of botox in non-surgical treatment of chronic anal fissures [3,4,17,18]. Maria et al. reported a higher healing rate compared to placebo (73% versus 13%) [19]. Botox reduces the anal resting pressure, an effect that persists for two to three months. Side-effects are transient incontinence for air in up to 10% [19–21] and for stool in up to 5% of patients [22]. Recurrence rates vary between 10 and 55% [20,21]. But note that, the use of botox is not without risk. Beside temporary incontinence for air and stool, other side-effects are reported, including necrotizing fasciitis, generalized muscular weakness, perianal thrombosis and the possibility of antibody production [13].

A recent meta-analysis [18] included three randomized controlled studies, which compared glyceryltrinitrate (GTN) and botox for chronic anal fissures. Botox was as effective as GTN, but associated with fewer side-effects showing a healing rate of 80%. But the main shortcomings of this analysis were the short follow-up of two months in one and the not reported recurrence rate in two of the included studies. The authors concluded that botox could be recommended as first-line treatment in patients with chronic anal fissures. However, they also stated that stronger evidence is needed to definitively support this treatment strategy because only three trials done on 180 patients were qualified for the meta-analysis. A Cochrane review showed no healing advantage of botox over placebo but noted the statistical heterogeneity and generally short follow-up of studies [23].

The current recommendation of the *American Society of Colon and Rectal Surgeons* states that botox injections may be used for chronic anal fissures that fail to respond to conservative measures [9] (evidence level II, recommendation B). However, there was no consensus on dosage, precise site of administration (internal anal sphincter, external anal sphincter, or intersphincteric space) and number of injections.

Botox in the context of surgical treatments

For refractory anal fissures, surgery is still the treatment of choice. Among the different surgical techniques, lateral internal sphincterotomy has shown the best healing and the lowest recurrence rates in different trials and meta-analyses [3,17,23]. However, there is a considerable risk for incontinence. Incontinence rates in the literature vary between 0 and 36% for gas, 0 and 21% for liquid stool and 0 and 5% for solid stool [2]. Today, it is known that faecal incontinence may occur many years after sphincter damage such as from complicated delivery or anal surgery [24]. For that reason, incontinence after lateral internal sphincterotomy has probably been underestimated [25]. A Cochrane review [23], including three trials on 235 patients, showed that lateral internal sphincterotomy compared to botox had superior healing rates (94% versus 67%). But botox caused no incontinence compared to lateral internal sphincterotomy (0% versus 11%) in two trials including 191 patients. Another recent meta-analysis [17], including four studies on 279 patients, concluded that surgical sphincterotomy and botox were comparable. Surgical sphincterotomy had a higher hea-

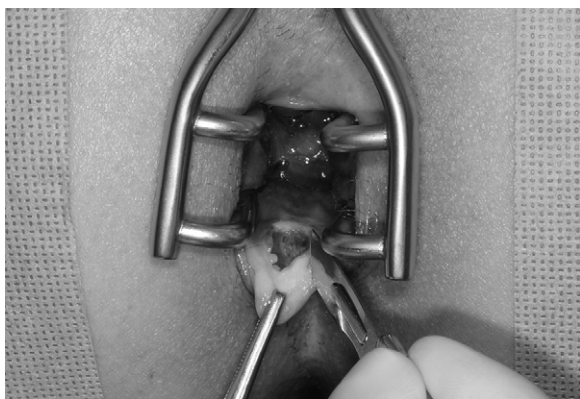

Figure 1 Surgical excision of fissure edges and sentinel skin tag. Triangle shape of excision facilitates wound drainage. *Résection chirurgicale des berges de la fissure avec sa marisque sentinelle. La forme triangulaire de l'excision favorise le drainage de la plaie.*

ling rate (95% versus 65%) and lower recurrence rate (8% versus 20%) than botox and there were no differences in complications and incontinence rates.

Fissurectomies with removal of the fibrotic edges of the fissure and resection of anal papilla and the skin tag, respectively (Fig. 1), have been successfully applied as alternative for lateral internal sphincterotomy in the treatment of chronic anal fissures in pediatric studies [26]. The concept of fissurectomy, in combination with reversible chemical sphincterotomy (or botox), was first introduced by Engel et al. in 2002 [27]. The fissurectomy, as wound debridement, supports wound healing and botox injection (Fig. 2), decreases the tonus of the internal anal sphincter temporary leading to an increased anal blood flow. We have recently demonstrated that this technique is safe, may be done in an outpatient setting and may achieve healing rates of 79% after one year with a recurrence rate of 9%. We observed no incontinence in these patients [6]. These results were in accordance with Lindsey et al. [7] who described a healing rate of 93% after 16 weeks and transitory flatus incontinence of 7%. Sileri et al. [5] compared different treatment strate-

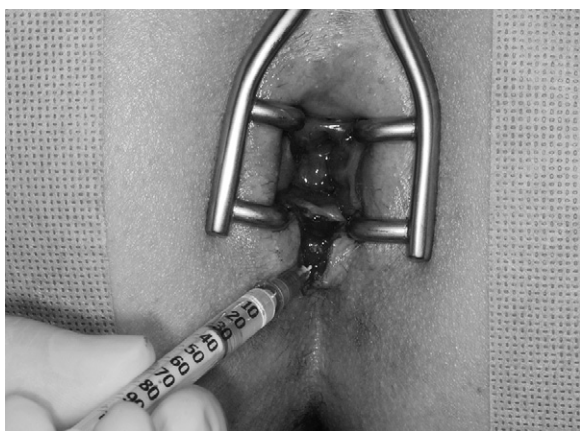


Figure 2 Injection of botulinum toxin on both sides of the fissure. *Injection de toxine botulique aux deux bords de la fissure.*

gies and described a healing rate of 82% with a follow-up for 19 months without recurrences for fissurectomy combined with botox. Incontinence for flatus was described in 4.5% of patients.

Conclusions

The significance of botox in the treatment of chronic anal fissures is still puzzling. Data in the literature are inconsistent and final conclusions cannot be drawn. From our point of view, botox will not replace surgical treatment for refractory anal fissures. Also, current data do not provide evidence for a clear benefit for the patient as non-surgical first-line treatment not justifying the high costs of botox treatment (100 U Botox®, Allergan costs 260 €). Fissurectomy and botox injection, however, treats both main causes of chronicity of anal fissures, the presence of bradytrophic scar tissue and the high resting anal pressure. This combined treatment strategy is very promising for the treatment of chronic anal fissures with a high success rate and a low morbidity and most importantly with very little risk of incontinence.

References

- [1] Lund JN, Scholefield JH. Aetiology and treatment of anal fissure. *Br J Surg* 1996;83:1335–44.
- [2] Lindsey I, Jones OM, Cunningham C, Mortensen NJ. Chronic anal fissure. *Br J Surg* 2004;91:270–9.
- [3] Nelson R. A systematic review of medical therapy for anal fissure. *Dis Colon Rectum* 2004;47:422–31.
- [4] Nelson R. Non-surgical therapy for anal fissure. *Cochrane Database Syst Rev* 2003. CD003431.
- [5] Sileri P, Mele A, Stolfi VM, Grande M, Sica G, Gentileschi P, et al. Medical and surgical treatment of chronic anal fissure: a prospective study. *J Gastrointest Surg* 2007;11:1541–8.
- [6] Scholz T, Hetzer FH, Dindo D, Demartines N, Clavien PA, Hahnloser D. Long-term follow-up after combined fissurectomy and Botox injection for chronic anal fissures. *Int J Colorectal Dis* 2007;22:1077–81.
- [7] Lindsey I, Cunningham C, Jones OM, Francis C, Mortensen NJ. Fissurectomy–botulinum toxin: a novel sphincter-sparing procedure for medically resistant chronic anal fissure. *Dis Colon Rectum* 2004;47:1947–52.
- [8] Collins EE, Lund JN. A review of chronic anal fissure management. *Tech Coloproctol* 2007;11:209–23.
- [9] Orsay C, Rakinic J, Perry WB, Hyman N, Buie D, Cataldo P, et al. Practice parameters for the management of anal fissures (revised). *Dis Colon Rectum* 2004;47:2003–7.
- [10] Nelson R. Operative procedures for fissure in ano. *Cochrane Database Syst Rev* 2005. CD002199.
- [11] Montecucco C, Molgo J. Botulinum neurotoxins: revival of an old killer. *Curr Opin Pharmacol* 2005;5:274–9.
- [12] Jost WH, Schimrigk K. Use of botulinum toxin in anal fissure. *Dis Colon Rectum* 1993;36:974.
- [13] Ayantunde AA, Debrah SA. Current concepts in anal fissures. *World J Surg* 2006;30:2246–60.
- [14] Farouk R, Duthie GS, MacGregor AB, Bartolo DC. Sustained internal sphincter hypertonia in patients with chronic anal fissure. *Dis Colon Rectum* 1994;37:424–9.
- [15] Schouten WR, Briel JW, Auwerda JJ, De Graaf EJ. Ischaemic nature of anal fissure. *Br J Surg* 1996;83:63–5.
- [16] Utzig MJ, Kroesen AJ, Buhr HJ. Concepts in pathogenesis and treatment of chronic anal fissure—a review of the literature. *Am J Gastroenterol* 2003;98:968–74.

- [17] Sajid MS, Hunte S, Hippolyte S, Kiri VA, Maringe C, Baig MK. Comparison of surgical vs chemical sphincterotomy using botulinum toxin for the treatment of chronic anal fissure: a meta-analysis. *Colorectal Dis* 2008;10:547–52.
- [18] Sajid MS, Vijaynagar B, Desai M, Cheek E, Baig MK. Botulinum toxin vs glyceryltrinitrate for the medical management of chronic anal fissure: a meta-analysis. *Colorectal Dis* 2007, doi:10.1111/j.1463-1318.2007.01387. Epub ahead of print <http://www.blackwell-synergy.com>.
- [19] Maria G, Cassetta E, Gui D, Brisinda G, Bentivoglio AR, Albanese A. A comparison of botulinum toxin and saline for the treatment of chronic anal fissure. *N Engl J Med* 1998;338:217–20.
- [20] Brisinda G, Maria G, Sganga G, Bentivoglio AR, Albanese A, Castagneto M. Effectiveness of higher doses of botulinum toxin to induce healing in patients with chronic anal fissures. *Surgery* 2002;131:179–84.
- [21] Jost WH, Schrank B. Repeat botulin toxin injections in anal fissure in patients with relapse and after insufficient effect of first treatment. *Dig Dis Sci* 1999;44:1588–9.
- [22] Jost WH. One hundred cases of anal fissure treated with botulin toxin: early and long-term results. *Dis Colon Rectum* 1997;40:1029–32.
- [23] Nelson R. Non surgical therapy for anal fissure. *Cochrane Database Syst Rev* 2006. CD003431.
- [24] Lunniss PJ, Gladman MA, Hetzer FH, Williams NS, Scott SM. Risk factors in acquired faecal incontinence. *J R Soc Med* 2004;97:111–6.
- [25] Casillas S, Hull TL, Zutshi M, Trzcinski R, Bast JF, Xu M. Incontinence after a lateral internal sphincterotomy: are we underestimating it? *Dis Colon Rectum* 2005;48:1193–9.
- [26] Lambe GF, Driver CP, Morton S, Turnock RR. Fissurectomy as a treatment for anal fissures in children. *Ann R Coll Surg Engl* 2000;82:254–7.
- [27] Engel AF, Eijsbouts QA, Balk AG. Fissurectomy and isosorbide dinitrate for chronic fissure in ano not responding to conservative treatment. *Br J Surg* 2002;89:79–83.