
UNIVERSITE DE LAUSANNE - FACULTE DE BIOLOGIE ET DE MEDECINE

Département des services de chirurgie et anesthésiologie
Service de Chirurgie Cardio-Vasculaire

**The transventricular-transseptal access to the aortic root: a new route
for extrapleural trans-catheter aortic stent-valve implantation.**

THESE

préparée sous la direction du Professeur Ludwig Karl von Segesser
avec la collaboration du Docteur Enrico Ferrari

et présentée à la Faculté de biologie et de médecine de
l'Université de Lausanne pour l'obtention du grade de

DOCTEUR EN MEDECINE

par

Ligang LIU

Médecin diplômé de la République Populaire de Chine
Originaire de Shandong (R.P. Chine)

WG
265
LIU

Lausanne

2011

BME 3619

Bibliothèque Universitaire
de Médecine / BiUM
CHUV-BH08 - Bugnon 46
CH-1011 Lausanne

R00637A18

Imprimatur

Vu le rapport présenté par le jury d'examen, composé de

Directeur de thèse Monsieur le Professeur Ludwig Karl Von Segesser

Co-Directeur de thèse

Expert Monsieur le Professeur titulaire Pierre Vogt

Directrice de l'Ecole Madame le Professeur Stephanie Clarke
doctorale

la Commission MD de l'Ecole doctorale autorise l'impression de la thèse de

Monsieur Ligang Liu

intitulée

***The transventricular-transseptal access to the aortic root: a
new route for extrapleural trans-catheter aortic stent-valve
implantation***

Lausanne, le 30 septembre 2011

*pour Le Doyen
de la Faculté de Biologie et de Médecine*



*Madame le Professeur Stephanie Clarke
Directrice de l'Ecole doctorale*

The transventricular—transseptal access to the aortic root: a new route for extrapleural trans-catheter aortic stent-valve implantation.

Docteur Ligang Liu.

Directeur de thèse: Professeur Ludwig Karl von Segesser.

Avec la collaboration du Docteur Enrico Ferrari.

Rapport de synthèse

Objectif: le remplacement valvulaire aortique par voie transcathétère est, actuellement, une méthode fiable indiquée pour des patients à haut risque porteurs d'une sténose valvulaire aortique. La voie transfémorale est utilisable seulement en cas d'absence de maladie vasculaire et la voie transapicale est contraindiquée en cas de dysfonction pulmonaire chronique sévère. Une alternative pour ne pas passer à travers l'espace pleural serait par voie sous-xiphœidienne et trans-septale à travers le ventricule droit.

Méthode: une expérience animale a été amené au laboratoire de recherche du CHUV. Cinq cochons (poids : 52.3 ± 10.9 kg) ont été endormi et, sous anesthésie générale, le ventricule droit a été préparé à travers un accès sous-xiphœidien. Ensuite, sous guide fluoroscopique et avec l'utilisation d'une échocardiographie intracardiaque, un accès trans-septal a été créé entre le ventricule droit et le ventricule gauche en utilisant des dilateurs de diamètre croissant (de 8F à 26F). Par la suite, une valve stentée créée dans le laboratoire en utilisant un stent en nitinol et du péricarde a été chargée dans une cartouche et introduite dans le ventricule gauche à travers un introducteur trans-septal. Enfin, la valve a été amenée dans la chambre de chasse du ventricule gauche et ensuite dans la racine aortique et puis déployée au bon endroit. Quand le système a été retiré, le septum ventriculaire a pu être réparé par mise en place d'un système d'occlusion septal Amplatzer. Trente minutes après la procédure, les animaux ont été sacrifiés et le cœur a été analysé pour étudier le positionnement de la valve stentée, l'efficacité de la fermeture du septum inter-ventriculaire et la fermeture de la paroi du ventricule droit.

Résultat : les cinq cochons ont tous eu un parfait positionnement et pose de la prothèse en position aortique au premier essai (efficacité 100%). Les procédures ont duré, moyennement, 49 ± 4 minutes et la progressive dilatation de l'accès trans-septal a donné lieu à une communication inter-ventriculaire mesurable après dilatation avec du 18F et plus. Toutes les valves stentées ont été déployées au bon endroit avec un bon résultat du fonctionnement des valves prothétiques et absence d'insuffisance para prothétique. Pendant les procédures, des battements prématurés ainsi que des épisodes isolés de tachycardie supra ventriculaire ont été détectés. Par contre, il n'y a pas eu de bloc atrio-ventriculaire. Les pertes sanguines pendant les procédures étaient de 280 ± 10 mL, et les systèmes d'occlusion Amplatzer étaient tous bien déployés sans shunts inter-ventriculaires résiduels.

Conclusion: la technique d'introduction de valve stentées par voie extrapleurale (trans-ventriculaire et trans-septale) est techniquement possible et elle jette les bases pour le remplacement valvulaire aortique trans-ventriculaire sous anesthésie locale.

The transventricular–transseptal access to the aortic root: a new route for extrapleural trans-catheter aortic stent-valve implantation[☆]

Ligang Liu^{*}, Piergiorgio Tozzi, Enrico Ferrari, Ludwig K. von Segesser

Department of Cardio-Vascular Surgery, University Hospital of Lausanne (CHUV), Rue du Bugnon 46, CH-1011 Lausanne, Switzerland

Received 9 March 2010; received in revised form 21 April 2010; accepted 26 April 2010

Abstract

Objective: The aim of this study was to investigate the feasibility of transventricular–transseptal approach (TVSA) for extrapleural trans-catheter aortic valved stent implantation via a subxyphoidian access. **Methods:** In five porcine experiments (52.3 ± 10.9 kg) the right ventricle was exposed via subxyphoidian access. Under the guidance of intracardiac echocardiography (ICE) and fluoroscopy, the transseptal access from right ventricle to left ventricle was created progressively by puncture and dilation with dilators (8F–26F). Valved stents built in-house from commercial tanned pericardium and self-expandable Nitinol stents were loaded into a cartridge. A delivery sheath was then introduced from the right ventricle into the left ventricle and then into the ascending aorta. The cartridge was connected and the valved stent was deployed in the aortic position. Then, the ventricular septal access was sealed with an Amplatzer septal occluder device and the right ventricular access was closed by tying prepared purse-string suture directly. Thirty minutes after the whole procedure, the animals were sacrificed for macroscopic evaluation of the position of valved stent and septal closure device. **Result:** Procedural success of TVSA was 100% at the first attempt. Mean procedure time was 49 ± 4 min. Progressive dilatation of the transseptal access resulted in a measurable ventricular septal defect (VSD) after dilator sizes 18F and more. All valved stents were delivered at the target site over the native aortic valve with good acute valve function and no paravalvular leaks. During the procedure, premature beats (5/5) and supraventricular tachycardias (5/5) were observed, but no atrial-ventricular block (0/5) occurred. Heart rate before (after) was 90 ± 3 beats min^{-1} (100 ± 2 beats min^{-1} ; $p < 0.05$), whereas blood pressure was 60 ± 1 mm Hg (55 ± 2 mm Hg ($p < 0.05$)). Total blood loss was 280 ± 10 ml. The Amplatzer septal occluder devices were fully deployed and the ventricular septal accesses were sealed successfully, without detectable residual shunt. **Conclusion:** Trans-catheter implantation of aortic valved stent via extrapleural transventricular–transseptal access is technically feasible and has the potential for a simplified procedure under local anaesthesia.

© 2010 European Association for Cardio-Thoracic Surgery. Published by Elsevier B.V. All rights reserved.

Keywords: Transventricular septal approach; Aortic valved stent implantation; Amplatzer septal occluder

1. Introduction

Trans-catheter aortic valve implantation (TAVI) [1] is growing rapidly and it has been demonstrated for the trans-apical route [2,3] that an excellent result can be achieved with minimal risk of stroke or atrial-ventricular block [4,5], and, of course no damage of access vessels. However, the trans-apical route has so far been realised through a mini-thoracotomy, which, in turn, requires general anaesthesia. We have previously reported a video-endoscopic approach [6], which has been realised in the experimental setting in combination with modified closure devices [7,8] to achieve

rapid sealing of the trans-apical access orifice. Although this approach is less invasive, it is still a transpleural route with all its limitations.

The opening of the pleural space can be avoided with a subxyphoid access, and we have used this route for implantation of a stent valve into a right ventricle (RV)-pulmonary artery conduit with a degenerated valve by puncture of the right ventricle [9]. In the experimental setting, we have also reached the left ventricle and the aorta from a subxyphoid or rather a trans-umbilical approach to implant an aortic stent-valve through a natural orifice [10] for namely, Natural Orifice Transluminal Endoscopic Surgery [11]. Interestingly enough, the pulmonary artery and the aorta could be accessed both in reproducible fashion with this experimental single port approach in combination with closure devices for sealing of the transparietal ventricular access orifices.

In the clinical setting, however, it appears to be more difficult to access the left ventricle with a subxyphoid technique because of the natural position of the human

[☆] Dr Ligang Liu benefits from the post-thoracic residency fellowship for a 1-year period at the Department of Cardiovascular Surgery of CHUV (Lausanne, Switzerland).

^{*} Corresponding author. Address: Department of Cardiothoracic Surgery, Tongji Hospital, Huazhong University of Science and Technology, No. 1095 Jiefang Avenue, Wu Han, 430030, China. Tel.: +86 27 83663408; fax: +86 27 83663671.

E-mail address: liuligang@hotmail.com (L. Liu).

heart, which tends to expose mainly the right ventricle in the antero-diaphragmatic position, whereas the left ventricle is usually latero-posterior. Hence, the idea was to approach the aortic root in transventricular–transseptal fashion by passing through the right ventricle and the septum to reach the left side and ultimately the aortic route.

2. Materials and methods

2.1. Valved stent construction

The valved stents used in this study were built from two components: a double-crowned [12] self-expandable Nitinol stent [13] with a waist diameter of 25 mm (Symetis SA, Lausanne, Switzerland, shown in Fig. 1(D)) and inside a pericardial valve, which was made in-house from glutaraldehyde-preserved equine pericardium as shown in Fig. 1(A)–(C)). *In vitro* bench tests were realised with the Dynatek Delta MP3 system as previously reported [13].

2.2. Delivery system

The stent-valve delivery system was based on a commercial introducer for trans-apical aortic valve implantations with an external diameter of 30F and total length of 22 cm, which was modified for use with a self-expanding stent-valve design by adding a pusher with a blunt tip. The valved stent was compressed with a commercial crimper over a guide wire and a catheter, and loaded into a cartridge. Once the introducer was positioned in transventricular–transseptal fashion, the cartridge was connected to the valved sheath and the stent valve was transferred with the pusher. No balloon was necessary to deliver the thermosensitive Nitinol stent, which expanded immediately as soon as it was released from the sheath.

2.3. Access closure device

An Amplatzer muscular septal occluder (AGA Medical Corp, Golden Valley, MN, USA), which is made of woven

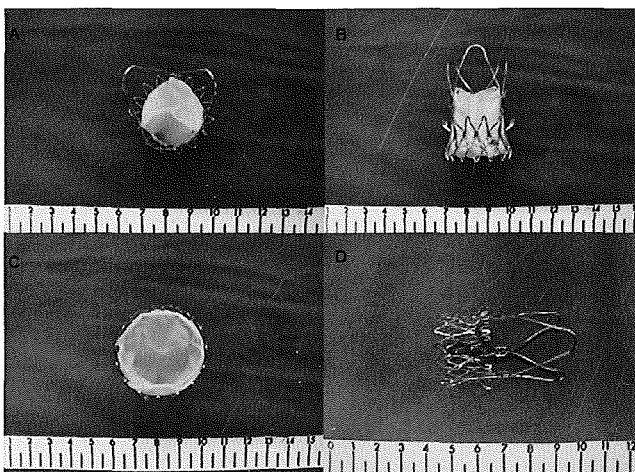


Fig. 1. The self-expandable valved Nitinol stent, which consisted of a self-expandable Nitinol stent (D) and a homemade equine pericardial trileaflet valve with single point attachment (A, B and C).

Nitinol wires into two self-expandable round concave retention disks with a connecting 7-mm waist, was used to seal the transventricular septal access after the deployment of the aortic valved stent. To pass more easily through the ventricular septal access, the Amplatzer delivery system was modified to allow for a monorail technique. After implantation of the aortic valved stent, the same guide wire was used to insert the closure device for sealing off the transseptal left ventricular access.

All of the above devices underwent thorough *in vitro* testing prior to the experimental *in vivo* implantation. All animals received care in compliance with 'the Principles of Laboratory Animals' formulated by the National Society of Medical Research and 'the Guide for the Care and Use of Laboratory Animals' prepared by the Institute of Laboratory Animal Resources and published by the National Institute of Health (NIH publication 85-23, revised 1985). The protocol was approved by the State Committee on Animal Research.

2.4. Surgical access

An acute *in vivo* evaluation was performed in five porcine experiments, aged from 9 to 12 weeks, with a mean body weight of 52.3 ± 10.9 kg. Before the procedure, general anaesthesia was induced with 22 mg kg^{-1} ketamine, 0.8 mg kg^{-1} atropine administered intramuscularly, and 15 mg kg^{-1} thiopental administered through a superficial vein of the right ear. Under general anaesthesia maintained with volatile anaesthetics, and mechanical ventilation, bilateral internal jugular veins and arteries were exposed. An intravenous line was placed in the right jugular vein. Then, the arterial pressure line was inserted into the right carotid artery. The left jugular vein was mobilised for the insertion of an intracardiac echocardiographic probe (ICE: Accuson Navigate, Accuson, Siemens, Munich, Germany). Continuous monitoring of electrocardiography, arterial pressure, central venous pressure and oxygen saturation was routine. The subxyphoid to paraxiphoid area was prepared and a 5-cm incision was made. Then, the diaphragmatic face of the right ventricle was exposed. A double 2/0 purse-string monofilament suture reinforced with felt pledgets was prepared in a zone of myocardium, without coronary arteries, on the diaphragmatic side of the right ventricle.

2.5. Transventricular-transseptal aortic valved stent implantation

First, the left ventricular outflow tract dimensions and the native aortic valve, including annular diameter, valvular surface and morphology of the aortic root were visualised and measured by intracardiac ultrasound. Then, a valved stent of optimal size was crimped and loaded into the delivery cartridge as outlined above. After systemic heparinisation (Liquemine[®], Roche, Switzerland: 100 IU kg^{-1}), the prepared area of right ventricle was punctured with a needle, followed by a guide wire, and then an over-the-wire 8F introducer system (Arrows, Reading, PA, USA) was inserted crossing the right ventricular cavity and the ventricular septum into the left ventricle. Under ICE and fluoroscopic guidance, a soft-tip J-type STARTER guide wire (0.035 inches, 180 cm; Boston Scientific, Natick, MA, USA) was first introduced into the left

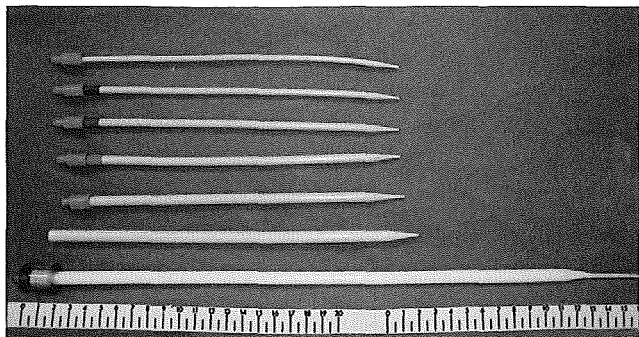


Fig. 2. The set of dilators used in this experiment, from 12F to 26F in size.

ventricle, then crossed the aortic annulus, and finally advanced into the descending aorta. Next, the soft-tip guide wire was exchanged with a pig-tail catheter for a Lunderquist extra stiff back-up guide wire (TSMG-35-260-LES, Cook Medical, Limerick, Ireland). A series of dilators with progressive diameters ranging from 12F to 26F was used to dilate the ventricular transseptal access up to the optimal size required for TAVI (shown in Fig. 2). At each step, the electrocardiogram and the haemodynamic parameters were recorded continuously, and the ventricular septum was monitored in real time under ICE to assess the dimensions of the ventricular septal defects (VSDs) and the shunt between the left and right ventricles.

Finally, the 30-F sheath was positioned in ascending aorta through the right ventricle–left ventricle (RV–LV) transseptal route. The cartridge with the preloaded stent valve was connected and transferred into the sheath as previously described. Once the stent valve could be identified by fluoroscopy in the ascending aorta, the sheath was slowly pulled back, and the stent valve was released in a stepwise fashion at the predetermined level of the aortic annulus.

2.6. Closure of both the ventricular access and the septal access

Under the guidance of ICE and fluoroscopy, a delivery sheath with an optimally sized muscular Amplatzer occluder device was inserted over the Lunderquist guide wire into the left ventricle. Then, the Amplatzer device was advanced within its sheath, while the 30-F sheath was withdrawn, until the left of the occluder disk was deployed on the left side of ventricular septum (in the left ventricle). Further retraction of the sheath over the delivery cable allowed the right disk to be deployed on the right side of the ventricular septum (in the right ventricle). At the end, the right ventricular access was closed by tying the purse-string sutures prepared at the beginning of the procedure.

2.7. Assessment of devices' position and function

The position and function of valved stent and Amplatzer septal occluder were assessed after their deployment for 30 min by ICE. Then, animals were sacrificed to re-examine the position of the valved stents and the Amplatzer device at necropsy.

Data were analysed with SPSS software (Statistical Package for the Social Sciences). Continuous variables were

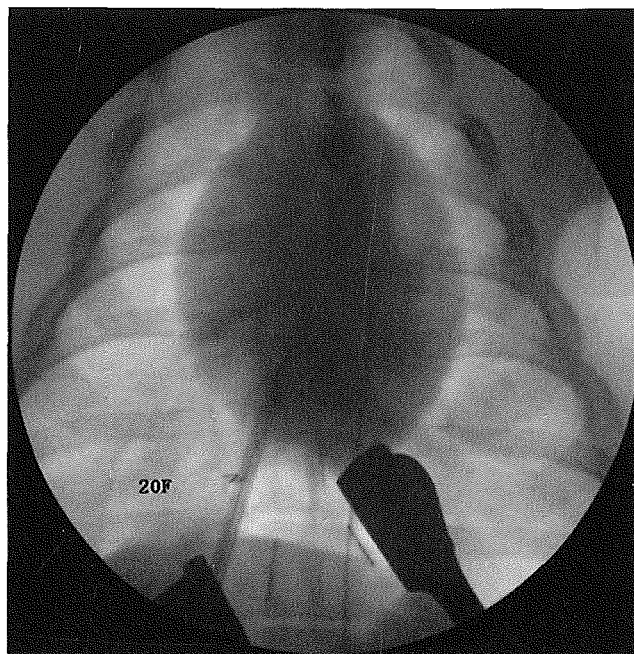


Fig. 3. Under fluoroscopy, the ventricular septal access was dilated with a 20 French dilator, by following the super stiff back-up guide wire.

reported as mean \pm SD. Paired Student's *t*-tests was used for comparison, where applicable, each animal being its own control.

3. Results

Procedural success of transventricular–transseptal TAVI was 100% (5/5 animals). Mean procedure time was 49 ± 4 min. Transventricular–transseptal access was straightforward and there was not much difficulty to deliver the guide wire crossing aortic annulus into the ascending aorta under fluoroscopy. By following the guide wire, the ventricular septal access was dilated progressively from 8F up to 26F (Fig. 3).

Under ICE, the manipulations for dilation were monitored and the ventricular septal access was evaluated each time. Obvious blood shunts between the left and right ventricle would not appear, until the septal accesses were dilated with the 18F and over-sized dilators (Fig. 4). The size of acquired ventricular septal defects (aVSD) was assessed at each step, following the guide wire with ICE.

The mean diameter of native aortic annulus in pigs was 21.9 ± 0.4 mm. All valved stents were delivered at the target site with good acute valve function. Likewise, the Amplatzer septal occluder devices were fully deployed and the ventricular septal accesses were sealed successfully (Figs. 5 and 6). All animals were in sinus rhythm before and after the transventricular–transseptal aortic valve implantation and device closure of the VSD. However, during the procedure, the following electro-mechanical events were recorded: atrial premature beat 5/5, ventricular premature beat 4/5, sino-tachyarrhythmia 5/5, ST segment elevation 1/5 and atrioventricular block 0/5. Likewise, the haemodynamics were relatively stable. The heart rate was

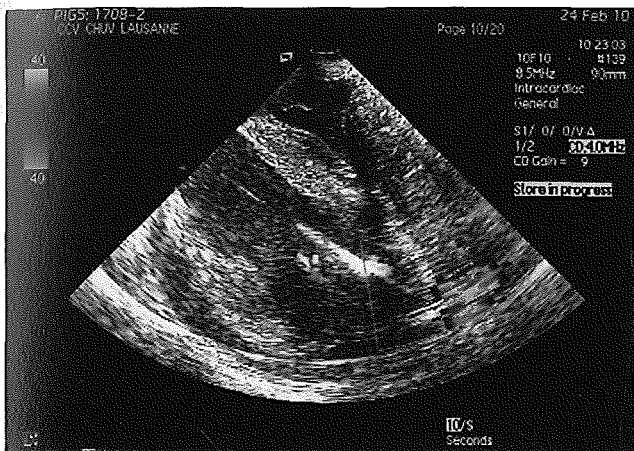

Fig. 4. After the ventricular septal access was dilated with 18F and oversized dilators, an obvious blood shunt from left ventricle to the right ventricle can be demonstrated with ICE and the colour-Doppler.

90 ± 3 beats min^{-1} before and 100 ± 2 beats min^{-1} after the procedure ($p < 0.05$), whereas the arterial pressure was assessed before (60 ± 1 mm Hg) and after the procedure (55 ± 2 mm Hg; $p < 0.05$).

No animal had significant regurgitation or paravalvular leak after implantation on ICE analysis. ICE demonstrated the complete opening and closing of the implanted valves. There were also no residual shunts detectable between the two ventricles after deployment of Amplatzer septal occluder device.

Macroscopic analysis of valved stents in the aortic position confirmed the adequate positioning within the defined landing zone, without left ventricular outflow tract obstruction and no damage to the ascending aorta or structural

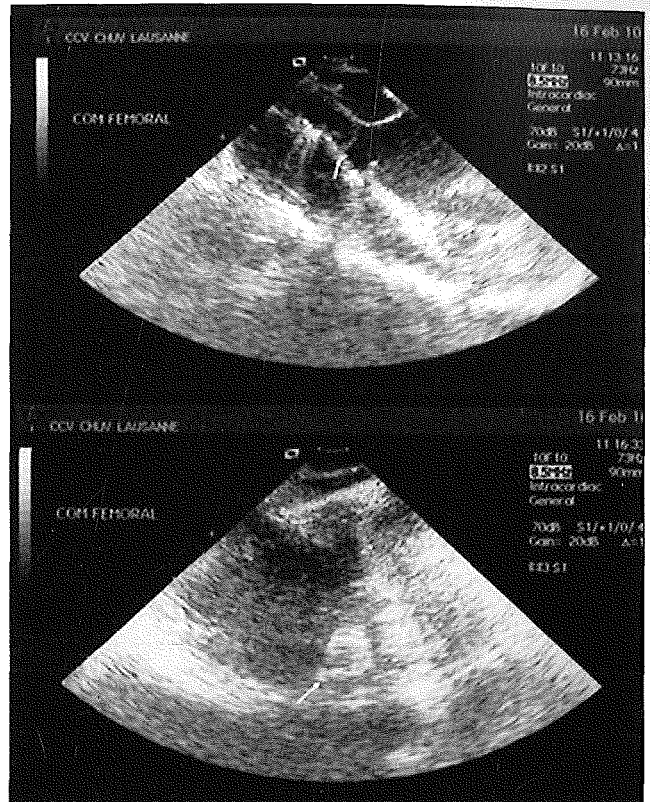


Fig. 6. Under ICE the valved stent was in aortic position with good function (A, indicated with an arrow). The Amplatzer septal occluder device was deployed in the accurate position, the ventricular septal access (B, the left disk of Amplatzer closure device in the left ventricle, indicated with an arrow).

defects of the valved stents was found at necropsy (Fig. 7). The ventricular septal access was closed completely by the Amplatzer septal occluder device, on gross visual examination (Fig. 7).

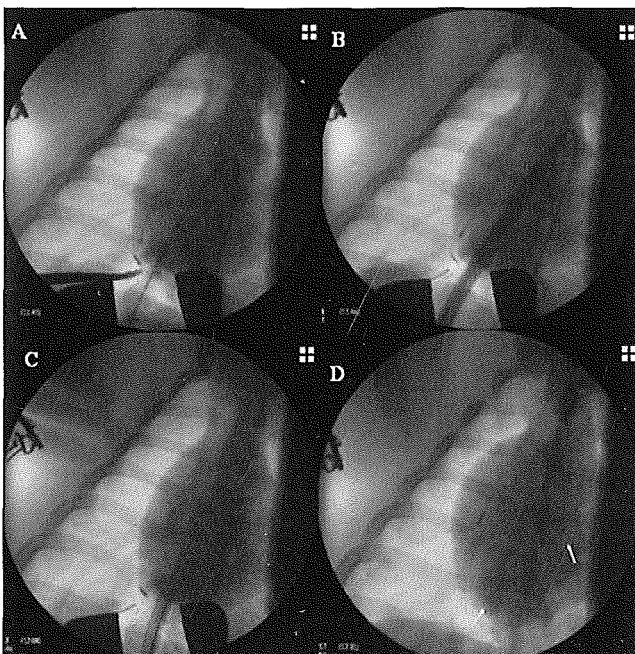


Fig. 5. Delivering the valved stent in the aortic annulus under the guidance of fluoroscopy (from A to C). The valved stent and ventricular septal occluder (D) were correctly positioned after deployment (indicated with arrows).

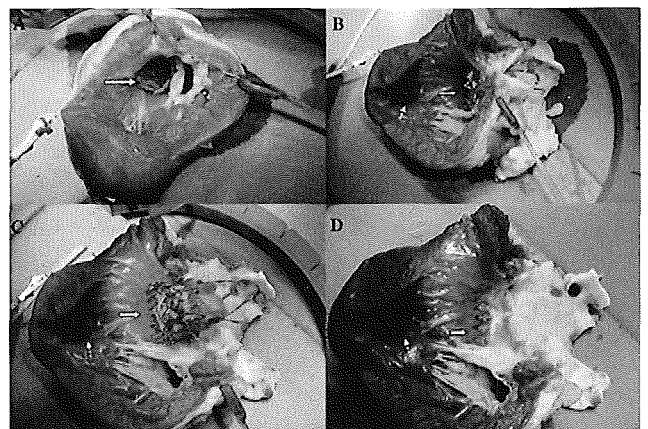


Fig. 7. At necropsy the valved stent was in the correct position (□), without displacement of anterior leaflet of mitral valve and the outflow tract of left ventricle was normal without obstruction (A, valved stent □; outflow tract of left ventricle →). No damage to the ascending aorta or structural defects of the valved stents was found at necropsy (B and C, valved stent □; Amplatzer closure device →). There were obvious fingerprints of stent after the valved stent was removed and confirmed again the valved stent was correctly positioned in the aortic annulus (D, fingerprints of the valved stent □; Amplatzer closure device →).

4. Discussion

The subxyphoid, transventricular–transseptal approach to the aortic root appears to be a promising new route for less invasive TAVI. Interestingly enough, only minor cardiac rhythm disturbances occurred during our experiments, although the porcine model is known for its arrhythmia and its fragile haemodynamics. As demonstrated previously, the left side of the heart is easily accessed through a subxyphoid incision in the pig [10,11]. Such situation occurs to a less extent in the clinical setting where mainly the diaphragmatic side of the right ventricle is exposed from this incision. We have successfully used the subxyphoid transventricular (RV) approach for clinical trans-catheter pulmonary valve implantation [9]. We were impressed by the ease of recovery and the fact that this procedure had been realised without opening of the pleural space and therefore it appeared that there was no need for either intubation or pleural drainage.

The subxyphoid approach is well known to cardiac surgeons not only for pericardial drainage [14], but also for implantation of epicardial pacemaker leads. Some of these procedures can also be realised with endoscopic techniques [15,16] which have also been demonstrated for trans-apical aortic valve implantation [6]. The most intriguing finding is, of course, that the subxyphoid route has also been used in awake patients for coronary artery bypass grafting in high risk patients [17], indeed very similar to the patients we have for TAVI.

Hence, our interest in a transventricular–transseptal route to the aortic root and TAVI, which may provide again a number of interesting advantages such as:

1. an extrapleural access;
2. no need for intubation;
3. no need for general anaesthesia; and
4. potential for NOTES (trans-umbilical access).

With the present study, we have been able to show, that technically, the transventricular–transseptal approach is not only feasible but also that the aortic root can be reached from the right ventricle in a reliable fashion and that the delivery of a clinical sized stent-valve can be achieved with good functional results.

Of course, trans-apical TAVI is still an excellent and technically mature procedure with rare local complications and satisfying mid-term follow-up results. All of these findings do not preclude the already established advantages of antegrade trans-apical TAVI including superior device performance (less compromise required for smaller introducer diameters required for peripheral access route), better implantation control (shorter delivery systems, relatively straight access), as well as lower risk of stroke, atrioventricular block and vascular complications as compared with peripheral retrograde routes.

Of course, there are also potential limitations for the transventricular–transseptal approach to the aortic root. These include the obviously necessary temporary VSD and its potential problems including:

1. to create transseptal access means increasing additional traumatic complications to the heart;

2. arrhythmias during the procedure;
3. haemodynamic consequences of a temporary VSD;
4. problems of device delivery due to suboptimal alignment;
5. feasibility of the device closure, and the reliability of the right ventricular access closure, which might add additional costs to the patients;
6. potential risk of residual VSD, etc.

As outlined above, and very much to our surprise, arrhythmias appeared not to be a problem in this experimental set-up, and also the temporary VSD appeared to be manageable. As a matter of fact, only the dilator sizes of 18F and more resulted in a detectable VSD during ICE. This is in line with the knowledge compiled from atrial transseptal procedures, where small atrial septal defects (ASDs) created for diagnostic and/or therapeutic purposes do usually not require closure devices [18]. In addition, we allowed here for a stabilisation period to assess the sizes/consequences of the VSDs between the dilators of increasing size, whereas for the clinical setting, we would certainly replace immediately each dilator with the next one and therefore allow between the steps only for minimal time period of shunting due to the VSD. Furthermore, one can expect some degree of septal hypertrophy in clinical cases with severe aortic stenosis, which, in turn, will induce a longer intraseptal route and therefore reduce the potential for shunting, correspondingly.

With regard to suboptimal device alignment due to the eccentric initial puncture, we did not, in fact, encounter any problem with device delivery, which was always smooth. Likewise, antegrade exploration of the aortic root with a soft J-type guide wire at the beginning of the procedure was straightforward. It may be of interest to revise the perceived impression, that the trans-apical route to the aortic root is perfectly straight. As a matter of fact, a quite significant angulation can occur as shown in Fig. 8, where the apical access spot and the aortic annulus look perfectly aligned in the antero-posterior projection, but the lateral view provides a very different reality. As a matter of fact, there is an angle of at least 60° in this patient with excellent outcome. Hence, a moderate angle of 30° or less, which is typically seen with the transventricular–transseptal route, appears not to be a problem and is of course much less than what is observed with the peripheral access routes where several curves occur, which may exceed 180°.

Therefore, transventricular–transseptal TAVI via a subxyphoidian access might have the following unique advantages:

- There is no manipulation within pleural space. Therefore, one can expect less interference with the respiratory system. This is especially suitable for patients with concomitant respiratory diseases and poor pulmonary function, or those who have received prior operations within the left thoracic cavity or on the left ventricle (such as, left ventricular aneurysmectomy), with severe pleural adhesions or pericardial adhesions, which can make exposure of the apex of the heart more difficult.
- It provides a possibility of TAVI under epidural and/or local anaesthesia without the requirement of intubation, which will further minimise invasiveness and benefit patients' rehabilitation.

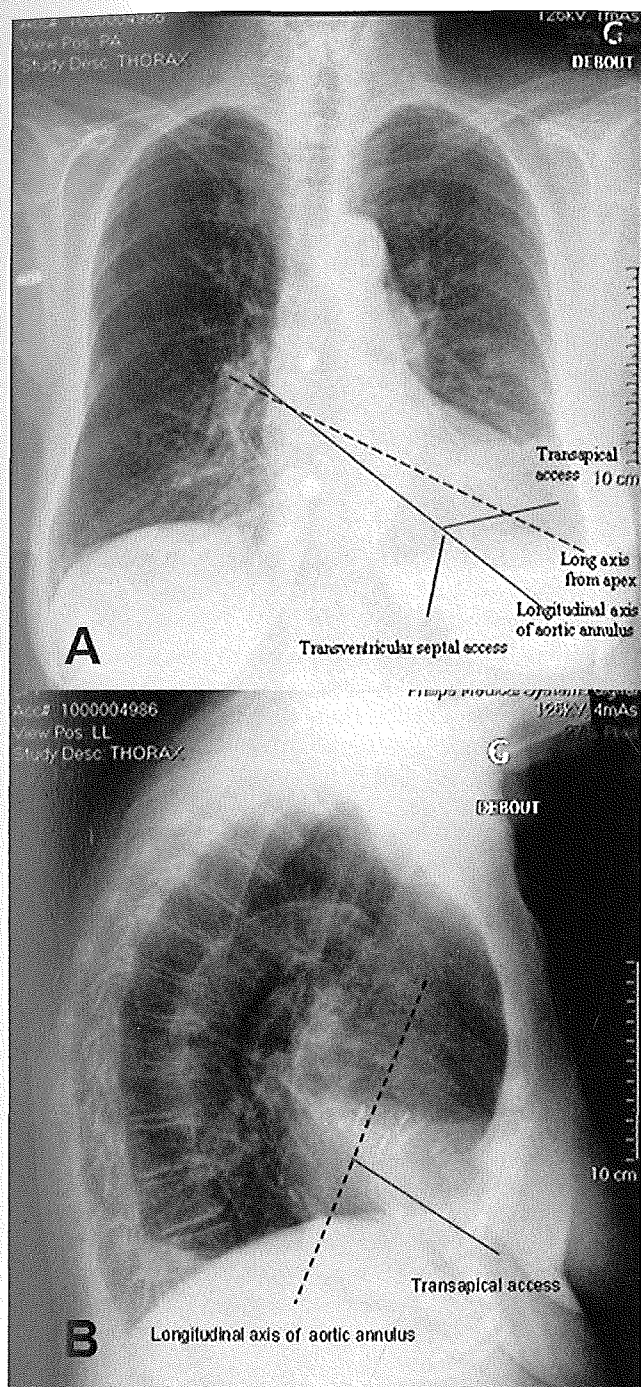


Fig. 8. Although an anterior-posterior chest view suggest an almost perfect alignment between the apical access and the aortic annulus, this is not necessarily true. As a matter of fact, the left lateral radiograph after trans-apical aortic valved stent implantation shows that the direction of trans-apical procedure is not parallel to the axis of aortic annulus and there is an obvious angle between them.

- By using the principle of NOTES in combination with the transventricular–transseptal access, an access route via the umbilicus is more feasible, provided closure tight devices become available.
- Easier to control bleeding from right ventricular access. The transventricular–transseptal access is on the right side of the heart with lower blood pressure, compared with

the left ventricle, which, in turn, makes closure easier not only with sutures, but also by the means of closure devices. In this experiment, no difficulties were encountered during closure of right ventricular access.

In short, transventricular–transseptal access for TAVI is a novel experimental exploration, which might enrich the routes for trans-catheter aortic valved stent implantation. Theoretically, it might be applied to those patients without indications for ‘traditional’ approaches (such as, transfermoral or trans-apical) TAVI. Considering the anatomic differences between human heart (patient’s diseased heart) and swine heart, further researches will be carried out before its possible clinical application.

Acknowledgement

We wish to thank Mr Marko Burki, and Mr Steven Taub sincerely, for their technical assistance received for and during the animal experiments, which contributed to the success of this work.

References

- [1] Vahanian A, Alfieri OR, Al-Attar N, Antunes MJ, Bax J, Cormier B, Cribier A, De Jaegere P, Fournial G, Kappetein AP, Kovac J, Ludgate S, Maisano F, Moat N, Mohr FW, Nataf P, Pierard L, Pomar JL, Schofer J, Tornos P, Tuzcu M, van Hout B, von Segesser LK, Walther T. Transcatheter valve implantation for patients with aortic stenosis: a position statement from the European Association of Cardio-Thoracic Surgery (EACTS) and the European Society of Cardiology (ESC), in collaboration with the European Association of Percutaneous Cardiovascular Interventions (EAPCI). *Eur J Cardiothorac Surg* 2008;34:1–8.
- [2] Zhou JQ, Corno AF, Huber CH, Tozzi P, von Segesser LK. Self-expandable valved stent of large size: off-bypass implantation in pulmonary position. *Eur J Cardiothorac Surg* 2003;24:212–6.
- [3] Huber CH, Tozzi P, Corno AF, Marty B, Ruchat P, Gersbach P, Nasratulla M, von Segesser LK. Do valved stents compromise coronary flow? *Eur J Cardiothorac Surg* 2004;25:754–9.
- [4] Walther T, Falk V, Borger MA, Kempfert J, Ender J, Linke A, Schuler G, Mohr FW. Transapical aortic valve implantation in patients requiring redo surgery. *Eur J Cardiothorac Surg* 2009;36:231–4.
- [5] Ferrari E, Sulzer C, Rizzo E, von Segesser LK. A fully echo-guided trans-apical aortic valve implantation. *Eur J Cardiothorac Surg* 2009;36:938–40.
- [6] Tozzi P, Pawelec-Wojtalik M, Bukowska D, Argitis V, von Segesser LK. Endoscopic off-pump aortic valve replacement: does the pericardial cuff improve the sutureless closure of left ventricular access? *Eur J Cardiothorac Surg* 2007;31:22–5.
- [7] Pawelec-Wojtalik M, Nożyński J, Wojtalik M, Piaszczyński M, Surmacz R, Bukowska D, Mrówczyński W. Is device closure for direct access valved stent implantation safe? *Eur J Cardiothorac Surg* 2006;30:4–9.
- [8] Von Segesser LK. Closure devices: the solution for repair of direct access apertures after valved stent implantation? *Eur J Cardiothorac Surg* 2006;30:2–3.
- [9] Ferrari E, Sulzer C, Rizzo E, von Segesser LK. Transcatheter stent-valve implantation in a stenotic pulmonary conduit via a sub-xyphoidian access. *Eur J Cardiothorac Surg* 2009;36:595–7.
- [10] Kalejs M, Ferrari E, von Segesser LK. Towards no-scar cardiac surgery – minimally invasive access through umbilicus for aortic valve replacement. *Eur J Cardiothorac Surg* 2009;36:773–5.
- [11] Marty B, Egger B. Editorial comment: access to the heart by a trans-umbilical incision. *Eur J Cardiothorac Surg* 2009;36:775.
- [12] Ma L, Tozzi P, Huber CH, Taub S, Gerelle G, von Segesser LK. Double-crowned valved stents for off-pump mitral valve replacement. *Eur J Cardiothorac Surg* 2005;28:194–8.
- [13] Vergnat M, Henaine R, Kalejs M, Bommeli S, Ferrari E, Obadia JF, Von Segesser LK. A new self-expanding aortic stent valve with annular fixation: in vitro haemodynamic assessment. *Eur J Cardiothorac Surg* 2009;35:970–5.

- [14] Ilabaca PA. Pleuropericardial window without thoracotomy: the subxyphoid approach. *J Tenn Med Assoc* 1984;77:454–5.
- [15] Manca G, Codecasa R, Valeri A, Braconi L, Giunti G, Tedone A, Perna AM, Stefano P, Gensini G. Totally endoscopic subxyphoid pericardiectomy: early steps with a new surgical tool. *Surg Endosc* 2009;23:444–6.
- [16] Ota T, Degani A, Zubiate B, Wolf A, Choset H, Schwartzman D, Zenati MA. Epicardial atrial ablation using a novel articulated robotic medical probe via a percutaneous subxyphoid approach. *Innovations Phila Pa* 2006;1:335–40.
- [17] Watanabe G, Yamaguchi S, Tomiya S, Ohtake H. Awake subxyphoid minimally invasive direct coronary artery bypass grafting yielded minimum invasive cardiac surgery for high risk patients. *Interact Cardiovasc Thorac Surg* 2008;7:910–2.
- [18] Ross Jr J. Transseptal left heart catheterization a 50-year odyssey. *J Am Coll Cardiol* 2008;51:2107–15.

Editorial comment

Why do it the easy way?

Keywords: Trans-apical; Aortic-valve implantation

With the event of trans-catheter aortic-valve implantation, the left-ventricular trans-apical access has gained renewed interest. While most studies report very few access-related complications, one recent study reports bleeding in 5% and formation of late pseudo-aneurysms in 6.6% of cases [1]. In rare cases (small ventricle, fragile tissue), rupture of the left-ventricular apex can occur and eventually lead to a fatal outcome [2]. It is therefore of interest to explore alternative direct cardiac access sites for aortic-valve implantation. The subxyphoid approach has been successfully used for single-port epicardial ablation of atrial fibrillation, and transabdominal, transdiaphragmatic endoscopic bypass grafting has been explored in an experimental setting [3].

In this issue, Liu et al. present a new method for subxyphoidal right-ventricular access for transseptal aortic-valve implantation [4]. While the authors have to be congratulated for their continuing and pioneering effort in developing devices to facilitate trans-apical aortic-valve implantation, this approach seems a little bit circumstantial. It is argued that opening the pleura can be avoided using a subxyphoidal approach and that general anesthesia may therefore no longer be needed. The requirement of general anesthesia for trans-apical aortic-valve implantation is continuously brought forward as a disadvantage when compared with the transfemoral access, which is now more often performed in local anesthesia. However, it has already been demonstrated that standard trans-apical aortic-valve implantation through the 5th or 6th left intercostal space can also be performed in the awake, spontaneously breathing patient using high epidural analgesia and despite pleural opening. However, there are other good reasons to favor general anesthesia in the setting of trans-catheter valve implantation. First, severe and life-threatening complications requiring cardiopulmonary bypass or cardiopulmonary resuscitation (CPR) can occur during the procedure at anytime. This can be managed more easily if the patient is already intubated.

Second, uncontrolled motion of the patient during valve deployment can unarguably lead to valve dislocation, a problem that can easily be avoided if the patient is asleep. Not general anesthesia itself, but prolonged ventilation is disadvantageous for the patient. Trans-catheter valve implantation should therefore go in hand with a fast-track anesthesia concept, applying short-acting anesthetics and early extubation.

The creation of an iatrogenic ventricular septal defect (VSD) is required for the proposed access. While this was successfully treated with the application of an Amplatzer occluder, the reasonableness of means can be put to question. Percutaneous closure of a VSD is associated with a relatively high risk of both peri-interventional and potential long-term complications. These include, but are not limited to, incomplete closure with residual shunt, the risk of device embolisation and migration, thromboembolic complications (pulmonary and systemic), hemolysis, arrhythmias and the risks associated with the need for anticoagulation are added to the procedure. Trans-catheter valve implantation is already expensive; the addition of devices to treat access-related collateral damage would further increase the economic burden.

For cases in whom standard aortic-valve replacement is truly not an option and neither the transfemoral, transsubclavian nor the trans-apical approach is feasible, a direct trans-aortic approach may be useful [5]. We must also accept that, even in 2010, some patients may be served best with no intervention at all.

References

- [1] Wong DR, Ye J, Cheung A, Webb JG, Carere RG, Lichtenstein SV. Technical considerations to avoid pitfalls during transapical aortic valve implantation. *J Thorac Cardiovasc Surg* 2010;140(1):196–202.
- [2] Al-Attar N, Ghodbane W, Himbert D, Rau C, Raffoul R, Messika-Zeitoun D, Brochet E, Vahanian A, Nataf P. Unexpected complications of transapical aortic valve implantation. *Ann Thorac Surg* 2009;88(July (1)):90–4.