

Advances in Treatment of Progressive Multifocal Leukoencephalopathy

Raphaël Bernard-Valnet, MD, PhD  ¹, Igor J. Koralnik, MD  ² and
Renaud Du Pasquier, MD ¹

Progressive multifocal encephalopathy (PML) is a severe demyelinating disease of the central nervous system (CNS) caused by JC virus (JCV), which occurs in immunocompromised individuals. Management of PML relies on restoration of immunity within the CNS. However, when this restoration cannot be readily achieved, PML has a grim prognosis. Innovative strategies have shown promise in promoting anti-JCV immune responses, and include T-cell adoptive transfer or immune checkpoint inhibitor therapies. Conversely, management of immune reconstitution inflammatory syndrome, particularly in iatrogenic PML, remains a major challenge. In this paper, we review recent development in the treatment of PML.

ANN NEUROL 2021;90:865–873

Progressive multifocal leukoencephalopathy (PML) is a rare and often fatal neurological disorder occurring in immunocompromised patients. It is due to reactivation of the polyomavirus JC (JC virus [JCV]), which causes lytic infection of oligodendrocytes and astrocytes in the central nervous system (CNS). Archetypic JCV transmission is thought to occur by person-to-person contact or contaminated food and water. It is thought that the virus spreads from oropharynx hematogenously to secondary sites such as bone marrow, lymphoid tissues, or kidneys. In healthy individuals, JCV establishes an asymptomatic persistent infection in the kidney, leading to its intermittent excretion in urine. Upon alteration of the cellular immune response, JCV may acquire mutations and gain the ability to infect the CNS.^{1,2}

PML was a rare condition mainly associated with hematological malignancies and transplant recipients until the onset of the acquired immune deficiency syndrome (AIDS) pandemic in the 1980s. PML occurred in 5% of patients with AIDS.³ Although AIDS remains the most

common etiology of PML throughout the world,^{4,5} the increased use of biological immunosuppressive/modulatory agents has contributed to a progressively larger proportion of cases. Some of those immunotherapies may trigger the onset of PML (eg, natalizumab, efalizumab fingolimod, dimethyl fumarate, rituximab, among others).^{4,6}

The initial clinical presentation of PML may include a large variety of neurological symptoms, like cognitive dysfunction, hemianopsia, aphasia, motor or sensory dysfunction, seizures, and ataxia, often with subacute progression.

Brain magnetic resonance imaging (MRI) typically shows T2-hyperintense and T1-hypointense lesions in the subcortical white matter of the brain or in cerebellar peduncles. A demyelination front may be observed on diffusion-weighted images. More recently, susceptibility-weighted imaging and positron emission tomography-computed tomography have been proposed as more sensitive techniques to discriminate PML from alternate diagnoses.⁷ Confirmation of the diagnosis is obtained by

View this article online at [wileyonlinelibrary.com](https://onlinelibrary.wiley.com/doi/10.1002/ana.26198). DOI: 10.1002/ana.26198

Received May 24, 2021, and in revised form Aug 9, 2021. Accepted for publication Aug 11, 2021.

Address correspondence to Dr Bernard-Valnet, Service of Neurology, Department of Clinical Neurosciences, Centre Hospitalier Universitaire Vaudois, Rue du Bugnon 46, 1011 Lausanne, Switzerland. E-mail: raphael.bernard-valnet@chuv.ch

From the ¹Service of Neurology, Department of Clinical Neurosciences, University Hospital of Lausanne and University of Lausanne, Lausanne, Switzerland; and ²Davee Department of Neurology, Northwestern University Feinberg School of Medicine, Chicago, IL, USA

Additional supporting information can be found in the online version of this article.

the detection of JCV DNA by polymerase chain reaction in the cerebrospinal fluid (CSF) or in brain biopsy tissue. In the latter, JCV proteins can be identified by immunohistochemistry and contribute to diagnosis of PML.⁸

In addition to classical PML, JCV infection has been associated with other clinical presentations, including JCV granule cell neuronopathy, JCV meningitis, and JCV encephalopathy.⁶

Medications with potential antiviral properties against JCV in vitro such as mirtazapine or mefloquine did not show efficacy in PML patients.⁹ Thus, the mainstay of therapy aims at restoring an immunity sufficient to keep JCV in check. Such restoration of immunity is achieved with antiretroviral therapy in the case of AIDS-associated PML or by attempting to withdraw immunosuppressive therapies in PML arising in patients treated for autoimmune diseases or cancers.

However, such improved immunity may lead to an immune reaction known as immune reconstitution inflammatory syndrome (IRIS). IRIS may cause a paradoxical neurological worsening in a patient whose immune system had started to recover.¹⁰ On MRI, PML-IRIS is characterized by gadolinium enhancement of PML lesions, and can be associated with edema and mass effect, which are not features of classical PML.

Despite improvements in the prognosis, treatment of PML remains a challenge. Here, we will review innovative therapies that have been tested recently. We will cover the recent literature related to the management of PML and PML-IRIS with a special focus on treatments and prevention strategies (Fig).

Search Strategy and Selection Criteria

Articles for this review were identified by search on PubMed and Web of Science for all references in English published from January 1, 2010, to June 28, 2021, using the terms (or combinations of these terms) “PML”, “progressive multifocal leukoencephalopathy”, “JCV”, “human polyomavirus”, “IRIS”, “immune reconstitution inflammatory syndrome”, “inflammatory PML”, “nivolumab PML”, “pembrolizumab PML”, “checkpoint inhibitors PML”, “interleukin-7 PML”, and “maraviroc PML”. Older papers were also selected from authors’ personal files. The final reference list was generated based on relevance for this review topic and to provide readership a comprehensive overview.

Immunological Mechanisms Underlying PML Infection

Potential therapies for PML are predicated on the fine interplay between JCV and the immune system. JCV infection cycle has been described in detail previously.^{1,2}

Because a majority of healthy individuals harbor JCV in their kidneys and remain asymptomatic throughout their lives, the containment of JCV seems to rest mostly on the cellular immune response, mediated by T lymphocytes. PML occurs in patients with AIDS who have CD4⁺ T cells lymphopenia, as well as in patients with idiopathic CD4⁺ or CD8⁺ T cells lymphopenia. PML may also be caused by the reduction of immune surveillance within the CNS, which takes place in natalizumab-treated patients.^{11,12} Natalizumab is a monoclonal antibody directed against $\alpha 4$ integrin, resulting in prevention of transmigration of nucleated blood cells, especially CD4⁺ T cells, into the CNS. Yet, CD4⁺ T cells are important in the clearance of JCV from PML lesions, where they produce interferon- γ (IFN γ) and interleukin (IL)-4, cytokines that may play a crucial role for viral clearance.¹³ Thus, absence of clearance of JCV in some patients is linked to impaired CD4⁺ T-cell responses in the CNS and a lack of IFN γ production.¹⁴ Furthermore, even if the CD4⁺ T-cell responses are increased in natalizumab-treated patients¹⁵, this response seems to be dysfunctional with the production of the anti-inflammatory cytokine IL-10.¹⁶ Further supporting the importance of JCV-specific CD4⁺ T cells in containing PML, the presence of those cells correlates with a favorable outcome in AIDS-PML patients.¹⁷

CD8⁺ T cells are the major effectors of cellular immune response against viruses.^{18,19} Most cells of the CNS are able to express class I major histocompatibility complex, and thus may present viral antigens to cytotoxic CD8⁺ T cells. Healthy individuals harbor JCV-specific CD8⁺ T cells that may control the latent form of the infection.²⁰ Furthermore, the presence of JCV-specific CD8⁺ cytotoxic T cells in peripheral blood has been associated with a better outcome of PML.^{21,22} Similarly to CD4⁺ T cells, CD8⁺ T-cell migration into the CNS is blocked by natalizumab.²³ Brain biopsies of PML and PML-IRIS patients show a prominent CD8⁺ T-cell infiltration at the edges of lesions.^{24,25} CD8⁺ T cells in close contact with JCV-infected CNS cells exhibit granzyme B polarization, suggesting cytotoxic activity against the virus. Most of these CD8⁺ T cells harbor the tissue homing marker CCR5, which is a key chemokine receptor involved in viral responses within the CNS.^{18,26}

Another aspect of the cellular immune response that is a factor in the immunopathogenesis of PML is T-cell exhaustion. Exhaustion is a state of T-cell dysfunction that can develop during chronic infections, sepsis, and cancer. Exhausted T cells are characterized by upregulation of immune checkpoint molecules (Programmed cell Death protein 1 [PD-1], cytotoxic T-lymphocyte-associated protein 4 [CTLA-4]) and reduced immune responses to pathogens.²⁷ A high expression of PD-1 on T cells, especially at the surface of JCV-specific CD8⁺ T cells, can be seen

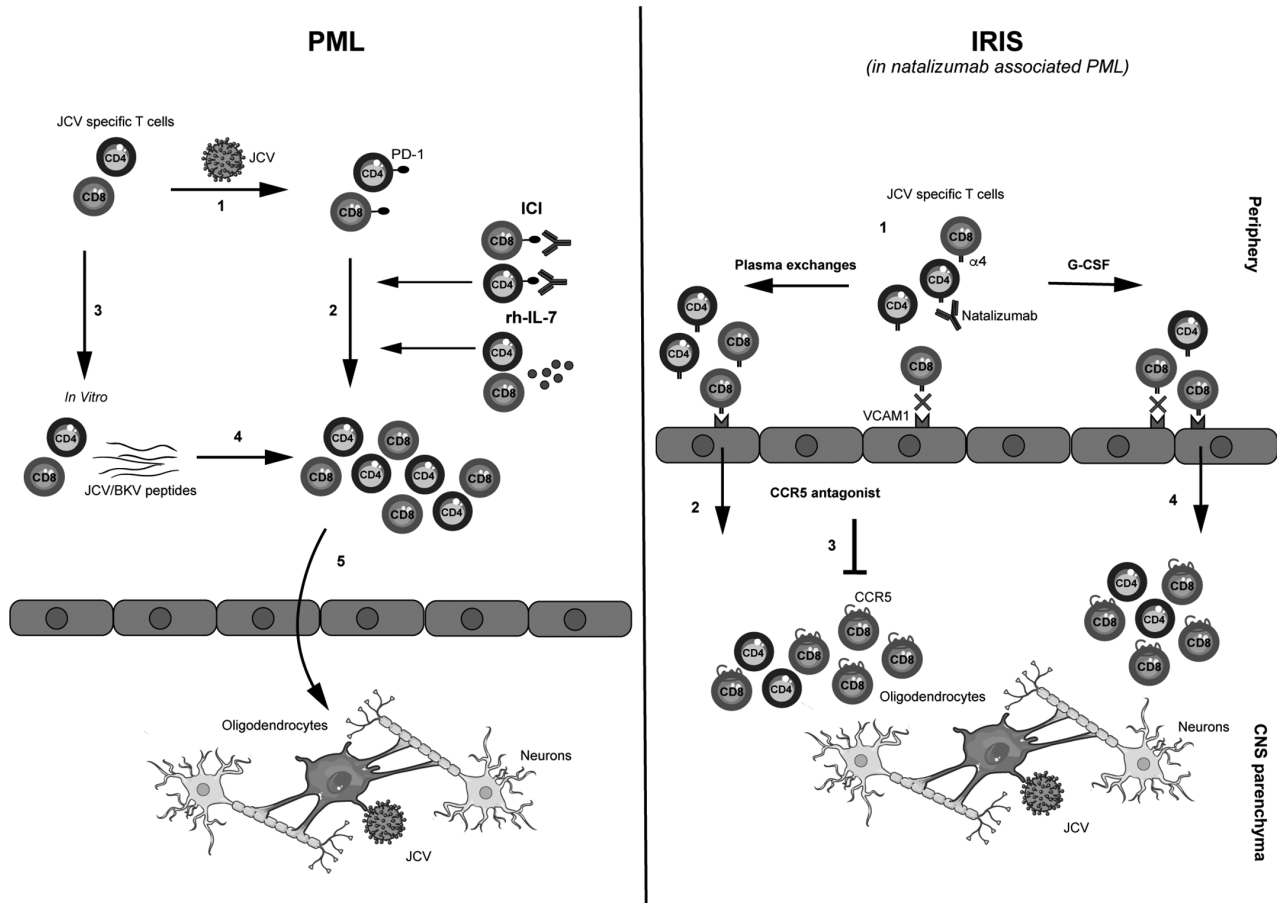


FIGURE: Mode of action of progressive multifocal encephalopathy (PML) and immune reconstitution inflammatory syndrome (IRIS) treatments. Left panel: In a patient with immunocompromised condition, JC virus (JCV)-specific T-cell pool is reduced and their level of exhaustion (characterized by Programmed cell Death protein 1 [PD-1] upregulation) is increased (1). Immune checkpoint inhibitors (ICIs) or recombinant human interleukin 7 (rh-IL-7) are used to foster JCV-specific T-cell proliferation and effector function (2). Alternatively, JCV-specific T cells may be purified from human leukocyte antigen-matched healthy donors (3) and expanded in vitro with JCV or BK virus (BKV) peptides before adoptive transfer (4). This increase of competent JCV-specific T-cell pool allows a reconstitution of the immune surveillance of the central nervous system (CNS; 5). Right panel: In natalizumab-associated PML, the blockade of $\alpha 4$ integrin expressed by T cells prevents those cells from entering the CNS, as they are unable to bind vascular cell adhesion molecule 1 (VCAM-1) at the surface of the blood-brain barrier (1). Upon natalizumab withdrawal (including prompt removal through plasma exchange), abrupt restoration of anti-JCV immunity occurs. This massive infiltration by JCV-specific T cells triggers an unregulated and potentially harmful immune response within CNS parenchyma, called IRIS (2). This infiltration is dominated by $CD8^+$ T cells harboring the CCR5 tissue homing marker (represented by a red receptor at cell surface). Thus, CCR5 agonist may theoretically be used to prevent massive influx of T cells and IRIS (3). Alternatively, granulocyte-colony-stimulating factor (G-CSF) has been proposed to induce immune reconstitution and CNS migration through pathways independent of $\alpha 4$ /VCAM-1 interaction (4). [Color figure can be viewed at www.annalsofneurology.org]

in PML patients, suggesting that T-cell exhaustion may play a role in the development of PML.²⁸ Consistent with this observation, a multiple sclerosis (MS) patient on dimethyl fumarate developed PML despite a normal T-cell count, albeit with evidence of T-cell exhaustion.²⁹

Restoration of Immunity as a Treatment for PML

The best way to control JCV infection is to restore the cellular immune response. In AIDS-related PML, introduction of antiretroviral therapy (ART) is instrumental in reconstituting the cellular immune response and thus

improving PML prognosis. However, in several other PML-predisposing conditions, such as hematological malignancies, organ transplant recipients, and idiopathic immune deficits, an immune reconstitution cannot be achieved readily. Unsurprisingly, these conditions are associated with a poor prognosis. Nevertheless, many strategies aiming at reinvigorating the cellular immune response have been recently developed.^{30,31}

Immune Checkpoint Inhibitors

Immune checkpoint inhibitors (ICIs), usually restricted to cancer treatment, have been used to strengthen JCV-

specific cellular immune responses in the hope of improving PML outcome. The indication for such treatment is to shift JCV-specific T cells from an exhausted phenotype to an activated one, and thus stimulate expansion of effector lymphocytes. The rationale rests on data showing a high expression of immune checkpoint molecules at the surface of CD4⁺ and CD8⁺ T cells in the blood and CSF of PML patients and the possibility to increase, in vitro, the cellular immune response against JCV by PD-1 blocking.^{28,32}

Table (detailed in Supplementary Table 1) summarizes published studies using the anti-PD-1 antibodies nivolumab and pembrolizumab in PML patients.³²⁻⁵⁰

Anti-PD-1 therapies have shown promising results in some cases, with documented clinical and radiological benefit. In these patients, nivolumab or pembrolizumab seem to have triggered an effector response mediated by JCV-specific CD4⁺ and CD8⁺ T cells,^{32,34} as well as immune reconstitution demonstrable on brain biopsy³⁶ and clearance of the virus in the CSF.^{32,34,35}

However, PD-1 blockers have a mixed track record in the treatment of PML in patients with refractory immunosuppression. In 48% of the patients (11/31), those drugs

showed no or minimal benefit. In such cases, it seems that the immunosuppression was too severe, with very low numbers of JCV-specific CD4⁺ T cells and limited expansion of this population despite effective PD-1 downregulation on their surface.^{32,39} Thus, the amount of JCV-specific CD4⁺ T cells may serve as predictor of an effective response to anti-PD-1. These results are in line with AIDS-related PML, where JCV-specific CD4⁺ T-lymphocyte response is associated with prolonged survival.¹⁷

In addition to the number of JCV-specific T cells, their level of exhaustion may also predict the response to ICIs. In one case of PML with fatal outcome despite ICI treatment, most JCV CD8⁺ T cells exhibited “terminally exhausted” phenotype.³⁹ Interestingly, such “terminally exhausted” CD8⁺ T cells have been shown not to respond to anti-PD-1 therapy in melanoma.⁵¹

ICIs are frequently associated with immune-related adverse events such as colitis or pneumonitis.⁵² However, in ICI-treated PML patients, adverse events were rare and mostly mild. Furthermore, clinical worsening caused by IRIS occurred in only 2 of 37 cases.³⁶ This low rate of immune-related adverse events could probably be explained by the severe immunodeficiency of PML patients.

TABLE. Outcome of treatments aiming at restoring anti-JC virus immunity.

Treatment	Reported cases	Associated condition(s)	Protocol	Outcome	Adverse events
Immune checkpoint inhibitors (ICI)	37	20 hematological malignancies (54%) 8 immune deficits (21,6%) 3 autoimmune diseases (8%) 3 solid organ transplant (8%) 2 HIV (5%) 1 none (3%)	Pembrolizumab: 25 (67%) Nivolumab: 12 (33%)	Favorable: 10 (27%) Stable: 10 (27%) Worsening: 17 (46%), including 14 (38%) who died of PML	2 IRIS 2 myositis 2 colitis 1 polymyositis flare 1 psoriatic rash
JCV/BKV specific T cells Transfer	28	1 GVHD (3.6%) 16 hematological malignancies (57%) 1 HIV (3.6%) 7 immune deficits (25 %) 1 solid organ transplant (3.6%) 2 autoimmune diseases (7%)	JCV specific T cells: 23 (82%) BKV specific T cells: 5 (18 %)	Favorable: 10 (36%) Stable: 9 (32%) Worsening: 9 (32%), Including 8 (29%) who died of PML	1 IRIS

BKV = BK virus, GVHD = Graft versus host disease, HIV = human immunodeficiency virus, IRIS = immune reconstitution inflammatory syndrome, JCV = JC virus, PML = progressive multifocal leukoencephalopathy.

To date, data on treatment of PML patients with PD-1 blockers are limited to case reports or small case series. Large multicenter studies using clinical, biological, and radiological endpoints are needed to assess treatment efficacy and to better identify responders.

Given the limited efficacy and the potential immune-related adverse events, the use of ICIs should not be considered a first-line therapy in PML cases where immune reconstitution may be readily achieved through ART in human immunodeficiency virus (HIV)-infected patients or discontinuation of immunotherapies in patients with MS.

Interleukins

Human recombinant cytokines have been used to boost effector T-cell responses against JCV. First attempts used IL-2 to foster the reconstitution of CD4⁺ T cells. However, this strategy showed no clinical or biological efficacy.⁵³

IL-7 is a pivotal cytokine in T-cell biology. IL-7 stimulates thymic differentiation and homeostatic expansion of naïve peripheral T cells. It also plays a role in memory T-cell survival and proliferation and decreases the expression of PD1 inhibitory molecule on T cells. Finally, IL-7 has been shown to increase the antigen-specific responses (mainly CD8⁺ T cell mediated) after viral infection or vaccination.⁵⁴

Recombinant human IL-7 (rhIL-7) has been used in a limited number of patients suffering from immune deficit-related PML, with encouraging outcomes.^{55–58} rhIL-7 increased the number of CD4⁺ T cells and JCV-specific T-cell responses. However, rhIL-7 therapy was also associated with severe IRIS.^{57,58}

Finally, IL-15, a superagonist known to stimulate natural killer cells and CD8⁺ T cells, may favor viral clearance and improve PML prognosis.⁵⁹

Polyomavirus-Specific Allogenic T-Cell Transplantation

Another strategy consists of adoptive transfer of human leukocyte antigen (HLA)-matched JCV-specific T cells in PML patients. Such JCV- or BK virus (BKV)-specific T cells (BKV shares several immunogenic peptides with JCV) are drawn from healthy donors, expanded in vitro, and stimulated in the presence of JCV (or BKV) peptides. These expanded cells, which are then transferred in HLA-matched PML patients, are found in the CSF and able to control JCV replication.

To date, 28 patients with hematological neoplasia, immune deficit, or organ transplant were treated with this approach (Table). Among those, 19 of 28 (68%) achieved containment of PML and had long-term survival. Some patients had rapid and marked reduction of JCV load in

the CSF and lack of radiological progression of the disease. Only one patient experienced mild IRIS, and none had transplantation-related adverse events.^{60–65} Thus, allogenic T-cell transfer appears to be a promising therapeutic strategy in PML related to refractory immunosuppression. However, virus-specific T-cell allogenic transfer requires an infrastructure and a technical expertise that are available at only few centers.

Neutralizing Antibodies/Vaccination against JCV

The identification of neutralizing JCV-specific antibodies in the CSF of patients who recovered from PML may pave the way for a humoral-based therapy. However, passive immunization strategies have not been tested in patients. Intravenous immunoglobulin administration early in the course of PML could be considered,⁶⁶ as healthy individuals display JCV-neutralizing antibodies.⁶⁷

Active immunization with JCV VP1-virus-like particles, associated with rhIL-7 and topically administered Toll-like receptor 7 agonist (imiquimod) as adjuvant, was tested in 3 patients who were severely immunocompromised and led to PML stabilization and decrease in JC viral load in the CSF. This clinical outcome was related to inflammatory signs on MRI and expansion of both T cells and humoral responses.^{55,67}

Risk Mitigation and Treatment Strategies in Iatrogenic PML

Numerous and highly efficacious immunomodulatory therapies have recently become available for treatment of a variety of autoimmune conditions. However, these therapies can significantly impair antiviral immune surveillance. Several of them have been associated with an increased occurrence of PML. Those include natalizumab, efalizumab, fingolimod, and dimethyl fumarate.

Risk Mitigation with Natalizumab

As of February 1, 2021, natalizumab has been associated with 853 cases of PML since 2006 and has an overall incidence of PML of 3.86/1,000 patients. However, risk mitigation strategies have been implemented using JCV serological testing (JCV index).¹ This risk stratification strategy helped lower the incidence of natalizumab-associated PML by 23%.⁶⁸

Extended interval dosing (EID) is another strategy recently developed to reduce the incidence of natalizumab-related PML. This approach relies on the observation, in a large Natalizumab-treated patient registry, that infusions every 5 to 6 weeks instead of every 4 weeks (standard regimen) was leading to a reduction of about 90% of PML incidence.⁶⁹ Retrospective studies and prospective data on small

sample sizes suggest that EID does not impact MS treatment efficacy.^{70–72}

The mechanisms underlying this reduction remain unclear. However, we suggest that reduction of $\alpha 4$ saturation may increase immune surveillance in the CNS.

Interestingly, a recent series of 4 cases suggests that PML occurring despite EID is less severe, characterized by a long minimally symptomatic phase and a low JCV CSF viral load at diagnosis.⁷³

Plasma Exchanges

Despite risk mitigation strategies, natalizumab-associated PML remains a therapeutic challenge. In the early days of natalizumab-associated PML, plasma exchange (PLEX) has been advocated with the goal of removing natalizumab from the bloodstream and allowing the CNS migration of activated lymphocytes, thus hastening immune reconstitution. However, this method caused a massive and sudden influx of lymphocytes into the brain and was associated with the occurrence of IRIS in most cases.⁷⁴ Thus, PLEX could accelerate and worsen the onset of IRIS. In 2 retrospective Italian studies, PLEX was not associated with increased survival or better clinical outcome of PML, but with longer IRIS duration.^{75,76} These results were confirmed by a larger retrospective study (>700 cases), based on the Biogen safety database.⁷⁷

Granulocyte-Colony-Stimulating Factor

In an attempt to boost the JCV-specific immune response within the CNS in natalizumab-associated PML, a pilot study tested an approach using granulocyte-colony-stimulating factor (G-CSF).⁷⁸ G-CSF is a growth factor widely used after chemotherapy that prompts neutrophil and lymphocyte recovery. G-CSF increases CNS migration properties of T cells through pathways that are not impacted by natalizumab. Thus, G-CSF may prompt effector T-cell responses in the CNS and achieve faster immune recovery.

Upon G-CSF treatment, 15 of 17 natalizumab-PML patients developed IRIS within a mean of 57.4 days after the last natalizumab infusion. Seven patients (41%) recovered to or near baseline. There were no PML/IRIS-related fatalities, and PLEX had no impact on PML outcome.⁷⁸ Thus, G-CSF may be a new strategy to treat natalizumab-associated PML, but further prospective studies including a control group are needed to better appraise its benefit.

Prevention and Treatment of IRIS

Although restoring immunity is a major goal of PML treatment, IRIS may be a harmful side effect and lead to sustained disability. Thus, the management of PML consists of a fine balance between restoring CNS T-cell

responses and preventing deleterious inflammation within the brain.

Corticosteroids have been widely used to treat IRIS and achieve control of excessive immune response and edema that develop around PML lesions.⁷⁹ However, one recent study suggested that corticosteroids may play a detrimental role in treatment of natalizumab-associated IRIS.⁷⁶ The timing of use of corticosteroids may explain some of these discrepancies.

Corticosteroids should be reserved for patients presenting a marked neurologic worsening caused by PML-IRIS, and those who have clinical or radiological signs suggesting brain/cerebellum herniation.

CCR5 Agonists

Given the questionable impact of steroids in PML-IRIS, the CCR5 chemokine receptor antagonist maraviroc has been used as a potential alternative/additional treatment. CCR5 is a key homing molecule for T cells and, in the context of PML-IRIS, favors their migration into the CNS.⁸⁰ Maraviroc has initially been developed to block HIV entrance into CD4⁺ T cells.⁸⁰ Two case reports, one in AIDS-PML and the other in natalizumab-PML, suggested that maraviroc was efficient at limiting IRIS.^{81,82} However, these data have not been confirmed by case series of iatrogenic PML.^{83,84} A larger retrospective study is ongoing and may contribute to better understanding of the role of maraviroc in PML-IRIS.

In HIV-infected patients, ART including maraviroc was not efficient at preventing PML-IRIS.⁸⁵ Furthermore, in 2 randomized studies, maraviroc failed to prevent IRIS observed in the context of ART introduction.^{86,87} Further studies are needed to determine the role of maraviroc in PML-IRIS.

Conclusions

In the past 2 decades, there has been an increased incidence of PML occurring in the context of a wider use of immunotherapies.⁴ Despite a better understanding of the mechanisms underlying JCV infection, the management of PML remains a major challenge for clinicians.

Treatment of PML relies on a fine balance between enhancement of JCV-specific effector T-cell responses and prevention of deleterious IRIS. Over the past 20 years, several potential antiviral treatments, including mirtazapine, mefloquine, cytarabine, and cidofovir, were tested, with disappointing results. The past 2 years have been marked by the development of innovative and targeted therapies aimed at restoring JCV-specific immunity or preventing/treating IRIS. However, due to the infrequent occurrence of PML, and the various etiologies of this disease, it has remained difficult to determine the

exact contribution of these emerging treatments. Most evaluations consist of limited case reports/series. If these limitations are inherent to orphan diseases, combined efforts in international initiatives are needed to evaluate these treatments on larger cohorts of patients.⁹

Furthermore, prevention and early detection of PML are important measures to reduce PML-associated morbidity and mortality. In this regard, natalizumab-associated PML is a model where implementation of several risk-lowering strategies proved efficient.⁶⁸

Successful management and research on PML will require continuous multidisciplinary effort, including neurologists, infectious disease, hematology, and transplantation specialists, and basic scientists, to establish standard of care for PML and PML-IRIS.

Acknowledgment

Open access funding provided by Universite de Lausanne.

Author Contributions

All authors contributed to conception and design of the review, interpretation of studies included in the review, and drafting the text; R.B.-V. contributed to preparing the figure.

Potential Conflicts of Interest

R.B.-V. has nothing to report. I.J.K. has received royalties for PML chapters in UpToDate. R.D.P. has served on scientific advisory boards discussing iatrogenic PML in the context of MS for Biogen, Celgene, and Novartis.

References

- Major EO, Yousry TA, Clifford DB. Pathogenesis of progressive multifocal leukoencephalopathy and risks associated with treatments for multiple sclerosis: a decade of lessons learned. *Lancet Neurol* 2018;17:467–480.
- Cortese I, Reich DS, Nath A. Progressive multifocal leukoencephalopathy and the spectrum of JC virus-related disease. *Nat Rev Neurol* 2021;17:37–51.
- Holman RC, Janssen RS, Buehler JW, et al. Epidemiology of progressive multifocal leukoencephalopathy in the United States: analysis of national mortality and AIDS surveillance data. *Neurology* 1991;41:1733–1736.
- Iacobaeus E, Burkill S, Bahmanyar S, et al. The national incidence of PML in Sweden, 1988–2013. *Neurology* 2018;90:e498–e506.
- Anand P, Hotan GC, Vogel A, et al. Progressive multifocal leukoencephalopathy: a 25-year retrospective cohort study. *Neurol Neuroimmunol Neuroinflamm* 2019;6:e618.
- Tan CS, Koralnik IJ. Progressive multifocal leukoencephalopathy and other disorders caused by JC virus: clinical features and pathogenesis. *Lancet Neurol* 2010;9:425–437.
- Mahler C, Schumacher A-M, Unterrainer M, et al. TSPO PET imaging of natalizumab-associated progressive multifocal leukoencephalopathy. *Brain*. 2021. <https://doi.org/10.1093/brain/awab127>
- Berger JR, Aksamit AJ, Clifford DB, et al. PML diagnostic criteria: consensus statement from the AAN neuroinfectious disease section. *Neurology* 2013;80:1430–1438.
- Clifford DB, Nath A, Cinque P, et al. A study of mefloquine treatment for progressive multifocal leukoencephalopathy: results and exploration of predictors of PML outcomes. *J Neurovirol* 2013;19:351–358.
- Martin-Blondel G, Delobel P, Blancher A, et al. Pathogenesis of the immune reconstitution inflammatory syndrome affecting the central nervous system in patients infected with HIV. *Brain* 2011;134:928–946.
- Aggarwal D, Tom JP, Chatterjee D, Goyal M. Progressive multifocal leukoencephalopathy in idiopathic CD4+ lymphocytopenia: a case report and review of literature. *Neuropathology* 2019;39:467–473.
- Stüve O, Marra CM, Jerome KR, et al. Immune surveillance in multiple sclerosis patients treated with natalizumab. *Ann Neurol* 2006;59:743–747.
- Aly L, Yousef S, Schippling S, et al. Central role of JC virus-specific CD4+ lymphocytes in progressive multi-focal leukoencephalopathy-immune reconstitution inflammatory syndrome. *Brain* 2011;134:2687–2702.
- Jelic I, Jelic I, Kempf C, et al. Mechanisms of immune escape in central nervous system infection with neurotropic JC virus variant. *Ann Neurol* 2016;79:404–418.
- Jilek S, Jaquière E, Hirsch HH, et al. Immune responses to JC virus in patients with multiple sclerosis treated with natalizumab: a cross-sectional and longitudinal study. *Lancet Neurol* 2010;9:264–272.
- Perkins MR, Ryschkeiwitsch C, Liebner JC, et al. Changes in JC virus-specific T cell responses during natalizumab treatment and in natalizumab-associated progressive multifocal leukoencephalopathy. *PLoS Pathog* 2012;8:e1003014.
- Gasnault J, Kahraman M, De Herve MGDG, et al. Critical role of JC virus-specific CD4 T-cell responses in preventing progressive multifocal leukoencephalopathy. *AIDS* 2003;17:1443–1449.
- Korn T, Kallies A. T cell responses in the central nervous system. *Nat Rev Immunol* 2017;17:179–194.
- Yshii L, Gebauer C, Bernard-Valnet R, Liblau R. Neurons and T cells: understanding this interaction for inflammatory neurological diseases. *Eur J Immunol* 2015;45:2712–2720.
- Du Pasquier RA, Schmitz JE, Jean-Jacques J, et al. Detection of JC virus-specific cytotoxic T lymphocytes in healthy individuals. *J Virol* 2004;78:10206–10210.
- Du Pasquier RA, Kuroda MJ, Zheng Y, et al. A prospective study demonstrates an association between JC virus-specific cytotoxic T lymphocytes and the early control of progressive multifocal leukoencephalopathy. *Brain* 2004;127:1970–1978.
- Gheuens S, Bord E, Kesari S, et al. Role of CD4+ and CD8+ T-cell responses against JC virus in the outcome of patients with progressive multifocal leukoencephalopathy (PML) and PML with immune reconstitution inflammatory syndrome. *J Virol* 2011;85:7256–7263.
- Martin-Blondel G, Pignolet B, Tietz S, et al. Migration of encephalitogenic CD8 T cells into the central nervous system is dependent on the $\alpha 4\beta 1$ -integrin. *Eur J Immunol* 2015;45:3302–3312.
- Martin-Blondel G, Bauer J, Cuvincius V, et al. In situ evidence of JC virus control by CD8+ T cells in PML-IRIS during HIV infection. *Neurology* 2013;81:964–970.
- Wüthrich C, Kesari S, Kim WK, et al. Characterization of lymphocytic infiltrates in progressive multifocal leukoencephalopathy: co-localization of CD8+T cells with JCV-infected glial cells. *J Neurovirol* 2006;12:116–128.
- Martin-Blondel G, Bauer J, Uro-Coste E, et al. Therapeutic use of CCR5 antagonists is supported by strong expression of CCR5 on

- CD8+ T cells in progressive multifocal leukoencephalopathy-associated immune reconstitution inflammatory syndrome. *Acta Neuropathol* 2015;129:463–465.
27. Wykes MN, Lewin SR. Immune checkpoint blockade in infectious diseases. *Nat Rev Immunol* 2018;18:91–104.
 28. Tan CS, Bord E, Broge TA, et al. Increased program cell death-1 expression on T lymphocytes of patients with progressive multifocal leukoencephalopathy. *J Acquir Immune Defic Syndr* 2012;60:244–248.
 29. Garcia J, Hendel-Chavez H, De-Goer MG, et al. Progressive multifocal leukoencephalopathy on dimethyl fumarate with preserved lymphocyte count but deep T-cells exhaustion. *Mult Scler* 2021;27:640–644.
 30. Neil EC, DeAngelis LM. Progressive multifocal leukoencephalopathy and hematologic malignancies: a single cancer center retrospective review. *Blood Adv* 2017;1:2041–2045.
 31. Mateen FJ, Muralidharan R, Carone M, et al. Progressive multifocal leukoencephalopathy in transplant recipients. *Ann Neurol* 2011;70:305–322.
 32. Cortese I, Muranski P, Enose-Akahata Y, et al. Pembrolizumab treatment for progressive multifocal leukoencephalopathy. *N Engl J Med* 2019;380:1597–1605.
 33. Martinot M, Ahle G, Petrosyan I, et al. Progressive multifocal leukoencephalopathy after treatment with nivolumab. *Emerg Infect Dis* 2018;24:1594–1596.
 34. Walter O, Treiner E, Bonneville F, et al. Treatment of progressive multifocal leukoencephalopathy with nivolumab. *N Engl J Med* 2019;380:1674–1676.
 35. Rauer S, Marks R, Urbach H, et al. Treatment of progressive multifocal leukoencephalopathy with pembrolizumab. *N Engl J Med* 2019;380:1676–1677.
 36. Hoang E, Bartlett NL, Goyal MS, et al. Progressive multifocal leukoencephalopathy treated with nivolumab. *J Neurovirol* 2019;25:284–287.
 37. Medrano C, Vergez F, Mengelle C, et al. Effectiveness of immune checkpoint inhibitors in transplant recipients with progressive multifocal leukoencephalopathy. *Emerg Infect Dis* 2019;25:2145–2147.
 38. Küpper C, Heinrich J, Kamm K, et al. Pembrolizumab for progressive multifocal leukoencephalopathy due to primary immunodeficiency. *Neurol Neuroimmunol Neuroinflamm* 2019;6:e628.
 39. Pawlitzki M, Schneider-Hohendorf T, Rolfes L, et al. Ineffective treatment of PML with pembrolizumab: exhausted memory T-cell subsets as a clue? *Neurol Neuroimmunol Neuroinflamm* 2019;6:e627.
 40. Audemard-Verger A, Gasnault J, Faisant M, et al. Sustained response and rationale of programmed cell death-1-targeting for progressive multifocal leukoencephalopathy. *Open Forum Infect Dis* 2019;6:ofz374.
 41. Holmes A, Wellings T, Walsh O, Rowlings P. Progressive multifocal leukoencephalopathy associated with a lymphoproliferative disorder treated with pembrolizumab. *J Neurovirol* 2020;26:961–963.
 42. Mahler C, Andrews M, Henson SM, Gnanapavan S. Sequential interleukin 2 and pembrolizumab use in progressive multifocal leukoencephalopathy. *Neurol Neuroimmunol Neuroinflamm* 2020;7:4–7.
 43. Goeraci Y, Schweitzer F, Wellstein A, et al. Clearance of JC polyomavirus from cerebrospinal fluid following treatment with interleukin-2 and pembrolizumab in an individual with progressive multifocal leukoencephalopathy and no underlying immune deficiency syndrome. *Eur J Neurol* 2020;27:2375–2377.
 44. Grassl N, Bunse L, Beutel T, et al. Nivolumab for treatment of progressive multifocal leukoencephalopathy in Sézary syndrome. *Eur J Neurol* 2020;27:2373–2374.
 45. Stögbauer J, Schulz-Schaeffer W, Mühl-Benninghaus R, Lochner P. Clinical and magnetic resonance imaging monitoring in progressive multifocal leukoencephalopathy treated with pembrolizumab: a case report. *Neurol Sci* 2021;42:357–359.
 46. Uzunov M, Demeret S, Nguyen-Quoc S, et al. Post allogeneic transplantation progressive multifocal leukoencephalopathy successfully treated by nivolumab. *Br J Haematol* 2020;188:e82–e84.
 47. Roos-Weil D, Weiss N, Guihot A, et al. Immune checkpoint inhibitors for progressive multifocal leukoencephalopathy: a new gold standard? *J Neurol* 2021;268:2458–2465.
 48. Beudel M, Rövekamp F, van de Beek D, Brouwer M. Single-dose pembrolizumab treatment for progressive multifocal leukoencephalopathy. *Neurol Neuroimmunol Neuroinflamm* 2021;8:e1021.
 49. Möhn N, Wattjes MP, Adams O, et al. PD-1-inhibitor pembrolizumab for treatment of progressive multifocal leukoencephalopathy. *Ther Adv Neurol Disord* 2021;14:1756286421993684.
 50. Fischbach L, Bauer T, Rüber T, et al. Treatment of progressive multifocal leukoencephalopathy associated with idiopathic lymphocytopenia with nivolumab. *J Neurol Sci* 2021;427:117503.
 51. Miller BC, Sen DR, Al Aboosy R, et al. Subsets of exhausted CD8+ T cells differentially mediate tumor control and respond to checkpoint blockade. *Nat Immunol* 2019;20:326–336.
 52. Martins F, Sofiya L, Sykiotis GP, et al. Adverse effects of immune-checkpoint inhibitors: epidemiology, management and surveillance. *Nat Rev Clin Oncol* 2019;16:563–580.
 53. Lefaucœur R, Ahtoy P, Bouwijn JP, et al. Progressive multifocal leukoencephalopathy in patients with sarcoidosis. *Neurology* 2014;83:1301–1302.
 54. MacKall CL, Fry TJ, Gress RE. Harnessing the biology of IL-7 for therapeutic application. *Nat Rev Immunol* 2011;11:330–342.
 55. Sospedra M, Schippling S, Yousef S, et al. Treating progressive multifocal leukoencephalopathy with interleukin 7 and vaccination with JC virus capsid protein VP1. *Clin Infect Dis* 2014;59:1588–1592.
 56. Miskin DP, Chalkias SG, Dang X, et al. Interleukin-7 treatment of PML in a patient with idiopathic lymphocytopenia. *Neurol Neuroimmunol Neuroinflamm* 2016;3:e213.
 57. Harel A, Horng S, Gustafson T, et al. Successful treatment of progressive multifocal leukoencephalopathy with recombinant interleukin-7 and maraviroc in a patient with idiopathic CD4 lymphocytopenia. *J Neurovirol* 2018;24:652–655.
 58. Soleimani-Meigooni DN, Schwytze KE, Angeles MR, et al. JC virus granule cell neuronopathy in the setting of chronic lymphopenia treated with recombinant interleukin-7. *J Neurovirol* 2017;23:141–146.
 59. Oza A, Rettig MP, Powell P, et al. Interleukin-15 superagonist (N-803) treatment of PML and JCV in a post-allogeneic hematopoietic stem cell transplant patient. *Blood Adv* 2020;4:2387–2391.
 60. Balduzzi A, Lucchini G, Hirsch HH, et al. Polyomavirus JC-targeted T-cell therapy for progressive multiple leukoencephalopathy in a hematopoietic cell transplantation recipient. *Bone Marrow Transplant* 2011;46:987–992.
 61. Muftuoglu M, Olson A, Marin D, et al. Allogeneic BK virus-specific T cells for progressive multifocal leukoencephalopathy. *N Engl J Med* 2018;379:1443–1451.
 62. Steinhardt MJ, Wiercinska E, Pham M, et al. Progressive multifocal leukoencephalopathy in a patient post allo-HCT successfully treated with JC virus specific donor lymphocytes. *J Transl Med* 2020;18:177.
 63. Berzero G, Basso S, Stoppini L, et al. Adoptive transfer of JC virus-specific T lymphocytes for the treatment of progressive multifocal leukoencephalopathy. *Ann Neurol* 2021;89:769–779.
 64. Hopfner F, Möhn N, Eiz-Vesper B, et al. Allogeneic BK virus-specific T-cell treatment in 2 patients with progressive multifocal

- leukoencephalopathy. *Neurol Neuroimmunol Neuroinflamm* 2021;8:e1020.
65. Cortese I, Beck ES, Al-Louzi O, et al. BK virus-specific T cells for immunotherapy of progressive multifocal leukoencephalopathy: an open-label, single-cohort pilot study. *Lancet Neurol* 2021;20:639–652.
 66. Kuhle J, Gosert R, Bühler R, et al. Management and outcome of CSF-JC virus PCR-negative PML in a natalizumab-treated patient with MS. *Neurology* 2011;77:2010–2016.
 67. Ray U, Cinque P, Gerevini S, et al. JC polyomavirus mutants escape antibody-mediated neutralization. *Sci Transl Med* 2015;7:306ra151.
 68. Vukusic S, Rollot F, Casey R, et al. Progressive multifocal leukoencephalopathy incidence and risk stratification among natalizumab users in France. *JAMA Neurol* 2020;77:94–102.
 69. Ryerson LZ, Foley J, Chang I, et al. Risk of natalizumab-associated PML in patients with MS is reduced with extended interval dosing. *Neurology* 2019;93:e1452–e1462.
 70. Chisari CG, Grimaldi LM, Salemi G, et al. Clinical effectiveness of different natalizumab interval dosing schedules in a large Italian population of patients with multiple sclerosis. *J Neurol Neurosurg Psychiatry* 2020;91:1297–1303.
 71. van Kempen ZLE, Hoogervorst ELJ, Wattjes MP, et al. Personalized extended interval dosing of natalizumab in MS. *Neurology* 2020;95:e745–e754.
 72. Zhovtis Ryerson L, Frohman TC, Foley J, et al. Extended interval dosing of natalizumab in multiple sclerosis. *J Neurol Neurosurg Psychiatry* 2016;87:885–889.
 73. Scarpazza C, De Rossi N, Tabiaddon G, et al. Four cases of natalizumab-related PML: a less severe course in extended interval dosing? *Neurol Sci* 2019;40:2119–2124.
 74. Vermersch P, Kappos L, Gold R, et al. Clinical outcomes of natalizumab-associated progressive multifocal leukoencephalopathy. *Neurology* 2011;76:1697–1704.
 75. Landi D, De Rossi N, Zagaglia S, et al. No evidence of beneficial effects of plasmapheresis in natalizumab-associated PML. *Neurology* 2017;88:1144–1152.
 76. Scarpazza C, Prosperini L, De Rossi N, et al. To do or not to do? Plasma exchange and timing of steroid administration in progressive multifocal leukoencephalopathy. *Ann Neurol* 2017;82:697–705.
 77. Kappos L, McGuigan C, Derfuss T et al. Determinants of clinical outcomes for patients with natalizumab-associated progressive multifocal leukoencephalopathy. 2019. ECTRIMS online library.
 78. Stefoski D, Balabanov R, Waheed R, et al. Treatment of natalizumab-associated PML with filgrastim. *Ann Clin Transl Neurol* 2019;6:923–931.
 79. Tan IL, McArthur JC, Clifford DB, et al. Immune reconstitution inflammatory syndrome in natalizumab-associated PML. *Neurology* 2011;77:1061–1067.
 80. Martin-Blondel G, Brassat D, Bauer J, et al. CCR5 blockade for neuroinflammatory diseases-beyond control of HIV. *Nat Rev Neurol* 2016;12:95–105.
 81. Martin-Blondel G, Cuzin L, Delobel P, et al. Is maraviroc beneficial in paradoxical progressive multifocal leukoencephalopathy-immune reconstitution inflammatory syndrome management? *AIDS* 2009;23:2545–2546.
 82. Giacomini PS, Rozenberg A, Metz I, et al. Maraviroc and JC virus-associated immune reconstitution inflammatory syndrome. *N Engl J Med* 2014;370:486–488.
 83. Scarpazza C, Prosperini L, Mancinelli CR, et al. Is maraviroc useful in multiple sclerosis patients with natalizumab-related progressive multifocal leukoencephalopathy? *J Neurol Sci* 2017;378:233–237.
 84. Hodecker SC, Stürmer KH, Becker V, et al. Maraviroc as possible treatment for PML-IRIS in natalizumab-treated patients with MS. *Neurol Neuroimmunol Neuroinflamm* 2017;4:e325.
 85. Januel E, Martin-Blondel G, Lamirel C, et al. Do CCR5 antagonists improve the overall survival of patients with AIDS-related progressive multifocal leukoencephalopathy? *J Neurol Neurosurg Psychiatry* 2018;89:1125–1126.
 86. Sierra-Madero J, Ellenberg SS, Rassool MS, et al. Effect of the CCR5 antagonist maraviroc on the occurrence of immune reconstitution inflammatory syndrome in HIV (CADIRIS): a double-blind, randomised, placebo-controlled trial. *Lancet HIV* 2014;1:e60–e67.
 87. Lévy Y, Lelièvre JD, Assoumou L, et al. Addition of maraviroc versus placebo to standard antiretroviral therapy for initial treatment of advanced HIV infection: a randomized trial. *Ann Intern Med* 2020;172:297–305.