

# Congenital Malformations of the Cricoid Cartilage: Upper Airway Obstruction and Treatment Strategy

Edwige Gombert, MD ; Francois Gorostidi, MD, PhD ; Kishore Sandu, MD 

**Objectives:** To review treatment and outcomes in patients with congenital cricoid cartilage malformation.

**Methods:** Retrospective analysis of patients with diagnosis of congenital cricoid malformation (CCM) treated in a single tertiary pediatric referral center between 1985 and 2022. Patients were grouped according to the morphology of the cricoid cartilage that was diagnosed during endoscopy. We reviewed the treatment strategy(s), decannulation rate, complications, and functional outcomes.

**Results:** Twenty-nine patients were grouped into four morphological subtypes of cricoid cartilage: 10 patients had a hypoplastic cricoid, eight had an elliptic shape, five had severe anterior thickening, and six an accentuated V-shape posterior cricoid plate. Twenty-four patients underwent surgery, and five were closely followed up without surgical treatment. Eight patients had a tracheostomy prior to surgery, and the majority had a hypoplastic cricoid. Most patients (20 out of 24) required additional procedures postoperatively to achieve an age-appropriate airway. Thirteen patients needed endoscopic dilatation(s) and granulation tissue removal; four needed more aggressive treatment, and three patients required revision open surgery. Decannulation was achieved after a median of 4.5 months in all previously tracheostomized patients. Endoscopy at the last follow-up showed an age-appropriate airway in 27 patients; 20 patients had normal oral feeding, and 11 patients had a normal voice.

**Conclusion:** Endoscopy is important to diagnose CCM and most of the time patients would need only watchful waiting. In this report, surgery was required for patients who continued to remain symptomatic and had a compromised airway. The type of surgery depends on the type of cricoid malformation and the grade of stenosis.

**Key Words:** congenital, cricoid cartilage, cricotracheal resection, laryngotracheal reconstruction, subglottic stenosis.

**Level of Evidence:** 4

*Laryngoscope*, 133:3185–3191, 2023

## INTRODUCTION

Subglottic stenosis (SGS) is a pathological narrowing of the upper airway located below the level of the vocal cords and above the first tracheal ring. SGS can be congenital, acquired or mixed (acquired on an underlying congenital cricoid cartilage malformation [CCM])<sup>1</sup> and its severity is graded according to the Myer–Cotton grading scale.<sup>2</sup>

Congenital SGS (C-SGS) is rare. It is due to a malformed cricoid cartilage. It is the third most common congenital laryngeal anomaly presenting with respiratory stridor.<sup>3</sup> C-SGS is due to the failure of recanalization of the laryngeal lumen by the tenth week of embryogenesis.<sup>4–6</sup> Failure of complete recanalization of the larynx may result in a range of laryngeal anomalies, including laryngeal

atresia, laryngeal webs, and C-SGS. C-SGS is characterized by an insufficient airway lumen (diameter <4 mm for a full-term neonate and <3 mm for a preterm newborn) at the level of the cricoid at birth. The obstruction can either be membranous (*soft*) resulting from submucosal gland hyperplasia and excessive connective tissue deposition, or cartilaginous (*hard*) resulting from an insufficient size or an abnormal shape of the cricoid cartilage.<sup>5</sup> In 1954, Holinger was the first to document abnormally shaped cricoid cartilage as C-SGS.<sup>1,7</sup> The five most commonly described morphological types of the cricoid cartilage are: A- normal shape cricoid; B- hypoplastic (normal shape cricoid cartilage with decreased diameter); C- elliptic (transverse diameter is significantly smaller than anteroposterior diameter); D- anterior cricoid arch thickening; and E- an accentuated V-shape of the posterior cricoid plate<sup>1,7,8</sup> (Fig. 1).

Depending on its severity, C-SGS may manifest clinically at birth with increased respiratory work and may require a tracheostomy. It may present later in life with recurrent croup-like symptoms or a difficult intubation during an elective surgery. The diagnosis of CCM is done by endoscopy. Watchful waiting is sufficient in mildly symptomatic patients as children may outgrow their symptoms with age. Surgery is required in children with symptomatic and severe CCM who may have received a prior tracheostomy.

In this article, we report our experience managing this rare condition and the treatment outcomes.

This is an open access article under the terms of the [Creative Commons Attribution-NonCommercial-NoDerivs](#) License, which permits use and distribution in any medium, provided the original work is properly cited, the use is non-commercial and no modifications or adaptations are made.

From the Centre Hospitalier Universitaire Vaudois (E.G., F.G., K.S.), ENT – Lausanne, Lausanne, Switzerland.

Editor's Note: This Manuscript was accepted for publication on February 04, 2023.

The authors have no funding, financial relationships or conflicts of interest to disclose.

Send correspondence to Kishore Sandu, Centre Hospitalier Universitaire Vaudois, Oto-Rhino-Laryngologie, Rue du Bugnon 41, Lausanne CH 1011, Switzerland. Email: [kishore.sandu@chuv.ch](mailto:kishore.sandu@chuv.ch)

DOI: 10.1002/lary.30626

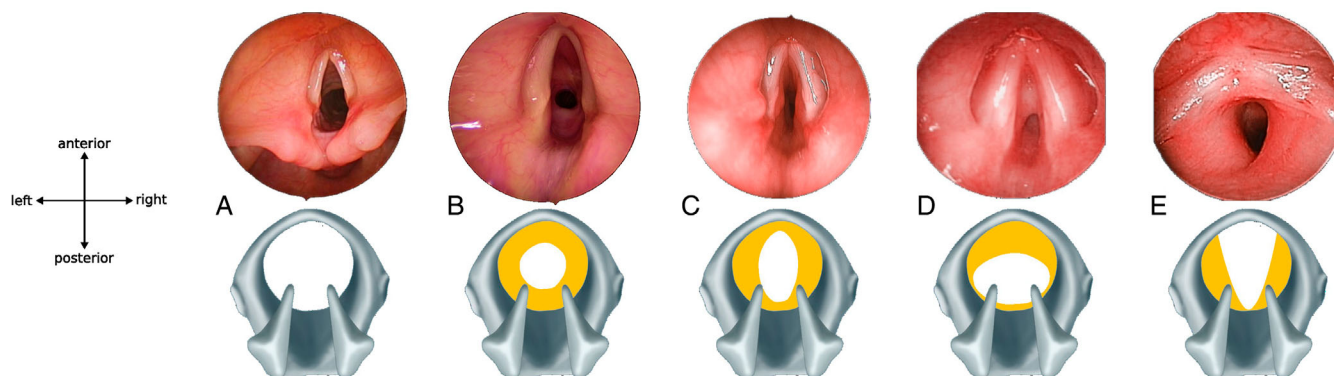


Fig. 1. Endoscopic photos and schematic representation of congenital cricoid cartilage malformations (A) Normal dimensions of the cricoid cartilage and the subglottis; (B) Hypoplastic and small cricoid with uniform circumferential cartilage thickening (yellow highlights the abnormal cartilage) and reduction of the antero-posterior (AP) and transverse (T) diameters; (C) Elliptic shape of the cricoid cartilage. AP > T diameter; (D) Thick anterior cricoid arch; (E) Prominent V-shape posterior cricoid plate.

## METHODS

This study was approved by our institution's ethical committee and review board (CER-VD 2021-00567). We retrospectively analyzed the treatment charts of all patients under 18 years of age who were referred to our clinic with a diagnosis of CCM between September 1985 and February 2022. Data collected included: patient demography, type of cricoid malformation, severity of stenosis, synchronous laryngeal lesions, associated comorbidities, treatment/surgical details and complications, follow up and functional results. Exclusion criteria included patients with an acquired SGS (intubation trauma in normal cricoid, prolonged intubation without prior endoscopic status of the subglottis, post traumatic and caustic lesions), patients who had received prior open laryngo-tracheal surgery without precise cricoid documentation, patients with laryngeal webs and clefts and those with missing relevant data.

Twenty nine patients met the inclusion criteria. The majority (90%) of which were referred from other institutions. Individual patient consent was waived due to the anonymous study design.

## Operative Techniques

**Diagnostic endoscopy.** Patients with a clinical suspicion of CCM underwent an endoscopy in two stages; the technique is described in a previous publication.<sup>9</sup> The first stage involves a dynamic fiber-optic endoscopy in a spontaneously breathing patient to observe the extra-laryngeal upper airway, vocal fold movements, and the distal airway. The second stage examines the upper airway using rigid telescopes.

**Open surgery.** In the present series, three types of open airway surgeries were used, namely, partial crico-tracheal resection (PCTR), laryngotracheal reconstruction (LTR), and slide tracheoplasty (ST). The description of these surgical procedures has been well described in the literature.<sup>3,4,10</sup>

These surgical techniques were adapted to address a specific cricoid malformation and are discussed below:

- PCTR for a hypoplastic cricoid required steps to expand the *neo*-subglottis.<sup>3,10</sup> This included generous drilling and thinning of the posterior cricoid plate with a diamond bur, along with lateral suturing of the infra-glottic mucosa with the thyroid cartilage. A posterior cricoid split without or with rib graft expansion (extended PCTR) was needed in select cases with sub-optimal posterior glottic space. Anterior thick cricoid

required removal of the abnormal anterior cricoid arch without thinning of the posterior plate. In addition, an inferior partial thyroid cartilage split below the anterior commissure was beneficial in expanding the anterior subglottis.

- LTR<sup>4</sup> for a hypoplastic cricoid invariably required submucosal thinning of the anterior arch with a diamond bur, followed by subglottic expansion using anterior and posterior rib grafts. Elliptic cricoid required both anterior and posterior grafts, which transformed the subglottis into a larger square shape. Anterior cricoid thickening required submucosal cartilage thinning and anterior cartilage graft expansion. The V-shape deformity required a posterior graft.
- ST was used in patients with a hypoplastic cricoid and an adjacent circular ring trachea. The surgery included dividing the complete tracheal rings of the cranial segment of the stenosis in the front and extending into the anterior cricoid, and then sliding the caudal segment upwards to expand the anterior cricoid arch.

PCTR and LTR were performed as a single stage (SS) procedure (concomitant removal of the SGS and the tracheostomy if pre-existing) or as a double stage (DS) procedure (when a tracheostomy was maintained at the end of the reconstructive surgery). SS was selected in patients with isolated SGS, normal vocal cord functions, and without comorbidities. DS was favored in the presence of comorbidities.<sup>3,11</sup> Stenting was done with Monniers' LaryngoTracheal (LT) Mold. Over the study period, all surgeries were performed by two experienced surgeons, sometimes with the help of cardiothoracic surgeons to treat concomitant malformations.

## Follow Up

A significant number of patients (90%) were referred from other institutions. Prior to discharge from our hospital, all patients had an endoscopic checkup and were evaluated by our speech and swallowing therapists.

Respiration was subjectively evaluated as normal, limited with forced exertion, and limited with moderate exertion, limited at rest, and objectively by the Myer-Cotton grading scale during endoscopy.

Swallowing capacity was extracted from medical records and categorized as orally fed (O), patients requiring thickeners for liquids (T), or fed through gastrostomy (G).

**TABLE I.**  
Patients Demography (*n* = 29).

	Hypoplastic	Elliptic	Anterior Thickening	V-shape
<i>n</i> (%)	10 (36%)	8 (27%)	5 (17%)	6 (20%)
Sex				
Male	8	3	2	3
Female	2	5	3	3
Comorbidities				
Heart	2		2	2
Pulmonary	4	3		1
Trisomy-21			1	
VACTERL			1	
Preterm (weeks)	3 (25)			3 (25, 28, 30)
Synchronous laryngeal lesions				
Laryngeal synechia		1	1	
Laryngomalacia	1		1	1
Vocal fold paralysis	1			
Pre-treatment				
Tracheostomy	5		2	1
Intubation		2		2

Phonation was evaluated clinically and categorized as normal voice (N), mild dysphonia (D1: hoarse voice with some difficulties of being heard or understood in a loud environment) and moderate dysphonia (D2: weak to breathy voice, easy fatigability with difficulty to communicate).

Further follow ups in the patient's home countries were conducted with the collaborating consultants. Individual patient details were obtained by sending electronic mails to the doctors and the parents. Responses to questions addressing the functional results were noted in a Microsoft Excel format.

## RESULTS

Here, we include 29 patients and identify four types of CCMs: hypoplastic (*n* = 10, 36%), elliptic (*n* = 8, 27%), anterior thickening (*n* = 5, 17%), and V-shaped (*n* = 6, 20%).

Patient characteristics are shown in Table I. Eight patients (27%) had undergone tracheostomy prior to their referral to our unit, and the majority (*n* = 5/8, 62%) were in the context of a hypoplastic cricoid. 24/29 patients (83%) received surgery, and the remaining five patients (17%) had an expectative strategy with a close follow up (NS).

Table II shows surgical data with the age of the patient at the time of diagnosis, at surgery, and the surgical technique used for each type of CCM. Around 91% of

**TABLE II.**  
Surgical Treatment.

	Hypoplastic	Elliptic	Anterior Thickening	V-shape
Subjects	10	8	5	6
Age at time of diagnosis				
At birth	3	3	3	
<6 month	1		1	2
6 month - 2 years	2	2		3
2-5 years			1	
5-10 years	1			1
NA	3	3		
Age at time of surgery				
0-3 month		1	1	
3-6 month	2	2		
6 month - 2 years	5	4	2	2
2-5 years	2			
5-15 years			1	1
>15 years	1			
First surgical treatment				
PCTR	5 SS	3 SS	2 SS	
LTR A + PCCG	2 DS 1 SS	3 SS	1 SS	1 SS
LTR PCCG	1 DS	1 SS	1 DS	2 DS
Slide tracheoplasty + anterior cricoid split	2 SS			
No surgery		1	1	3
Additional treatment				
Dilatation or ablation of granulation tissue	5	4	3	1
Endoscopic		1-endolaryngeal stent; 1-epiglottopexy 1-posterior cordotomy		1-Posterior cordotomy
Open surgery	1 (PCCG)	1 (PCCG)	1 (segmental TRA)	

Abbreviations: A + PCCG, anterior + posterior costal cartilage graft(s); DS, double stage; LTR, laryngotracheal reconstruction; NA, not available; PCCG, posterior cricoid split plus costal cartilage graft; PCTR, partial cricotracheal resection and anastomosis; SS, single stage; TRA, tracheal resection & anastomosis.

patients (21/23) were diagnosed, and 92% had the surgery (22/24) before 5 years of age.

Of the 10 patients with hypoplastic cricoid—H Six patients (60%) were treated with PCTR, 83% of whom were in SS (5/6). Two patients were treated by LTR (1 DS and 1 SS), and another two underwent ST because of associated complete tracheal ring stenosis.

Of the eight patients with an elliptic cricoid—E Three patients (37%) received PCTR, four (50%) underwent a LTR, and we adopted a close follow up policy in one patient (13%). All surgeries were done as SS procedures. Of the five patients with an anterior cricoid arch thickening—A Two patients (40%), each were treated with PCTR in a SS and LTR (1DS and 1SS), and one had NS (20%).

Of the six patients with a V-shaped CCM—V Three patients (50%) needed LTR (2DS and 1SS), and three others (50%) had only a close follow up.

Around 83% patients (20/24) required additional interventions to obtain a stable, age-appropriate airway, and decannulation if a tracheostomy was present. Of these, 85% ( $n = 17$ ; 8 H; 4 E; 3 A; 2 V) needed endoscopic procedures, and 15% ( $n = 3$ ; one patient each having H, E, A) patients needed an open surgery.

The complementary interventions had varying degrees of complexity. Thirteen patients needed balloon dilation or minor granulation tissue ablation (average: 1–4 procedures were required). Two patients needed posterior cordotomy, one needed an endoscopic stent placement and 1 needed an endoscopic epiglottopexy.

Of the three patients needing open surgical revision, two required additional posterior cartilage graft expansion, and one had segmental tracheal resection and anastomosis for stomal malacia. No patient with a V cricoid needed revision surgery.

For the SS procedure, extubation was done at a median of 7 days after surgery (IQR 6–10 days) for elliptic, and median 7 (IQR 6.5–10.5) days for hypoplastic cricoid.

Temporary re-intubation (within the first 24 h post extubation) was needed for additional 1–5 days in 31% (6 out of 19) patients.

Decannulation was possible after a median of 4.5 months (IQR: 2–5.5 m) in all previously tracheotomized patients.

Table III presents the functional results of respiration, swallowing capacity, and phonation before and after the treatment.

Currently, all previously tracheotomized patients are decannulated, and the postoperative endoscopy in 22/24 patients treated surgically has an age appropriate airway size. Two patients (one each with an elliptic and hypoplastic cricoid) presented with dyspnea during exercise at the last follow-up. One of these patients has moderate degree tracheomalacia and needs nocturnal continuous positive airway pressure (CPAP). The other patient had bilateral vocal cord hypomobility (existed preoperatively), necessitating a unilateral posterior cordotomy.

Prior to surgical treatment, 62% of patients ( $n = 15/24$ ) were fed orally. Three patients with hypoplastic cricoid and severe respiratory symptoms were dependent on gastrostomy (G) and the remaining six

	Hypoplastic	Elliptic	Anterior Thickening	V-shape
Patients (n)	10	8 (1-NS)	5 (1-NS)	6 (3-NS)
Respiration				
Pre-Operative CM grade				
I		1	1	3
II <sub>m</sub>	3	3		3
II <sub>s</sub>	1	1	1	
III <sub>m</sub>	4	3	2	
III <sub>s</sub>	2		1	
Post-Operative				
AAA	10	7	4	6
RS		1	1	
Swallowing capacity				
Pre-Operative				
O	4	5	5	6
T	3	3		
G	3			
Post-Operative				
O	4	4	3	2
T	2	1	1	1
NA	4	2		
Phonation				
Pre-Operative				
N	7	5	5	6
Aphonia <sup>a</sup>	3	3		
Post-Operative				
N	3	4	2	2
D1	1	1	2	1
D2	2		1	
NA	4	3		3

Abbreviations: AAA, age appropriate airway; NA, not available; NS, no surgery; RS, residual stenosis.

Note: Myer-Cotton (MC) grade - I: (<50% obstruction); II<sub>m</sub>: minor grade (50%–60% obstruction); II<sub>s</sub>: severe grade (60%–70% obstruction); III<sub>m</sub>: minor grade (70%–80% obstruction); III<sub>s</sub>: severe grade (80%–90% obstruction). Swallowing capacity - O: oral feeds; T: requires thickeners for liquids; G: gastrostomy fed. Phonation - N: normal voice; D1: mild dysphonia (hoarse voice with some difficulties being heard or understood in loud environment); D2: moderate dysphonia (weak voice, easy fatigability with difficulty to communicate).

<sup>a</sup>Due to tracheostomy.

needed fluid thickeners. Currently no patient is PEG fed, though 21% (5/24) of the operated patients require fluid thickeners and show improvement in their swallowing.

Postoperatively, voice was evaluated as normal in 11 patients. Five patients experience mild dysphonia (D1), and three patients have moderate dysphonia (D2).

Follow-up duration at our institution ranged from 1 month to 34 years (median 10 months; IQR 3–24 months).

## DISCUSSION

This study is a retrospective, descriptive, and monocentric experience of a small group of patients with congenital CCM. Morphologically, these present in four



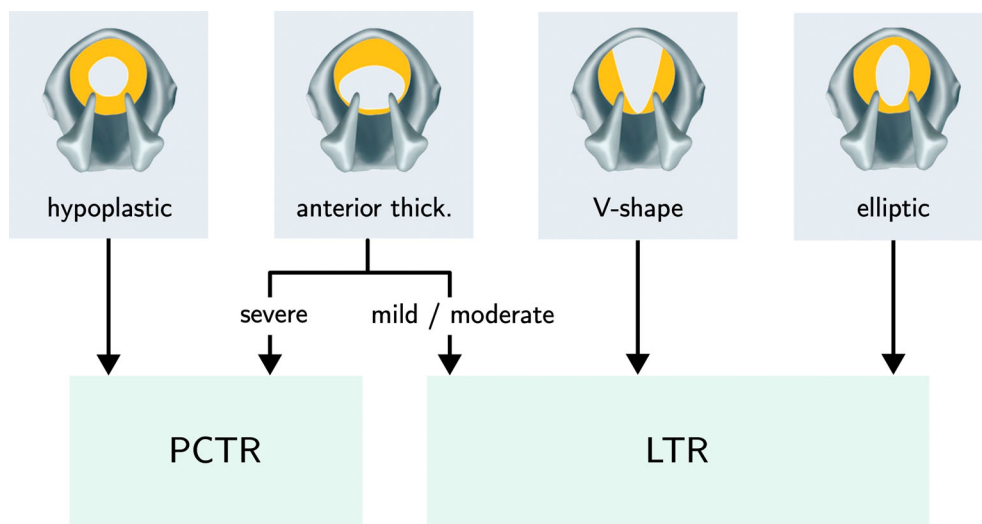


Fig. 2. Surgical treatment plan for different cricoid cartilage malformations. PCTR: partial cricotracheal resection and anastomosis; LTR: laryngotracheal reconstruction.

forms: hypoplastic, elliptic shape, thick anterior arch and prominent V-shape posterior plate.

These congenital anomalies present diversely, and therefore the treatment is variable and depends on the patient's symptoms, the type of cartilage morphology, and the associated comorbidities. Mildly symptomatic CCM with minor grades of SGS may not require surgical correction and can be closely followed. If a surgical treatment is selected, the objectives should be to achieve an age-appropriate well mucosalized airway with optimal functional outcomes. One should consider the needs of a growing airway, daily activities, sports, and an upper respiratory tract infection.

Monnier et al.<sup>3</sup> summarized the principles of laryngotracheal surgery that an airway surgeon must respect to maximize the chances of success. The quantity and quality of the original native mucosa are keys to achieving optimal mucosalization of the subglottis. Altered subglottic mucosa alters mucociliary clearance and can get reactivated in the future following an upper respiratory infection, leading to a recurrence of the stenosis.<sup>12</sup>

Bias in the choice of surgery and the retrospective design are weaknesses of this study. Our choice of surgery depends on the subtype of the CCM, the grade of the SGS, and the amount of native subglottic mucosa available. We propose to select the simplest surgical option that can efficiently solve the problem. It is critical to remove the diseased airway and preserve maximum physiologic mucosa to guarantee optimal functioning of the airway. Therefore, we preferred PCTR in a high-grade hypoplastic cricoid that has circumferentially thick cartilage. LTR could be used for cricoid hypoplasia with low-grade stenosis. When the hypoplastic cricoid is associated with a circular tracheal ring anomaly, a ST is a good option. Anterior plus posterior cartilage graft expansion is ideal for an elliptic cricoid. The posterior glottis is critical for respiration and the V shape of the cricoid narrows down this space. A posterior graft should correct this defect, though an anterior graft

can also be added as per the case requirements. Anterior thickening of the cartilage will cause a decrease in the antero-posterior diameter of the lumen airway. We therefore preferred PCTR with resection of the malformed, thickened anterior portion of the cricoid cartilage. LTR (anterior and posterior cartilage graft expansion +/- submucosal reduction of the cartilage thickness) can also be considered for this type of malformation. A patient with CCM who was intubated may develop mixed stenosis (acquired or congenital) with excessive scarring of the subglottis, or the stenosis could be multi-level. This therefore requires PCTR or extended PCTR to remove the diseased mucosa and correct the airway stenosis.

In this report, we propose a definitive surgical plan for each of the CCMs (summarized in Fig. 2), but modifications are allowed depending on the subsequent wound healing and outcomes faced at different stages of the recovery. A prospective multi-centric study including more patients would bring further evidence to the literature.

From our study, we can draw some points of critical clinical importance. First, 79% (19/24) had surgery before 2 years of age. These patients either had an early tracheostomy for an advanced grade of stenosis or were consistently symptomatic due to their compromised airway.

All the patients requiring surgery (24/29) had grade II or more SGS. Five patients had grade I SGS and required only a close follow up without the need for surgery, thanks to the natural age-related growth of their laryngeal structures.

Half the patients who required surgery had prior intubation and/or tracheostomies.

Second, from a surgical correction viewpoint, PCTR and LTR require some technical adaptation specific to the malformation.

The choice of operating in a single- or double-stage is well discussed in other articles,<sup>3,11</sup> and in our patients was based on number of airway sub-sites affected, associated comorbidities and vocal cord function(s).

Additional interventions (endoscopic and open) were required to optimize the airway and achieve decannulation. Regular postoperative endoscopic controls were performed for early detection of complications that can be repaired to ensure optimal airway healing.

An additional open procedure was performed when the airway was found to be inappropriate for the age. In this series, revision open surgeries included posterior graft expansion ( $n = 2$ ) for suboptimal posterior glottic space and segmental tracheal resection ( $n = 1$ ) for severe stomal malacia.

Airway surgeons, pediatricians, anesthesiologists, and intensivists must be aware of these malformations to allow early detection and avoid additional intubation lesions. Ultrasound has been used to predict the size of the subglottic airway and thereby the endotracheal tube size.<sup>13</sup> Rafiq et al.<sup>14</sup> found the CT scan was erroneous in detecting the endocricoid diameters. In our opinion, endoscopy is the gold standard in diagnosing CCM. A prior intubation will make this diagnosis challenging, and therefore knowledge of the existence of such an anomaly, careful observation of the subglottis during endoscopy, and differentiating cicatricial intubation lesions from the underlying cartilage anomaly are critical. We prefer a small-for-age soft endotracheal tube or a laryngeal mask ventilation in a patient with a confirmed malformation who requires an essential intervention. A patient who already has developed intubation lesions (granulations, submucosal retention cysts) over a possible CCM warrants urgent endoscopic treatment of these lesions to relieve the airway compromise and avoid a tracheostomy and a check endoscopy at a later date following complete resorption of the airway edema. In our study, we found patients were symptomatic when the subglottic obstruction exceeded grade I Myer–Cotton grading scale (up to 50% obstruction).

Regarding age at diagnosis of the CCM, this report is in agreement with the published literature.<sup>7</sup> Patients with hypoplastic and severe anterior cartilage thickening present at birth and may require an intubation and/or tracheostomy. Minor cartilage malformations present later in life (6–12 months) and are diagnosed during an endoscopy performed either for a difficult intubation, following a failed extubation, or for recurrent croup.

The treatment of CCM is inherently difficult in the presence of comorbidities and synchronous airway lesions (SALs).<sup>15</sup> In our series, SALs were seen in six out of the 29 patients, and two patients were syndromic. One child with Down syndrome was diagnosed with severe a V-shaped posterior cricoid plate and extensive anterior cricoid arc thickening at the time of intubation for cardiac surgery. If prior information of the subglottic narrowing was not documented, the child could have had an intubation trauma and a possible rough post-extubation period. A couple of months later, he received a SS-PCTR with a favorable outcome.

Six patients were preterm and of these 5 were extreme preterm (< 28 weeks). Four of these patients had a tracheostomy when they were addressed to our institution and the other two had history of previous intubation. Vakharia et al.<sup>16</sup> did not find any role of extreme prematurity on

airway surgery results, though this topic remains minimally investigated.

In terms of postoperative outcomes, optimal breathing was restored in most of our patients (22 out of 24) and all children with tracheostomies were decannulated. Swallowing results were acceptable.

Dysphonia was the poorest outcome in the postoperative period. Pre-operatively, six patients had aphonia (due to tracheostomy and an advanced grade of stenosis), and 23 patients recorded a normal voice. One patient had bilateral vocal fold immobility. Post-operatively, 11 patients had a normal voice, eight had mild to moderate dysphonia, and information was not available in 10 patients. Two patients underwent posterior cordotomies, and two required revision open surgery to enlarge the posterior glottis. It is possible that the poor voice results could be due to the advanced grades of stenosis in our series (15 patients had >70% obstruction), which required larger posterior grafts that were placed higher and led to an overexpansion of the posterior glottis. In airway surgeries, one tries to achieve an optimal balance between the airway and the voice results, and it is possible that the attempt to improve the airway by enlarging the posterior glottic space led to poor voice results in our patients.

In the future, it would be interesting to compare surgical outcomes in patients with SGS due to CCM and those following an acquired etiology.

## CONCLUSION

Clinicians must be aware of congenital CCMs. Respiratory symptoms can be variable, and there should be a high level of suspicion of such an anomaly in cases of a difficult intubation, multiple failed extubations, or recurrent croup. Endoscopy is critical to the diagnosis. Various surgical options exist and depend on the cartilage morphology and the associated comorbidities.

## ACKNOWLEDGMENT

Open access funding provided by Universite de Lausanne.

## BIBLIOGRAPHY

- Schroeder JW, Holinger LD. Congenital laryngeal stenosis. *Otolaryngol Clin North Am.* 2008;41(5):865-875.
- Myer CM, O'connor DM, Cotton RT. Proposed grading system for subglottic stenosis based on endotracheal tube sizes. *Ann Otol Rhinol Laryngol.* 1994;103(4 Pt 1):319-323.
- Monnier P. Pediatric airway surgery: management of laryngotracheal stenosis in infants and children.
- de Alarcon A, Rutter MJ. Revision pediatric Laryngotracheal reconstruction. *Otolaryngol Clin North Am.* 2008;41(5):959-980.
- Ahmad SM, Soliman AMS. Congenital anomalies of the larynx. *Otolaryngol Clin North Am.* 2007;40:177-191.
- Jefferson ND, Cohen AP, Rutter MJ. Subglottic stenosis. *Semin Pediatr Surg.* 2016;25(3):138-143.
- Holinger PH, Johnson KC, Schiller F. XLVI congenital anomalies of the larynx.
- Holinger PH, Schild JA, Kutnick SL, Holinger LD. Subglottic stenosis in infants and children. *Ann Otol.* 1976;85:591-599.
- Monnier P, Dikkers FG, Eckel H, et al. Preoperative assessment and classification of benign laryngotracheal stenosis: a consensus paper of the European laryngological society. *Eur Arch Otorhinolaryngol.* 2015; 272(10):2885-2896.
- Monnier P, Savary M, Chapuis G. Partial cricoid resection with primary tracheal anastomosis for subglottic stenosis in infants and children. *Laryngoscope.* 1993;103(11):1273-1283.

11. Smith LP, Zur KB, Jacobs IN. Single- vs double-stage laryngotracheal reconstruction. *Arch Otolaryngol Head Neck Surg.* 2010;136(1):60-65.
12. Kokje V, Ishii A, Sandu K. Moderate grade subglottic stenosis in children: laryngotracheal reconstruction versus cricotracheal resection and anastomosis. *Front Pediatr.* 2022;28(10):914892.
13. Shibasaki M, Nakajima Y, Ishii S, Shimizu F, Shime N, Sessler DI. Prediction of pediatric endotracheal tube size by ultrasonography. *Anesthesiology.* 2010;113(4):819-824.
14. Rafiq M, Wani TM, Moore-Clingenpeel M, Tobias JD. Endotracheal tubes and the cricoid: is there a good fit? *Int J Pediatr Otorhinolaryngol.* 2016; 85:8-11.
15. George M, Ikonomidis C, Jaquet Y, Monnier P. Partial cricotracheal resection for congenital subglottic stenosis in children: the effect of concomitant anomalies. *Int J Pediatr Otorhinolaryngol.* 2009;73(7):981-985.
16. Vakharia N, Maity A, Bajaj G, Bajaj Y, Hall A. Prematurity and associated future paediatric airway pathology: experience from a single tertiary paediatric ENT Centre. *Eur Arch Otorhinolaryngol.* 2020;277(11):3179-3184.