



UNIL | Université de Lausanne

Unicentre

CH-1015 Lausanne

<http://serval.unil.ch>

Year : 2022

Long-term outcomes in corticosteroid-refractory Graves' orbitopathy treated with tocilizumab

Moi Laura

Moi Laura, 2022, Long-term outcomes in corticosteroid-refractory Graves' orbitopathy treated with tocilizumab

Originally published at : Thesis, University of Lausanne

Posted at the University of Lausanne Open Archive <http://serval.unil.ch>

Document URN : urn:nbn:ch:serval-BIB_56F2D5CFCC426

Droits d'auteur

L'Université de Lausanne attire expressément l'attention des utilisateurs sur le fait que tous les documents publiés dans l'Archive SERVAL sont protégés par le droit d'auteur, conformément à la loi fédérale sur le droit d'auteur et les droits voisins (LDA). A ce titre, il est indispensable d'obtenir le consentement préalable de l'auteur et/ou de l'éditeur avant toute utilisation d'une oeuvre ou d'une partie d'une oeuvre ne relevant pas d'une utilisation à des fins personnelles au sens de la LDA (art. 19, al. 1 lettre a). A défaut, tout contrevenant s'expose aux sanctions prévues par cette loi. Nous déclinons toute responsabilité en la matière.

Copyright

The University of Lausanne expressly draws the attention of users to the fact that all documents published in the SERVAL Archive are protected by copyright in accordance with federal law on copyright and similar rights (LDA). Accordingly it is indispensable to obtain prior consent from the author and/or publisher before any use of a work or part of a work for purposes other than personal use within the meaning of LDA (art. 19, para. 1 letter a). Failure to do so will expose offenders to the sanctions laid down by this law. We accept no liability in this respect.



UNIL | Université de Lausanne

Faculté de biologie
et de médecine

UNIVERSITÉ DE LAUSANNE - FACULTÉ DE BIOLOGIE ET MÉDECINE

Département de Médecine

Service d'Immunologie et d'Allergie

**Long-term outcomes in corticosteroid-refractory Graves' orbitopathy treated
with tocilizumab**

THESE

préparée sous la direction du Professeur Camillo Ribi

et présentée à la Faculté de biologie et médecine de
l'Université de Lausanne pour l'obtention du grade de

DOCTEUR EN MÉDECINE

par

Laura MOI

Médecin diplômée d'Italie

Originaire de Zurich (ZH)

Lausanne

2022



UNIL | Université de Lausanne

Faculté de biologie
et de médecine

Ecole Doctorale
Doctorat en médecine

Imprimatur

Vu le rapport présenté par le jury d'examen, composé de

| | |
|--|---------------------------|
| Directeur.trice de thèse | Prof. Camillo Ribi |
| Co-Directeur.trice de thèse | |
| Expert.e | Prof. Peter Kopp |
| Vice-Directeur de l'Ecole doctorale | Prof. John Prior |

la Commission MD de l'Ecole doctorale autorise l'impression de la thèse de

Madame Laura Moi

intitulée

***Long-term outcomes in corticosteroid-refractory
Graves' orbitopathy treated with tocilizumab***

Lausanne, le 3 février 2022

*pour Le Doyen
de la Faculté de Biologie et de Médecine*

*Monsieur le Professeur John Prior
Vice-Directeur de l'Ecole doctorale*

Long-term outcomes in corticosteroid-refractory Graves' orbitopathy treated with tocilizumab

L'orbitopathie dysthyroïdienne (OD) est une pathologie inflammatoire de l'orbite touchant environ 20% des patients atteints de maladie de Basedow (MB). La corticothérapie systémique à haute dose représente le traitement de première ligne des cas modérés à sévères. Pour les formes récidivantes ou réfractaires, plusieurs traitements immunosuppresseurs de deuxième ligne ont été étudiés. En particulier, le tocilizumab (TCZ) a fait preuve d'efficacité dans une étude publiée en 2018, montrant une amélioration du Score d'Activité Clinique (CAS) significativement plus importante dans le groupe traité avec TCZ par rapport au groupe placebo.

Nous avons conduit une étude observationnelle rétrospective sur dix patients consécutifs avec OD réfractaire aux corticostéroïdes, traités avec TCZ entre 2016 et 2019 dans le service d'Immunologie du CHUV. Le suivi médian (IQR) a été de 24 (12-36) mois.

Nous avons pu confirmer l'efficacité du traitement: l'inflammation (CAS) et l'exophtalmie se sont considérablement améliorées chez tous les patients dans les 6 mois après le début du TCZ. Une résolution de la diplopie a été observée chez sept patients. Nous avons ainsi remarqué sous TCZ une diminution des anticorps anti-récepteurs de la TSH (anti-TSHR) plus rapide par rapport à celle qui est habituellement observée dans l'histoire naturelle de la MB. Chez six patients nous avons effectué un dosage des cytokines avant d'instaurer le TCZ : les taux sériques pré-traitement de l'IL-6, revenus tous dans les normes, n'ont pas été prédicteurs de la réponse clinique à l'anti-IL6-recepteur, qui a été efficace chez tous les patients étudiés.

Durant le *follow-up*, des effets indésirables légers à modérés, tels que neutropénie, hypercholestérolémie et infections ont été documentés chez quatre patients. Presque un tiers des patients (trois sur dix) a développé un cancer durant le *follow-up* : deux patientes ont présenté un cancer du sein et une, un cancer urothélial, d'emblée métastatique. Concernant cette incidence préoccupante, nous trouvons en littérature que les patients atteints de MB présentent un risque plus élevé de développer un cancer solide par rapport à la population générale. D'autre part, le nombre relativement élevé de fumeurs dans notre petite cohorte pourrait représenter une explication supplémentaire, étant donné que le tabagisme est un facteur de risque bien connu tant pour l'OD que pour les cancers solides, comme celui du sein. En conclusion, au vu du nombre des cas de cancer observé dans notre centre chez les patients atteints d'OD modérée à sévère, nous proposons actuellement dans notre pratique d'effectuer un *screening* oncologique au *baseline* chez cette population susceptible de recevoir de fortes doses cumulées d'immunosuppresseurs, avec une attention toute particulière pour les patients avec une histoire familiale et/ou fumeurs.

Long-term outcomes in corticosteroid-refractory Graves' orbitopathy treated with tocilizumab

Laura Moi¹  | Mehrad Hamedani² | Camillo Ribí¹

¹Division of Immunology and Allergy, Department of Medicine, Lausanne University Hospital, Lausanne University, Lausanne, Switzerland

²Department of Oculoplasty, Jules-Gonin Eye Hospital, Lausanne University, Lausanne, Switzerland

Correspondence

Laura Moi, Division of Immunology and Allergy, Department of Medicine, Lausanne University Hospital and Lausanne University, Lausanne, Switzerland.
Email: laura.moi@chuv.ch

Abstract

Background: Up to 20% of patients with moderate to severe Graves' orbitopathy (GO) do not respond to high-dose glucocorticoids (GC). A few studies, including a randomized trial, have demonstrated the efficacy of interleukin-6 (IL-6) blockade with tocilizumab (TCZ) in GC-refractory GO. However, data on predictors of response to TCZ and long-term outcomes are lacking.

Methods: Observational single-center study on ten consecutive patients treated with TCZ for GC-refractory GO, between 2016 and 2020. Median (interquartile range) follow-up was 24 (12–36) months.

Results: Inflammation and exophthalmos improved dramatically in all patients within months after starting TCZ. Mean Clinical Activity Score decreased from 4.80 ± 1.13 to 0.70 ± 0.82 points at 6 months (mean change: -4.10 ± 1.52 ; $p < .0001$). Proptosis improved from 23.2 ± 2.1 to 20.6 ± 2.0 mm at 6 months (mean change: -2.9 ± 1.4 mm; $p < .0001$). Diplopia resolved in 7 patients. Thyroid receptor antibodies decreased markedly during TCZ treatment. Baseline serum IL-6 levels did not predict clinical response. TCZ was well-tolerated. During follow-up, 3 patients were diagnosed with cancer (breast cancer in 2 and urothelial cancer in 1).

Conclusions: TCZ was rapidly effective and well-tolerated in our patients with GC-refractory GO. Four patients experienced mild/moderate adverse events as neutropenia, hyperlipidemia, and infections; nearly a third developed cancer during the follow-up. The increased incidence observed could be explained by the high prevalence of smokers, that are at higher risk for Graves' orbitopathy and solid malignancies as breast cancer. Thus, regular cancer screening could be proposed to this vulnerable population receiving high doses of immunosuppressants.

KEYWORDS

breast cancer, clinical activity score, Graves' disease, Graves' orbitopathy, interleukin-6, tocilizumab, TSHR antibodies

This is an open access article under the terms of the Creative Commons Attribution-NonCommercial-NoDerivs License, which permits use and distribution in any medium, provided the original work is properly cited, the use is non-commercial and no modifications or adaptations are made.

© 2021 The Authors. *Clinical Endocrinology* published by John Wiley & Sons Ltd.

1 | INTRODUCTION

Graves' orbitopathy (GO), also known as thyroid eye disease, is an inflammatory disorder that affects the orbital structures, causing oculomotor muscles and adipose tissue hypertrophy. Exophthalmos, eyelid retraction, strabismus, conjunctival, and periorbital tissues inflammation are typical signs of the disease. In severe cases, the orbital content enlargement can result in sight-threatening complications such as compressive optic neuropathy and corneal ulceration. Symptoms including intense pain, dryness, photophobia, diplopia, as well as aesthetic consequences impact negatively patients' quality of life.¹

GO occurs in approximately 25% of patients affected with Graves' disease (GD), representing the most common extrathyroidal disorder.² Rarely, GO is diagnosed before the occurrence of thyroid signs.³ Women are at higher risk than men, but severe forms occur more frequently in men aged over 50 years.⁴

It is thought that GO arises from crossed immunological activity between the thyroid gland and orbital tissue antigens, due to recognition of the thyroid-stimulating hormone (TSH) receptor (TSHR) and the insulin-like growth factor 1 (IGF-1) receptor (IGF-1R) as autoantigen on the cell surface of fibroblasts. The fibroblast differentiation in myofibroblasts or adipocytes following the upregulation of the TSHR/IGF-1R complex results in expanded orbital soft tissues.⁵⁻⁸ Histologic findings showing mononuclear infiltrate, predominantly characterized by CD4⁺ T cells⁵ and the overexpression of pro-inflammatory cytokines, including interleukin (IL)-6, IL-12, IL-17, interferon (IFN)- γ , and tumor necrosis factor (TNF)- α , indicate the key role of cell-mediated immunity in the physiopathology of GO.⁶

Negative prognostic factors include smoking, duration of thyroid dysfunction, severity of the local inflammation at baseline⁹ and higher serum levels of TSHR antibodies (Abs).¹⁰ Moreover, radioactive iodine treatment appears to increase the risk of occurrence of GO in patients diagnosed with GD, especially among smokers.¹¹

For mild forms, supplementation in selenium, smoking cessation, and stabilization of thyroid function can result effective.^{12,13} Nonetheless, about 2% of GO require immunosuppressive therapy.^{9,14} The European Group on Graves' Orbitopathy consensus group recommends intravenous glucocorticoids (GC) in monotherapy or in combination with mycophenolate sodium as first-line treatment for moderate-to-severe active forms of GO.¹⁵

However, up to 20% of patients with GO do not respond to high-dose glucocorticoids (GC), and approximately 30% relapse rapidly after their discontinuation.¹⁶

Numerous treatments including orbital radiotherapy, intravenous immunoglobulins, and immunosuppressants have been used in refractory GO with varying success. In recent years there has been a growing interest in targeted therapies, such as rituximab, a chimeric antibody against the B-cell marker CD20, tocilizumab (TCZ), an IL-6 inhibitor targeting the IL-6 receptor (IL-6R), and teprotumumab, an IGF-1R antagonist.

Two controlled trials have yielded conflicting results on the efficacy of rituximab in moderate-to-severe GO.^{17,18} Teprotumumab has shown efficacy in a randomized controlled trial as first-line treatment in active moderate-to-severe GO (Clinical Activity Score, CAS \geq 4), with

significant improvement of exophthalmos, CAS, diplopia, and quality of life compared to placebo.¹⁹ TCZ has been proven effective in GC-resistant patients in a small randomized clinical trial in 32 patients with moderate-to-severe GO. Improvement in CAS of \geq 2 points at week 16 compared with baseline was met in 93% of the patients receiving TCZ versus 59% receiving placebo. Exophthalmos was also significantly reduced at week 16 in the TCZ group.²⁰ Data on a longer follow-up of refractory GO treated with TCZ are lacking. We report our single-center experience in patients treated with intravenous TCZ for refractory GO followed over more than one year.

2 | MATERIALS AND METHODS

We conducted a retrospective single-center study including 10 consecutive adult patients with moderate to severe GO refractory to conventional systemic therapy of GC, treated with TCZ (Actemra/RoActemra, Roche) between June 2016 and November 2020. The study was approved by the local research ethics committee (2019-02341) and all patients gave written informed consent.

The treatment protocol consisted of TCZ 8 mg/kg body weight monthly in monotherapy for 6 months, followed by the subcutaneous formulation at the dosage of 162 mg once weekly for 6 months and once every 2 weeks for an additional 6 months.

According to local recommendations, all patients were checked monthly for complete blood count, aspartate aminotransferase (AST), alanine aminotransferase (ALT), erythrocyte sedimentation rate (ESR), and C-reactive protein (CRP). Triglycerides, high-density lipoprotein (HDL), low-density lipoprotein (LDL), and total cholesterol were measured 3 months after TCZ start and every 6 months thereafter. Ophthalmologic examination was performed every 1-3 months. Each evaluation comprised Snellen visual acuity, tonometry, Hertel exophthalmometry, and assessment of CAS score, composed of seven items: spontaneous retrobulbar pain, pain on attempted upward or downward gaze, redness of eyelids, redness of the conjunctiva, swelling of caruncle or plica, swelling of eyelids, chemosis. Six patients were assessed for serum cytokines and growth factors 6-14 weeks after the last methylprednisolone pulse and before initiating TCZ by multiplex bead assay (Thermo Fisher Scientific). The reference values of these 49 markers were defined based on the results obtained on 450 healthy subjects. Results of anti-TSHR antibodies (Abs) titers at baseline (T0) and at months 6-9 after starting TCZ, were available in 9 of the 10 patients.

The Student's paired *t*-test was carried out on CAS, proptosis, and anti-TSHR values with GraphPad Software. $p < .05$ was considered significant.

3 | RESULTS

Clinical characteristics of ten patients with refractory GO are shown in Table 1. Seven were women. Mean (\pm SD) age at diagnosis of GO was 51 ± 6.2 years (range 40-60). Six were active smokers at the time of GO diagnosis. Three patients were diabetics and two of them had

TABLE 1 Baseline characteristics and immunosuppressive treatment data on ten consecutive patients with moderate to severe Graves' orbitopathy (GO) refractory to glucocorticoids (GC), treated with tocilizumab (TCZ)

| Patient n. | 1 | 2 | 3 | 4 | 5 | 6 | 7 | 8 | 9 | 10 |
|---|----------------------|----------------------------|-------------------|-------------------------------|-------------------------------|---------------------------|-------------------------------|-------------------------------|-------------------------------|-------------------------------|
| Age at T0, year | 60 | 50 | 56 | 52 | 40 | 51 | 55 | 41 | 52 | 53 |
| Gender | F | F | F | F | M | F | F | M | M | F |
| Comorbidities | COPD, CAD, DM type 1 | Obesity (BMI 34) | | Obesity (BMI 32), DM type 2 | Chronic sinusitis | | Hepatitis C | DM type 1 | | Ulcerative colitis |
| HbA1c, % (normal range 4.9–6.5) | 7.1 | | | 5.9 | | | | 7.3 | | |
| Years from diagnosis of DM | 42 | | | 4 | | | | 23 | | |
| Smoker | Active | Active | Active | No | Active | Active | No | No | No | Active |
| PY | 61 | 28 | 56 | | 4 | 5 | | | | 12 |
| Years of exposure | 41 | 28 | 26 | | 8 | 5 | | | | 12 |
| Months between GD and GO | 4 | 29 | 61 | 120 | 21 | 21 | 1 | 72 | 4 | 1 |
| TSH at T0, mIU/L (normal range 0.27–4.20) | 0.11 ↓ | 0.67 | 1.14 | 2.75 | 0.98 | 0.30 | 0.10 ↓ | 4.21 | 2.33 | 0.20 ↓ |
| CAS at diagnosis of GO | 5 | 4 | 3 | 5 | 4 | 2 | 6 | 4 | 6 | 2 |
| CAS at T0 | 5 | 6 | 4 | 7 | 4 | 4 | 6 | 4 | 4 | 4 |
| Proptosis at T0, mm | 25 | 25 | 24 | 24 | 25 | 19 | 21 | 22 | 25 | 22 |
| Cumulative MP, grams | 3 | 6 | 4.5 | 1.5 | 3 | 6 | 3 | 3.5 | 4.5 | 4.5 |
| TCZ regimen (months) | IV (11), SC QW (4) | IV (11), SC QW (2), IV (9) | IV (6), SC QW (6) | IV (6), SC QW (6), SC Q2W (6) | IV (6), SC QW (6), SC Q2W (6) | IV (6), SC QW (6), QW (6) | IV (6), SC QW (6), SC Q2W (6) | IV (6), SC QW (6), SC Q2W (6) | IV (4), SC QW (1), SC Q2W (4) | IV (6), SC QW (6), SC Q2W (4) |
| Cumulative exposure in months | 15 | 22 | 12 | 18 | 18 | 12 | 18 | 18 | 12 | 16 |

Note: Mean (\pm SD) age at diagnosis of GO was 51 ± 6.2 years. Six patients were active smokers. Three patients were diabetics. Mean Clinical Activity Score (CAS) was 4 ± 1.50 at GO diagnosis and 4.80 ± 1.13 at T0 (time of first TCZ infusion). Mean cumulative dose of GC received was 3.95 ± 1.42 g. Three patients were hyperthyroid at T0. Three female patients (n. 1, 3, and 6) were diagnosed with cancer at least 12 months after TCZ start: breast cancer occurred in patients n. 1 and n. 6, metastatic bladder cancer in patient n. 3.

Abbreviations: BMI, Body Mass Index (expressed in kg/m^2); CAD, coronary artery disease; CAS, Clinical Activity Score; COPD, chronic obstructive pulmonary disease; DM, diabetes mellitus; GD, Graves' disease; GO, Graves' orbitopathy; HbA1c, glycated hemoglobin; IV, intravenous; MP, methylprednisolone; n., number; PY, pack-year; QW, once weekly; Q2W, once every 2 weeks; SC, subcutaneous; T0, time of first tocilizumab infusion; TCZ, tocilizumab; TSH, thyroid-stimulating hormone.

type I diabetes. The median time between the appearance of GD and diagnosis of GO was 14 (IQR: 61–4) months. Mean CAS at GO diagnosis was 4 ± 1.50 . The mean cumulative dose of GC received was 3.95 ± 1.42 g. One patient had received radioactive iodine 8 years before developing GO. Three patients had unsuccessful external orbital radiotherapy before starting TCZ.

Median (interquartile range) duration of ophthalmologic follow-up was 24 (12–36) months. All patients received intravenous TCZ for at least 6 months. In the majority of patients, the TCZ regimen was different from the planned protocol (Table 1), and this for different reasons: logistical problems, local side effects to subcutaneous injections, cancer diagnosis. Mean CAS at the TCZ treatment start was 4.80 ± 1.13 . All patients presented a marked reduction of the CAS within months of TCZ treatment: mean CAS at 6 months was 0.70 \pm 0.82, corresponding to a change in score of -4.10 ± 1.52 , $p < .0001$. Half of the patients showed a CAS of 0 after 6 months (Figure 1). Proptosis, measured with Hertel's exophthalmometer, improved from 23.20 ± 2.10 mm to 20.60 ± 2.01 mm at 6 months, corresponding to an average reduction of -2.90 ± 1.37 mm, $p < .0001$ (Figure 1).

Mean levels of anti-TSHR Ab decreased from 12.79 ± 11.92 U/l at baseline to 3.20 ± 4.57 U/l at 6 months, corresponding to a mean difference of -9.58 ± 8.62 U/l, $p = .016$ (Figure 1).

Serum cytokine and chemokine expression in six patients before TCZ treatment initiation is shown in Figure 2. IL-6 levels were in the normal range in all tested patients.

The treatment was overall well-tolerated. Mild and moderate adverse events were observed in four patients (Table 2): worsened hypercholesterolemia requiring statin therapy, mild neutropenia, delayed injection-site reactions to subcutaneous TCZ requiring prolonged intravenous administration, and recurrent upper respiratory tract infections and skin abscess in a diabetic patient. No cardiovascular events were observed during the follow-up.

Three patients were diagnosed with cancer after TCZ start: two had breast cancer and one bladder cancer. Patient n. 1 (Table 1) was diagnosed at age 62 with “no special type” breast cancer, stage pT2 N0 M0 according to TNM classification. The nodule was first noticed by the patient on breast self-examination, three years after the last mammogram. She had no family history of breast cancer and was never been exposed to exogenous estrogen. The diagnosis occurred 12 months after TCZ discontinuation. The patient underwent a lumpectomy followed by radiation therapy and hormone therapy. She is free of relapse 27 months after the tumor diagnosis.

Patient n. 6 (Table 1) was diagnosed with lobular in situ breast cancer at age 52, 12 months after starting TCZ. The tumor was detected by mammography/ultrasound screening, which was routinely performed in this patient due to several bilateral breast cysts and a positive family history: her mother and two maternal cousins had BRCA-negative breast cancer. The patient had had two full-term pregnancies and had never been exposed to exogenous estrogen. The tumor was completely resected by lumpectomy. The patient is free from relapse 40 months after cancer detection.

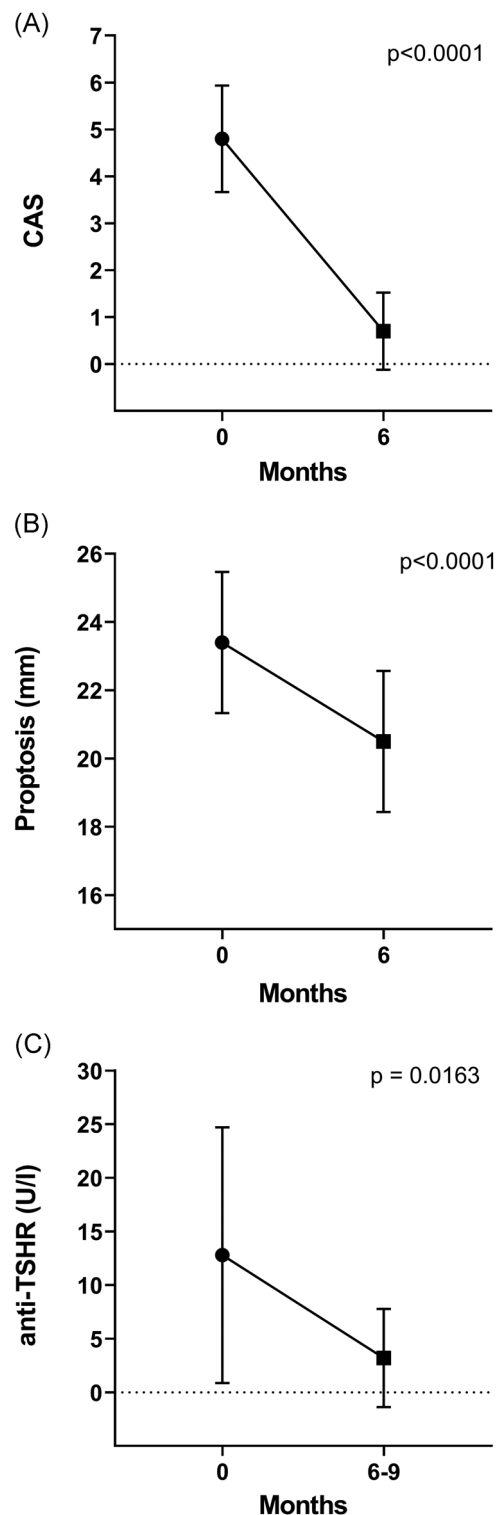


FIGURE 1 Disease activity at baseline and during treatment with TCZ in patients with refractory GO. (A) CAS at baseline and after 6 months in 10 patients. (B) Exophthalmos measured by Hertel exophthalmometer at baseline and after 6 months in 10 patients. (C) Antibodies to TSHR at baseline and after 6–9 months in 9 patients. GO, Graves' orbitopathy; TCZ, tocilizumab; TSHR, thyroid-stimulating hormone receptor

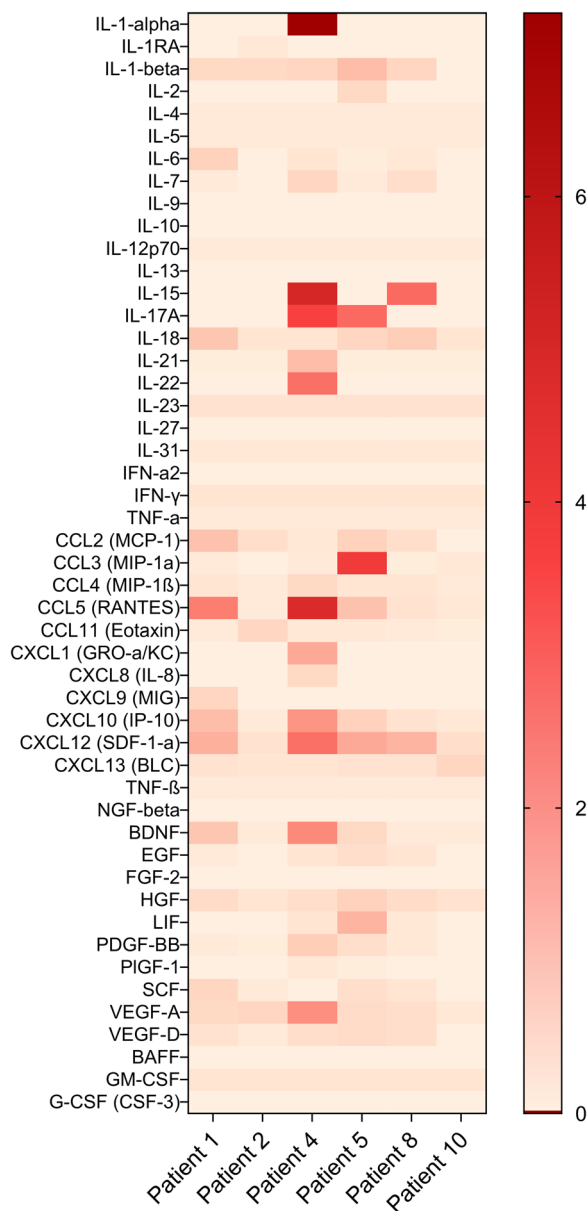


FIGURE 2 Heat map of serum cytokines, chemokines, and growth factors measured by multiplex bead assay in six patients with refractory GO before starting TCZ. The color scale represents the relative expression of the 47 serum markers, normalized from concentration in pg/ml, ranging from the minimum (0) to the maximum (6) of all values. GO, Graves' orbitopathy; TCZ, tocilizumab

Patient n. 3 (Table 1) was diagnosed with metastatic urothelial cancer at age 57. She complained of abdominal pain 12 months after the start of TCZ, the CT scan revealed a bladder mass, multiple enlarged lymph nodes, and liver metastasis. The patient survived 15 months.

After TCZ cessation, two patients underwent surgical rehabilitation (bilateral blepharoplasty and combined strabismus surgery and unilateral microtarsorrhaphy).

4 | DISCUSSION

The main limitation of this study is the lack of a control group, due to the retrospective nature of our analysis. However, we documented in detail the response to treatment and the clinical outcome of ten consecutive patients with moderate to severe GO, followed for at least 12 months. Our results confirmed the efficacy and safety of TCZ for GC-refractory GO.

Most patients displayed a rapid improvement in CAS after the first infusion. We also observed a dramatic reduction of anti-TSHR Abs levels measured after a 6- to 9-month of TCZ therapy, compared with pretreatment values. Anti-TSHR Abs were shown to be associated with activity and severity of GO.¹⁰ The reduction in TSHR Abs we observed exceeds the expected decrease during the natural course of the disease and can likely be attributed to TCZ treatment. Indeed, a significant reduction of autoantibodies during treatment with TCZ was reported in other diseases, such as antibodies to cyclic citrullinated peptides (CCP) in rheumatoid arthritis.²¹ The exact mechanism underlying the effect on auto-Abs is poorly understood, it is probably related to the blockade of IL-6 growth autocrine effect on B cells, which regulates the plasma-cell differentiation and antibodies (including autoantibodies) secretion. Furthermore, the disrupted IL-6 signaling might also influence the distribution of B cell subpopulations in circulation, lymphoid system, and inflamed tissues.²¹

In the orbit, IL-6 is able to stimulate the TSHR expression on the fibroblast surface²² and promotes orbital adipogenesis.²³ Such properties emphasize the local key role of IL-6 in the development of retrobulbar inflammation and enlargement. Of note, Kumar et al. found a 23.9-fold increased expression of genes encoding IL-6 in orbital tissues from active GO compared with normal specimens.²⁴ Moreover, increased IL-6 mRNA expression in orbital fat has been found to correlate with GO activity.²⁵ Significantly increased levels of IL-6, as well as IL-13 and TNF- α , were found in the tears of patients with active GO (CAS > 3) compared with controls.²⁶

We assessed circulating cytokines and growth factors in six patients before treatment started. Although patients had similar clinical characteristics (middle-aged with refractory GO with CAS \geq 4), no specific signature pattern emerged. Measured cytokine levels were unlikely influenced by previous methylprednisolone treatment, as samples had been taken at the earliest 6 weeks after glucocorticoid therapy. Interestingly, normal circulating IL-6 levels at baseline were not predictive of poor efficacy to IL-6 receptor blockade, all the patients had a satisfactory response to TCZ. This is in contrast to other studies in GO that suggest that pretreatment IL-6 levels correlated with disease activity and predict response to treatment.^{27,28} However, our findings are in accordance with what is observed in other conditions, such as rheumatoid arthritis, where serum IL-6 and other markers of inflammation do not predict response to TCZ.²⁹

Several of our patients displayed an increase in IL-1 signature and IL-15 (Figure 2). Interestingly, IL-1 α , as well as TNF- β and IFN- γ , has been detected in the retro-ocular connective tissue of GD patients³⁰ and it is able to induce fibroblast deposition of glycosaminoglycans.³¹

| Event | AEs n. | Patients n. (%) | AEs grade ^a | Onset from TCZ start, months (regimen) |
|---|--------|---------------------|------------------------|---|
| Neutropenia (Grade I) | 1 | 1 (10) | Mild | 6 (6 IV) |
| Hyperlipidemia | 1 | 1 (10) | Moderate | 8 (6 IV + 2 SC) |
| Delayed injection-site reactions | 1 | 1 (10) | Moderate | 13 (11 IV + 2 SC) |
| Skin infection | 1 | 1 (10) | Moderate | 17 (6 IV + 11 SC) |
| Respiratory tract infection | 2 | 1 (10) | Moderate | 16 (6 IV + 10 SC) 16 (6 IV + 12 SC) |
| Breast cancer, lobular in situ ^b | 1 | 1 (10) | Severe | 12 (6 IV + 6 SC) |
| Bladder cancer, metastatic ^b | 1 | 1 (10) | Death ^c | 12 (6 IV + 6 SQ) |
| Breast cancer, no special type pT2 N0 M0 ^b | 1 | 1 (10) | Severe | Delayed, 12 months after TCZ discontinuation ^d |
| Any AEs | 9 | 7 (70) ^e | | |

Abbreviations: AEs, adverse events; IV, intravenous; n., number; TCZ, tocilizumab; SC, subcutaneous.

^aAEs grades are reported according to the Common Terminology Criteria for Adverse Events (CTCAE) version 5.0.

^bThe causal link between the three cases of cancer and TCZ treatment is uncertain; individual predisposing factors, smoking, and prior immunosuppression burden may have been more relevant in the genesis of cancer.

^cDeath occurred 15 months after the cancer diagnosis.

^dCumulative exposure to TCZ was 15 months.

^eHyperlipidemia and bladder cancer occurred in the same patient.

TABLE 2 Adverse events (AEs) observed in ten patients with refractory Graves' orbitopathy treated with tocilizumab (TCZ)

Three of our patients were diagnosed with cancer after treatment with TCZ. TCZ therapy itself was not shown to be significantly associated with increased risk of cancer in large studies in rheumatoid arthritis^{32,33} or giant cell arteritis.³⁴ The association of cancer with TCZ treatment in our study might be incidental, given also the relatively short duration of exposure to the drug. It is more likely that the number of cancers observed is associated with the underlying disease. Indeed, several studies reported an increased risk for malignancies in thyroid autoimmune disease.^{35–37} In patients affected with GD, cancers of the thyroid, breast, and upper aero-digestive tract are reportedly the most common malignancies.³⁵

Data from a large Chinese cohort with newly diagnosed GD showed an increased incidence of cancer compared to the general background population. In particular, the hazard ratio for the development of breast cancer and thyroid cancer was 1.58- and 10.4-fold higher in patients with GD.³⁶ Increased risk for breast cancer, especially in women with multiple hospitalizations, was also shown in a large Swedish cohort of GD patients.³⁵ Specific receptivity of breast cells to thyroid hormones and/or thyroid Abs stimuli may play a role in oncogenesis, as suggested from the high incidence and aggressiveness of breast cancer observed in hyperthyroidism.³⁸

It is not excluded that the association between GD and breast cancer can be partially related to shared predisposing factors, as for instance smoking is a well-described risk factor for both entities.^{39,40}

Epidemiological studies have not highlighted a significant correlation between GD or GO and increased risk of urinary tract cancer. We can mention active smoking as the main risk factor for bladder cancer in the patient of our study.

In conclusion, our study confirms that TCZ is an effective and well-tolerated treatment in patients with steroid-refractory GO. Serum IL-6 levels did not predict response to TCZ. Thyroid receptor antibodies decreased markedly during treatment with TCZ. Patients with GO, and particularly patients with additional risk factors such as smoking and family history, are at higher risk for cancer compared to the general population. Based on such findings and given the increased frequency of cancer observed in our series, we currently recommend in our center that all patients with GD (and GO) undergo complete gynecological cancer-screening tests including a mammogram, in addition to regular screenings for thyroid cancer, especially if they are smokers, have a family history and anyway before starting systemic immunosuppressive agents.

ACKNOWLEDGMENT

No funding was received for this article.

CONFLICT OF INTERESTS

The authors declare that there are no conflict of interests.

AUTHOR CONTRIBUTIONS

Laura Moi carried out the data collection, data analysis and wrote the article with the support from Camillo Ribbi, who conceived and supervised the work. Mehrad Hamedani performed all the ophthalmological exams, contributed to the interpretation of the results, and revised the final manuscript.

DATA AVAILABILITY STATEMENT

The data that support the findings of this study are available on request from the corresponding author. The data are not publicly available due to privacy or ethical restrictions.

ORCID

Laura Moi  <http://orcid.org/0000-0001-7890-944X>

REFERENCES

- Wickwar S, McBain HB, Ezra DG, Hirani SP, Rose GE, Newman SP. What are the psychosocial outcomes of treatment for thyroid eye disease? A systematic review. *Thyroid*. 2014;24(9):1407-1418.
- Tanda ML, Piantanida E, Liparulo L, et al. Prevalence and natural history of Graves' orbitopathy in a large series of patients with newly diagnosed graves' hyperthyroidism seen at a single center. *J Clin Endocrinol Metab*. 2013;98(4):1443-1449.
- Wiersinga WM, Smit T, van der Gaag R, Koornneef L. Temporal relationship between onset of Graves' ophthalmopathy and onset of thyroidal Graves' disease. *J Endocrinol Invest*. 1988;11(8):615-619.
- Maheshwari R, Weis E. Thyroid associated orbitopathy. *Indian J Ophthalmol*. 2012;60(2):87-93.
- Bahn RS. Graves' ophthalmopathy. *N Engl J Med*. 2010;362(8):726-738.
- Hodgson NM, Rajaii F. Current understanding of the progression and management of thyroid associated orbitopathy: a systematic review. *Ophthalmol Ther*. 2020;9(1):21-33.
- Krieger CC, Place RF, Bevilacqua C, et al. TSH/IGF-1 receptor cross talk in Graves' ophthalmopathy pathogenesis. *J Clin Endocrinol Metab*. 2016;101(6):2340-2347.
- Naik VM, Naik MN, Goldberg RA, Smith TJ, Douglas RS. Immunopathogenesis of thyroid eye disease: emerging paradigms. *Surv Ophthalmol*. 2010;55(3):215-226.
- Wiersinga W, Žarković M, Bartalena L, et al. Predictive score for the development or progression of Graves' orbitopathy in patients with newly diagnosed Graves' hyperthyroidism. *Eur J Endocrinol*. 2018;178(6):635-643.
- Eckstein AK, Plicht M, Lax H, et al. Thyrotropin receptor auto-antibodies are independent risk factors for Graves' ophthalmopathy and help to predict severity and outcome of the disease. *J Clin Endocrinol Metab*. 2006;91(9):3464-3470.
- Träisk F, Tallstedt L, Abraham-Nordling M, et al. Thyroid-associated ophthalmopathy after treatment for Graves' hyperthyroidism with antithyroid drugs or iodine-131. *J Clin Endocrinol Metab*. 2009;94(10):3700-3707.
- Marcocci C, Kahaly GJ, Krassas GE, et al. Selenium and the course of mild Graves' orbitopathy. *N Engl J Med*. 2011;364(20):1920-1931.
- Pfeilschifter J, Ziegler R. Smoking and endocrine ophthalmopathy: impact of smoking severity and current vs lifetime cigarette consumption. *Clin Endocrinol (Oxf)*. 1996;45(4):477-481.
- Perros P, Hegedüs L, Bartalena L, et al. Graves' orbitopathy as a rare disease in Europe: a European Group on Graves' Orbitopathy (EUGOGO) position statement. *Orphanet J Rare Dis*. 2017;12(1):72.
- Bartalena L, Kahaly GJ, Baldeschi L, et al. The 2021 European Group on Graves' orbitopathy (EUGOGO) clinical practice guidelines for the medical management of Graves' orbitopathy. *Eur J Endocrinol*. 2021;185(4):G43-G67.
- Bartalena L, Krassas GE, Wiersinga W, et al. Efficacy and safety of three different cumulative doses of intravenous methylprednisolone for moderate to severe and active Graves' orbitopathy. *J Clin Endocrinol Metab*. 2012;97(12):4454-4463.
- Salvi M, Vannucchi G, Currò N, et al. Efficacy of B-cell targeted therapy with rituximab in patients with active moderate to severe Graves' orbitopathy: a randomized controlled study. *J Clin Endocrinol Metab*. 2015;100(2):422-431.
- Stan MN, Garrity JA, Carranza Leon BG, Prabin T, Bradley EA, Bahn RS. Randomized controlled trial of rituximab in patients with Graves' orbitopathy. *J Clin Endocrinol Metab*. 2015;100(2):432-441.
- Douglas RS, Kahaly GJ, Patel A, et al. Teprotumumab for the treatment of active thyroid eye disease. *N Engl J Med*. 2020;382(4):341-352.
- Perez-Moreiras JV, Gomez-Reino JJ, Maneiro JR, et al. Efficacy of tocilizumab in patients with moderate-to-severe corticosteroid-resistant Graves orbitopathy: a randomized clinical trial. *Am J Ophthalmol*. 2018;195:181-190.
- Noguchi A, Yasuda S, Hisada R, et al. Anti-cyclic citrullinated peptide antibody titers decrease in rheumatoid arthritis patients treated with tocilizumab: a pilot study. *Mod Rheumatol*. 2020;30(2):276-281.
- Jyonouchi SC, Valyasevi RW, Harteneck DA, Dutton CM, Bahn RS. Interleukin-6 stimulates thyrotropin receptor expression in human orbital preadipocyte fibroblasts from patients with Graves' ophthalmopathy. *Thyroid*. 2001;11(10):929-934.
- Gillespie EF, Raychaudhuri N, Papageorgiou KI, et al. Interleukin-6 production in CD40-engaged fibrocytes in thyroid-associated ophthalmopathy: involvement of Akt and NF-kappaB. *Invest Ophthalmol Vis Sci*. 2012;53(12):7746-7753.
- Kumar S, Leontovich A, Coenen MJ, Bahn RS. Gene expression profiling of orbital adipose tissue from patients with Graves' ophthalmopathy: a potential role for secreted frizzled-related protein-1 in orbital adipogenesis. *J Clin Endocrinol Metab*. 2005;90(8):4730-4735.
- Wakelkamp IM, Bakker O, Baldeschi L, Wiersinga WM, Prummel MF. TSH-R expression and cytokine profile in orbital tissue of active vs. inactive Graves' ophthalmopathy patients. *Clin Endocrinol (Oxf)*. 2003;58(3):280-287.
- Kishazi E, Dor M, Eperon S, Oberic A, Turck N, Hamedani M. Differential profiling of lacrimal cytokines in patients suffering from thyroid-associated orbitopathy. *Sci Rep*. 2018;8(1):10792.
- Lacka K, Manuszewska E, Korczowska I, Lacki JK. The effect of methylprednisolone pulse treatment on cytokine network in Graves ophthalmopathy. *Curr Eye Res*. 2007;32(3):291-297.
- Stoyanova MA, Shinkov AD, Georgiev GK, Kovatcheva RD. Association between clinical activity score and serum interleukin-6, interleukin-8 and interleukin-10 during systemic glucocorticoid treatment for active moderate-to-severe Graves' orbitopathy. *Curr Eye Res*. 2021;46:1-6.
- Wang J, Devenport J, Low JM, Yu D, Hitraya E. Relationship between baseline and early changes in C-reactive protein and interleukin-6 levels and clinical response to tocilizumab in rheumatoid arthritis. *Arthritis Care Res (Hoboken)*. 2016;68(6):882-885.
- Heufelder AE, Bahn RS. Detection and localization of cytokine immunoreactivity in retro-ocular connective tissue in Graves' ophthalmopathy. *Eur J Clin Invest*. 1993;23(1):10-17.
- Korducki JM, Loftus SJ, Bahn RS. Stimulation of glycosaminoglycan production in cultured human retroocular fibroblasts. *Invest Ophthalmol Vis Sci*. 1992;33(6):2037-2042.
- Kim SC, Pawar A, Desai RJ, et al. Risk of malignancy associated with use of tocilizumab versus other biologics in patients with rheumatoid arthritis: A multi-database cohort study. *Semin Arthritis Rheum*. 2019;49(2):222-228.

33. Rubbert-Roth A, Sebba A, Brockwell L, et al. Malignancy rates in patients with rheumatoid arthritis treated with tocilizumab. *RMD Open*. 2016;2(1):e000213.
34. Calderón-Goercke M, Loricera J, Aldasoro V, et al. Tocilizumab in giant cell arteritis. Observational, open-label multicenter study of 134 patients in clinical practice. *Semin Arthritis Rheum*. 2019;49(1):126-135.
35. Shu X, Ji J, Li X, Sundquist J, Sundquist K, Hemminki K. Cancer risk in patients hospitalised for Graves' disease: a population-based cohort study in Sweden. *Br J Cancer*. 2010;102(9):1397-1399.
36. Chen YK, Lin CL, Chang YJ, et al. Cancer risk in patients with Graves' disease: a nationwide cohort study. *Thyroid*. 2013;23(7):879-884.
37. Stocker DJ, Burch HB. Thyroid cancer yield in patients with Graves' disease. *Minerva Endocrinol*. 2003;28(3):205-212.
38. Glushakov RI, Proshin SN, Tapil'skaya NI. The incidence of breast tumor during experimental hyperthyroidism. *Bull Exp Biol Med*. 2013;156(2):245-247.
39. Macacu A, Autier P, Boniol M, Boyle P. Active and passive smoking and risk of breast cancer: a meta-analysis. *Breast Cancer Res Treat*. 2015;154(2):213-224.
40. Vestergaard P, Rejnmark L, Weeke J, et al. Smoking as a risk factor for Graves' disease, toxic nodular goiter, and autoimmune hypothyroidism. *Thyroid*. 2002;12(1):69-75.

How to cite this article: Moi L, Hamedani M, Ribic C. Long-term outcomes in corticosteroid-refractory Graves' orbitopathy treated with tocilizumab. *Clinical Endocrinology*. 2021;1-8. doi:10.1111/cen.14655