

Pediatrics

Hydronephrosis caused by kidney malrotation

Natalie Divjak^{a,*}, Jacques Birraux^b, Hassib Chehade^c, Oliver Sanchez^a^a Centre Universitaire Romand de Chirurgie Pédiatrique, Division of Pediatric Surgery of Lausanne, CHUV, Lausanne, Switzerland^b Centre Universitaire Romand de Chirurgie Pédiatrique, Division of Pediatric Surgery of Geneva, HUG, Genève, Switzerland^c Division of Pediatric Nephrology, Department Woman-Mother-Child, CHUV, Lausanne, Switzerland

ARTICLE INFO

Keywords:

Kidney malrotation
 Pyelo-ureteric joint obstruction
 Laparoscopic ureterocalicostomy
 Pediatric urology

ABSTRACT

Hydronephrosis associated with kidney malrotation can be a surgical challenge.

We present the case of a 3.5 y.o.-boy presenting with left pyelo-ureteric obstruction caused by kidney hyperrotation (270°) resulting in recurring urinary tract infection. After complete radiological work-up, we opted for a primary laparoscopic ureterocalicostomy, which allowed for complete resolution of the pelvic dilatation.

Kidney malrotation can present with a wide variation in anatomic features. Radiological work-up is the cornerstone of surgical strategy planning. Laparoscopic ureterocalicostomy is a useful primary option in unusual anatomical situations.

Introduction

During fetal development, kidney migration from a sacral to a lumbar position, as well as a medialization of the hilum position, occur. Abnormalities in this process cause kidney malrotation. The unusual orientation of the hilum may favor intrinsic pyelo-ureteric junction (PUJ) obstruction, as well as possible extrinsic compression by associated aberrant vascularization or ureteric kinking. These anatomic variations represent a challenge when surgical intervention on PUJ obstruction is needed.

Case presentation

We present the case of 3.5 y.o.-boy with bilateral kidney malrotation, with, on the right side, an ectopic pelvic kidney, and, on the left side, a hyper-rotated kidney with worsening hydronephrosis.

First work up was done at 33 days of age, when he presented with pyelonephritis. Ultrasound showed a right pelvic kidney with normal pelvic AP diameter, and a left orthotopic kidney with 12mm pelvic dilatation. Voiding cystourethrography (VCUG) showed right grade III vesico-ureteral reflux (VUR). Dynamic isotope renal scintigraphy showed symmetrical function with delayed left-sided clearance.

Despite antibiotic prophylaxis, the patient presented 3 subsequent episodes of pyelonephritis during the 5 following months. Circumcision was performed, in accordance with European Society of Pediatric

Urology recommendations, without recurrence of infection.

At 3 years of age, the left pelvic dilatation increased, nuclear scan clearance curve appeared clearly obstructive, and ultrasound suggested aberrant vascularization. Work-up was completed by angio-MRI and cystoscopic retrograde pyelogram (Fig. 1). This confirmed left pelvic dilatation explained by a very high insertion of the ureter on the pelvis of a hyperrotated (270°) kidney. Vascularization was abnormal with 3 arteries, of which two originated from the aorta and the third from de left common iliac artery. Venous return consisted in 3 renal veins originating from the hilum and joining the inferior vena cava. The right pelvic kidney, malrotated with an inferior directed hilum, presented no pelvic dilatation, and was vascularized by 2 arteries, one from the common iliac artery and one from the aortic bifurcation, as well as 2 veins.

The anatomical features of the left kidney did not allow for standard Anderson-Hynes dismembered pyeloplasty, and it was decided to reimplant the ureter antero-inferiorly on the inferior calyx to allow for optimal drainage. The patient thus underwent a left laparoscopic ureterocalicostomy. A JJ stent 3.7 Fr, 8–20 cm was positioned by cystoscopy at the beginning of the procedure and left in place throughout. We intraoperatively confirmed the hyperrotated kidney, with vascularization going behind the kidney to join the laterally orientated hilum. The ureter was cranially and laterally inserted on the pelvis, coursing over the kidney, with the PUJ showing signs of narrowing. After circumferential dissection of the ureter, it was sectioned and spatulated. Two

* Corresponding author. Service de Chirurgie de l'Enfant et de l'Adolescent, Centre Hospitalier Universitaire Vaudois, Rue du Bugnon 21, 1011, Lausanne, Switzerland.

E-mail address: natalie.divjak@chuv.ch (N. Divjak).

<https://doi.org/10.1016/j.eucr.2021.101564>

Received 8 December 2020; Received in revised form 27 December 2020; Accepted 4 January 2021

Available online 11 January 2021

2214-4420/© 2021 The Authors. Published by Elsevier Inc. This is an open access article under the CC BY license (<http://creativecommons.org/licenses/by/4.0/>).

ligatures were placed over the PUJ. An inverted funnel shape excision of parenchyma was performed on the lower pole, giving access to the inferior calyx. The spatulated ureter was then reimplanted on the inferior calyx opening, taking care to secure the four resorbable 4.0 stitches on the calix urothelium (Fig. 2).

At 1-month follow-up, pelvic dilatation had completely regressed. JJ stent was removed at 3 months. On nuclear scan 1 year post-operatively, function remained symmetrical (without loss of function) and urine flow had greatly improved on the operated kidney. Ultrasound showed no residual hydronephrosis.

Discussion

During its migration from the upper sacral region to the 12th thoracic rib level between 6 and 9 weeks of gestation, the kidney is supplied by a number of transitory vessels, all originating from the aorta, up to the definitive lumbar vessels.^{1,2}

Arrested migration of the kidney results in ectopic, most frequently pelvic, kidney. Ectopic kidneys are not uncommon (1/1000), and more frequently associated with other urological pathologies, like PUJ obstruction and VUR. Ectopic kidneys tend to retain early migration vascularization.³ In our patient, this resulted in the double right arterial supply described above.

During its ascent, the kidney also performs a 90° medial rotation from a ventral hilar orientation to a medial, slightly ventral position. Renal malrotation is found in 1/939 autopsies.² Its incidence is probably underestimated, as it is mostly non-symptomatic.

Abnormalities of renal rotation are generally in the horizontal plane (around a vertical axis), consisting in either insufficient rotation, hyperrotation or inversed rotation. Our case consists in a hyperrotation of more than 270°, considering the lateral position of the hilum, while vascularization lies posteriorly. Anomalies of vascularization are frequent in renal malrotation,⁴ but do not respect a specific pattern. In this case, on the left side, we also find residual arterial branches from different levels of migration.

The cause of the hydronephrosis was the position of the PUJ, cranially and posteriorly on the pelvis. The embryological origin of this situation may be an ectopic penetration of the ureteric bud cranially in the metanephric blastema, or, as suggested by Massicot and al.,² an overdevelopment of the inferior renal pole stretching the ureter and causing a PUJ kinking and stenosis. Our particular situation, with a dorso-cranial oriented PUJ, did not allow for a simple liberation of the ureter, as in Massicot's case,² or a dismembered Anderson-Hynes pyeloplasty, as in Jayakumar's cases.⁴ Non-dismembered pyeloplasty techniques wouldn't have allowed to relieve the kinking due to the

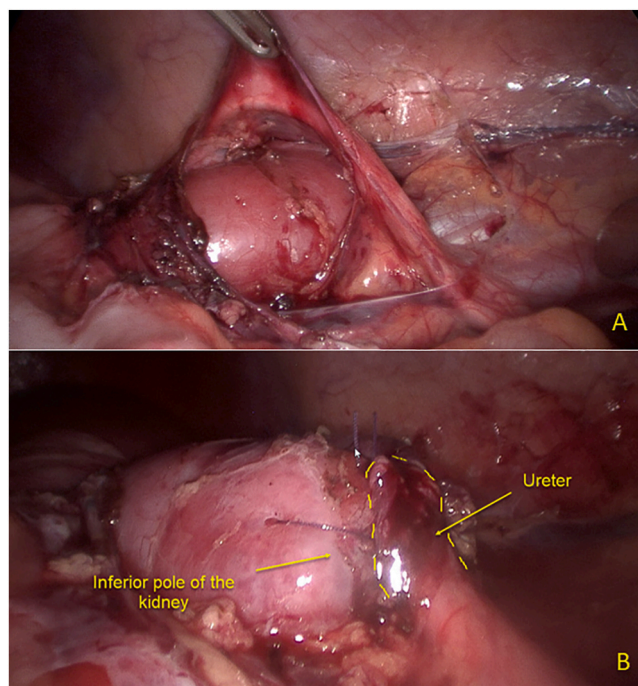


Fig. 2. Ureterocalicostomy. A. Before. B. After.

lateral orientation of the pelvis. We chose to perform an ureterocalicostomy on the inferior calyx, presenting a thinning of the cortex. The risk of secondary stenosis of the parenchymal tract or leak was minimized by sufficient inverted funnel shaped parenchymal resection and urothelial-urothelial anastomosis. By dismembering, we obtained a larger (spatulated) distal ureter than a latero-lateral ureterocalicostomy without sectioning the ureter would have allowed because of the tension on the ureter.

Ureterocalicostomy has been proven to be a safe and efficient procedure in children as in adults, and an appropriate primary procedure in particular anatomical situations. Its laparoscopic feasibility in children has also been demonstrated, although more frequently reported in older children than our patient.⁵

Conclusion

In the case of complicated kidney malrotation, radiological work-up

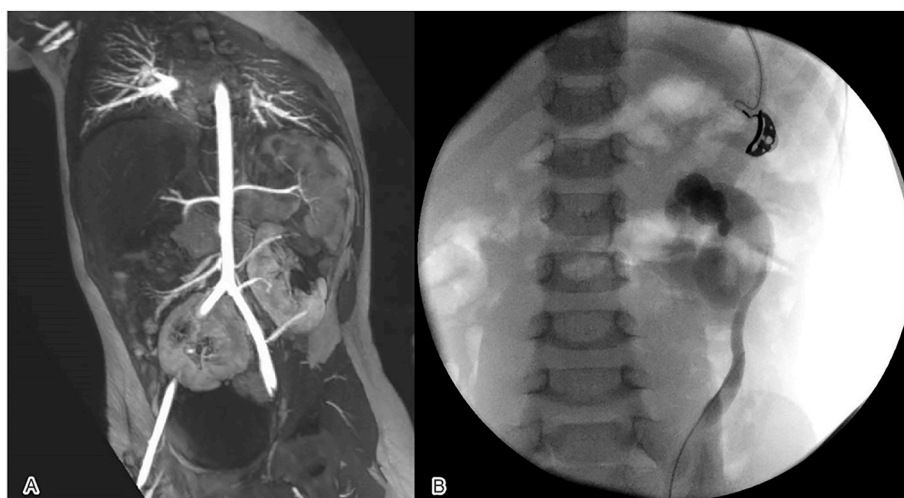


Fig. 1. Radiological work-up: A. Abdominal angio-MRI. B. Retrograde pyelogram.

is essential for planning surgical strategy. Laparoscopic ureterocalicostomy is a feasible and safe option, even in small children, when confronted with atypical anatomic features.

Author contribution

N Divjak: Data collection, Manuscript writing.
J Birraux: Manuscript editing.
H Chehade: Manuscript editing.
O Sanchez: Manuscript writing.

Section heading

Congenital Anomalies/Anatomical Variants

Declaration of competing interest

The authors declare that they have no conflict of interest.

References

1. Cochetoux B, Mounier-Vehier C, Gaxotte V, McFadden EP, Francke JP, Beregi JP. Rare variations in renal anatomy and blood supply: CT appearances and embryological background. A pictorial essay. *Eur Radiol.* 2001;11(5):779–786.
2. Massicot RE, Ferracci S, Uzel AP. [Malrotated kidney causing prenatal giant hydronephrosis]. *Morphologie.* 2018;102(337):91–96.
3. Collura G, De Dominicis M, Patricolo M, Caione P. Hydronephrosis due to malrotation in a pelvic ectopic kidney with vascular anomalies. *Urol Int.* 2004;72(4):349–351.
4. Jayakumar S, Antao BA, Ninan GK. Pyeloplasty for pelvi-ureteric junction obstruction in malrotated kidneys in children. *Eur J Pediatr Surg.* 2012;22(4):279–282.
5. Lobo S, Mushtaq I. Laparoscopic ureterocalicostomy in children: the technique and feasibility. *J Pediatr Urol.* 2018;14(4):358–359.