

How-to-do-it

Towards no-scar cardiac surgery – minimally invasive access through umbilicus for aortic valve replacement

Martins Kalejs^{*}, Enrico Ferrari, Ludwig Karl von Segesser

Department of Cardio-Vascular Surgery, Centre Hospitalier Universitaire Vaudois, CHUV, BH10-275, Rue du Bugnon 46, CH-1011 Lausanne, Switzerland

Received 26 January 2009; received in revised form 15 June 2009; accepted 18 June 2009; Available online 28 July 2009

Abstract

There is an ever-growing trend towards less-invasive procedures in all fields of medicine. We designed an animal study to prove the concept that trans-apical aortic valve replacement from an incision within the umbilicus through a single channel for instruments is feasible, which would be a major leap towards no-scar cardiac surgery. In three adult pigs, after creating a single 3-cm incision at a place where the human umbilicus would be, we introduced a 30F sheath through a tunnel created by an endoscopic vein-harvesting device up to the cardiac apex, through it and up to the left ventricle simulating the approach for trans-apical aortic valve replacement. We used a standard Amplatzer nitinol occluder to seal the defect in ventricle wall later. The animals were followed up for 1 h. Blood loss was minimal, and no tamponade occurred in any of the animals. In addition, we performed a test with water column static pressure to evaluate the impact of preclotting on the sealing properties of the occluders: 1 min flow-through was 2860 ± 176 ml for the standard occluders and 348 ± 56 ml for preclotted occluders ($p < 0.001$).

© 2009 European Association for Cardio-Thoracic Surgery. Published by Elsevier B.V. All rights reserved.

Keywords: Minimally invasive cardiac surgery; No-scar surgery; Trans-catheter valve replacement; Occluder; Trans-apical access

1. Introduction

Off-pump trans-left-ventricular approach for aortic valve replacement currently is being performed through a small mini-thoracotomy and has been proven to be safe and effective [1,2]. The limiting factor for this procedure to become even less invasive is the closure of left ventricular defect after catheter withdrawal. It has been reported previously that repair of the left ventricle with a standard sutureless closing device in a thoracoscopic fashion is feasible [3]. The goal of this study is to prove that distant single-orifice, single-channel access is sufficient to perform a trans-apical valve replacement procedure, which would be a major leap towards no-scar cardiac surgery.

As the use of a standard occluder was shown previously to be associated with increased blood loss during the procedure [3], as a side task we decided to test preclotting of the occluder with non-heparinised blood to minimise blood loss during the procedure.

2. Materials and methods

An acute animal study was performed in three adult pigs, 51 ± 2.0 kg weight, under general anaesthesia, equipped with arterial and venous pressure lines and electrocardiograph (ECG) monitoring. In five adult human male volunteers, we measured the mean distance between sternum and umbilicus to be 15.6 ± 1.8 cm, which was used in the animals as a reference. At this distance, a single incision of approximately 3 cm was performed (Fig. 1), a tunnel towards the sternum just above the abdominal fascia was created in a blunt fashion. A retractor for endoscopic vein harvesting (Karl Storz, Tuttlingen, Germany) equipped with a camera was introduced into the tunnel. Subsequently, using endoscopic scissors, an incision in the fascia was created just below the xyphoid process to reach the pericardium. A window of at least 3×4 cm was created in the pericardium and the apex of the heart was visualised (Video 1). From this point, the procedure of gaining trans-apical access and closing it using a 12-mm Amplatzer occluder for interventional septal defect closure (Aga, Golden Valley, MN, USA) is described in detail in Tozzi et al. [3]. In brief, it was as follows: after heparin injection (100 IU kg^{-1}), under fluoroscopic control, we punctured the heart, positioned a guide wire and inserted a 30F sheath through the tunnel and the cardiac apex, into the left ventricle, simulating the approach for aortic valve replacement. Subsequently, the sheath was

^{*} Corresponding author. Current address: Center of Cardiac Surgery, Pauls Stradins Clinical University Hospital, Pilsonu str. 13, Riga, LV-1002, Latvia. Tel.: +371 6 7069221; fax: +371 6 7069421.

E-mail address: martins.kalejs@stradini.lv (M. Kalejs).

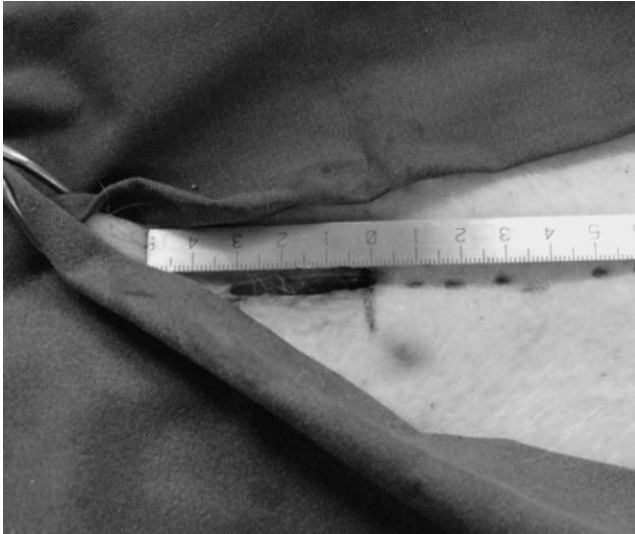

Fig. 1. An incision 3 cm long 16 cm below the sternum.

removed and the ventricle access closed with an occluder (Fig. 2A and Video 1, see Video 2 for a fluoroscopic view). Animals were then followed up for 1 h, and haemodynamics data were collected. The animals were subsequently sacrificed and gross anatomy examination of the heart carried out (Fig. 2B). Pericardial bleeding was assessed using a conventional suction device during the procedure.

All the pigs received care in compliance with 'the Guide for the Care and Use of Laboratory Animals' by the Institute of Laboratory Animal Resources (NIH publication 85–23, revised 1985). The protocol was approved by the Institutional Committee on Animal Research.

To test the effectiveness of preclotting the occluder in minimising blood loss, we conducted a separate *in vitro* test using three standard and three occluders preclotted with unheparinised blood for 15 min with a water column static pressure equal to 100 mmHg, measuring the flow of water through the occluders in 1 min.

We used Student's *t*-test for comparing means and chose a *P*-value below 0.05 as the threshold for statistical significance. Values are reported as mean \pm standard deviation (SD).

3. Results

Six occluders were successfully deployed in three animals (two occluders per animal; second after 1-h interval) in <1 min per device. Endoscopic view was acceptable and allowed for visualisation of coronary vasculature (Video 1). No major arrhythmias were detected during or after device deployment. Baseline mean blood pressure was 61 ± 15 mmHg, it decreased to 52 ± 10 mmHg during deployment and remained stable at 64 ± 12 mmHg after the procedure. Precise measurements of blood loss with standard occluders were performed by Tozzi et al. previously and were found to be 800 ± 20 ml in 3 h (100 ± 5 ml in 3 h when using a pericardial cuff) [3] and were not repeated, blood loss with preclotted occluders was 100 ± 30 ml in 1 h (~ 80 ml during deployment).

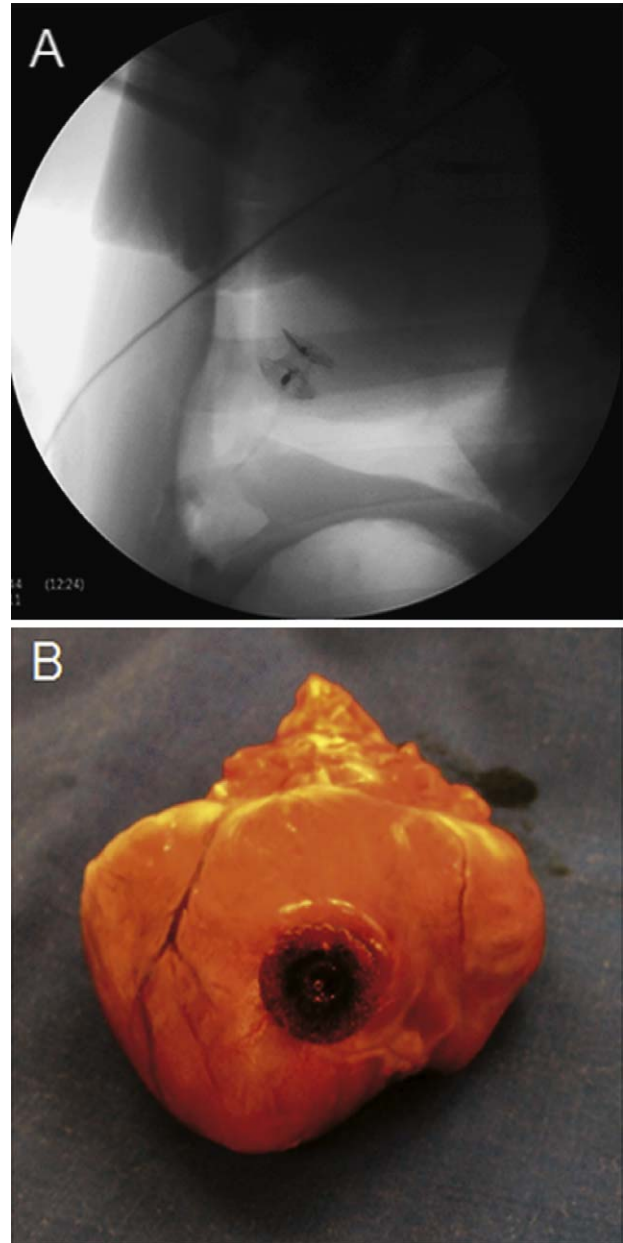


Fig. 2. (A) Fluoroscopic view of the occluder after deployment. (B) Gross anatomical view of heart after necropsy with the occluder correctly positioned.

In the *in vitro* test, 1-min flow-through was 2860 ± 176 ml for the standard occluders and 348 ± 56 ml for preclotted occluders ($p < 0.001$) with a flow reduction by a ratio of 8.2 – similarly to the decrease in blood loss by a ratio of 9.4 when using a pericardial cuff, as reported by Tozzi et al. [3].

4. Conclusions

Although the results are very preliminary, we have demonstrated that a defect in the free wall of the left ventricle can be safely closed in an endoscopic fashion during a single-port procedure, leaving a nearly invisible scar in the

region of the umbilicus. This finding readily suggests a possible new surgical access for trans-apical aortic valve replacement offering better cosmesis, less pain and faster recovery, with all the benefits of the trans-apical route.

Our *in vitro* tests and *in vivo* experience have shown that preclotting of the occluder with non-heparinised blood significantly improves its sealing capabilities by reducing liquid flow through the device.

References

- [1] Vahanian A, Alfieri OR, Al-Attar N, Antunes MJ, Bax J, Cormier B, Cribier A, De Jaegere P, Fournial G, Kappetein AP, Kovac J, Ludgate S, Maisano F, Moat N, Mohr FW, Nataf P, Pierard L, Pomar JL, Schofer J, Tornos P, Tuzcu M, van Hout B, von Segesser LK, Walther T. Transcatheter valve implantation for

patients with aortic stenosis: a position statement from the European Association of Cardio-Thoracic Surgery (EACTS) and the European Society of Cardiology (ESC), in collaboration with the European Association of Percutaneous Cardiovascular Interventions (EAPCI). *Eur J Cardiothorac Surg* 2008;34(1):1–8.

- [2] Walther T, Falk V, Kempfert J, Borger MA, Fassel J, Chu MW, Schuler G, Mohr FW. Transapical minimally invasive aortic valve implantation; the initial 50 patients. *Eur J Cardiothorac Surg* 2008;33(6):983–8.
- [3] Tozzi P, Pawelec-Wojtalik M, Bukowska D, Argitis V, von Segesser LK. Endoscopic off-pump aortic valve replacement: does the pericardial cuff improve the sutureless closure of left ventricular access? *Eur J Cardiothorac Surg* 2007;31(1):22–5.

Appendix A. Supplementary data

Supplementary data associated with this article can be found, in the online version, at [doi:10.1016/j.ejcts.2009.06.040](https://doi.org/10.1016/j.ejcts.2009.06.040).

Editorial comment

Access to the heart by a trans-umbilical incision

Keywords: NOTES; Trans-catheter aortic valve replacement; Minimal invasive

Natural orifice transluminal endoscopic surgery (NOTES) is an intensely discussed and an emerging technique in visceral surgery today. Embracing the NOTES philosophy and principles, Dr Kalejs and his colleagues took an innovative approach to both access to the heart and closure of the perforated ventricle [1]. They introduced the concept of single-port surgery in trans-apical trans-catheter valve implantation, by combining endoscopic and endovascular techniques. The endoscopic part consisted of a subcutaneous tunnel from the umbilicus to the pericardium and its fenestration. The cardiac apex was dilated creating a 1-cm defect and was successfully closed by endovascular means using a guide wire, sheath and a preclotted Amplatzer septal defect occluder. The results in six animals of a porcine model showed successful haemostatic sealing, with an operation wound that would be normally obfuscated in the human umbilicus 'button'.

As mentioned by the authors, single-port surgery or NOTES for valve replacement is not unrealistic, and may be a vision compatible with the future. Although trans-apical trans-catheter valve implantation requires only a small thoracotomy, the recommended trans-umbilical access is intriguing, as it is even less invasive with the potential of lowering morbidity. This technique could bring particular benefits in high-risk patients such as octogenarians with previous bypass surgery requiring valve replacement. In NOTES, considerable challenges remain, such as the safety of the access technique, the adequate closure of the perforated organ and sterility issues. The development of highly flexible instruments including triangulation of the visual field is crucial. Another objective is the achievement of adequate

retraction of the organs while working through a single channel. Despite these difficulties and the fact that NOTES is technically extremely demanding with a steep learning curve, it obviously gains more and more momentum. However, 'until we are forced to accept disruptive technologies ... either driven by patient demand, ... superiority of the therapy, and/or favourable reimbursement, most of us will not leave the comfort of our current practices ... for something new [2].' NOTES may have advantages and should be therefore considered as a promising new technique.

References

- [1] Kalejs M, Ferrari E, von Segesser LK. Towards no-scar cardiac surgery—minimally invasive access through umbilicus for aortic valve replacement. *Eur J Cardiothorac Surg* 2009;36:773–5.
- [2] Smith CD. Stretta: ahead of its time or has its time passed? *Gastrointest Endosc* 2007;65:373–4.

Bettina Marty*, Bernhard Egger
*Clinic of Surgery, Cantonal Hospital, 1700 Fribourg,
Switzerland*

*Corresponding author. Tel.: +41 26 426 7185;
fax: +41 26 426 7314

E-mail address: martyb@h-fr.ch
(B. Marty)

Available online 22 August 2009

[doi:10.1016/j.ejcts.2009.07.001](https://doi.org/10.1016/j.ejcts.2009.07.001)