

Mémoire de Maîtrise en médecine No 916

Assessment of myocardial edema and
area-at-risk in acute myocardial infarction
by CMR: Evaluation of a novel
T₂-mapping method

Étudiant

Cédric Bongard

Tuteur

Prof. Jürg Schwitter
Médecin chef, Service de Cardiologie, CHUV,
Directeur du CRMC du CHUV

Co-tuteur

Dr. Ruud van Heeswijk
CIBM/CHUV

Expert

Prof. Matthias Stuber
Directeur du CIBM/CHUV

Lausanne, décembre 2012

Acknowledgements

I owe sincere and earnest thankfulness to my supervisor, Professor Jürg Schwitter, for the guidance he showed me throughout this master thesis and my dissertation writing. I would also like to show my gratitude to Doctor Ruud van Heeswijk for his considerable support and encouragement all along my work. I am very grateful to have been part of such a dynamic team which has conducted this research. Besides I would like to thank to my love, Aurélie, my family and my friends for their great moral support.

Cédric Bongard

1 Table of content

2	Abstract.....	4
3	Background.....	5
4	Method.....	6
4.1	T2-mapping sequence.....	6
4.2	Volunteer study.....	6
4.3	Patient study.....	7
4.4	Statistical analyses.....	8
5	Results.....	9
5.1	Volunteer Studies.....	9
5.1.1	Inter-observer variability.....	9
5.1.2	Intra-observer variability.....	10
5.1.3	T ₂ -maps and phantom use.....	11
5.2	Patient study.....	12
5.2.1	Inter-observer variability.....	12
5.2.2	Agreement with the X-ray coronary angiography.....	13
6	Discussion.....	14
6.1	Volunteer studies.....	14
6.1.1	Inter-observer variability.....	14
6.1.2	Intra-observer variability.....	14
6.1.3	T ₂ -maps and phantom use.....	15
6.2	Patient studies.....	15
6.2.1	Inter-observer variability.....	15
6.2.2	Agreement with the X-ray coronary angiography.....	15
6.3	Study limitations.....	16
7	Conclusion.....	16
8	References.....	17

2 Abstract

Objectives. The goal of this study is to evaluate a T_2 -mapping sequence by: (i) measuring the reproducibility intra- and inter-observer variability in healthy volunteers in two separate scanning session with a T_2 reference phantom; (2) measuring the mean T_2 relaxation times by T_2 -mapping in infarcted myocardium in patients with subacute MI and compare it with patient's the gold standard X-ray coronary angiography and healthy volunteers results.

Background. Myocardial edema is a consequence of an inflammation of the tissue, as seen in myocardial infarct (MI). It can be visualized by cardiovascular magnetic resonance (CMR) imaging using the T_2 relaxation time. T_2 -mapping is a quantitative methodology that has the potential to address the limitation of the conventional T_2 -weighted (T_2W) imaging.

Methods. The T_2 -mapping protocol used for all MRI scans consisted in a radial gradient echo acquisition with a lung-liver navigator for free-breathing acquisition and affine image registration. Mid-basal short axis slices were acquired. T_2 -maps analyses: 2 observers semi-automatically segmented the left ventricle in 6 segments accordingly to the AHA standards. 8 healthy volunteers (age: 27 ± 4 years; 62.5% male) were scanned in 2 separate sessions. 17 patients (age : 61.9 ± 13.9 years; 82.4% male) with subacute STEMI (70.6%) and NSTEMI underwent a T_2 -mapping scanning session.

Results. In healthy volunteers, the mean inter- and intra-observer variability over the entire short axis slice (segment 1 to 6) was 0.1 ms (95% confidence interval (CI): -0.4 to 0.5, $p = 0.62$) and 0.2 ms (95% CI: -2.8 to 3.2, $p = 0.94$, respectively. T_2 relaxation time measurements with and without the correction of the phantom yielded an average difference of 3.0 ± 1.1 % and 3.1 ± 2.1 % ($p = 0.828$), respectively. In patients, the inter-observer variability in the entire short axis slice (S1-S6), was 0.3 ms (95% CI: -1.8 to 2.4, $p = 0.85$). Edema location as determined through the T_2 -mapping and the coronary artery occlusion as determined on X-ray coronary angiography correlated in 78.6%, but only in 60% in apical infarcts. All except one of the maximal T_2 values in infarct patients were greater than the upper limit of the 95% confidence interval for normal myocardium.

Conclusions. The T_2 -mapping methodology is accurate in detecting infarcted, i.e. edematous tissue in patients with subacute infarcts. This study further demonstrated that this T_2 -mapping technique is reproducible and robust enough to be used on a segmental basis for edema detection without the need of a phantom to yield a T_2 correction factor. This new quantitative T_2 -mapping technique is promising and is likely to allow for serial follow-up studies in patients to improve our knowledge on infarct pathophysiology, on infarct healing, and for the assessment of novel treatment strategies for acute infarctions.

Key Words: longitudinal studies; myocardial infarct; T_2 -mapping; cardiovascular MRI.

3 Background

Cardiovascular diseases (CVD) are the major cause of death in the Western world and contributed to 34% of deaths in the United States in 2007. The incidence of heart failure (HF) is 1% in the population older than 65 years; only coronary artery disease (CAD) and stroke are more frequent (1). The clinical management of these diseases still remains a challenge. In this context, cardiac imaging plays an important role for the diagnostic work-up of these patients with HF and CAD, for the evaluation of therapeutic responses in these patients, and for the understanding of its pathophysiology. Development and improvement of techniques such as Cardiovascular Magnetic Resonance (CMR) are aimed at addressing this problem.

One physical property of tissue that can be probed by CMR is its T_2 relaxation time. It is associated with the free water content in the tissue, thus providing a contrast between different types of tissues (2). Its usefulness has been demonstrated by the use of T_2 -weighted (T_2W) sequences in the evaluation of myocardial ischemia and infarction. In these situations, due to the hypoperfusion of the tissue, an intracellular edema develops. When ischemia persists, the myocytes undergo apoptosis which is paralleled by a subsequent extracellular edema formation (3). T_2W sequences allow to observe the presence of a myocardial edema associated with an acute or a subacute ischemic event, since the tissue edema typically persists up to one week after the ischemic event (4). Moreover, the edematous region has been shown to correspond to the area-at-risk (AAR) in infarct patients (4). In other words, this non-invasive CMR imaging modality allows the evaluation of the tissue properties over time, thus giving the possibility to investigate the pathophysiology of acute infarctions and infarct healing, as well as evaluate treatment strategies in acute infarctions.

Besides this, myocardial edema occurs within other acute cardiac diseases that have similar clinical patterns. This includes myocarditis, transplant rejection or certain types of cardiomyopathies. T_2W imaging allows the appreciation of the distribution of the edema and thus the detection of various acute cardiac diseases (5).

However, conventional T_2W imaging, which is based on turbo-spin echo (TSE) pulse sequences, has several limitations. First, these sequences are qualitative only, and they are depending on the imaging parameters defined by the examination protocol. Other limitations apply to the sequences themselves. They are prone to artifacts due to the bright signal of stagnant blood in the cardiac cavities potentially interfering with the signal measured in the subendocardium. The signal is furthermore affected by the surface coil intensity variation, and it is distorted in case of cardiac motion (6). This means an alternative approach that could measure T_2 relaxation times directly would be highly desirable.

To address this problem, a novel quantitative free-breathing T_2 -mapping technique at 3 T has been developed and tested (7). It incorporates a radial gradient echo (GRE) image acquisition and an adiabatic T_2 preparation (T2prep). It is aimed at eliminating the limitations of conventional T_2W imaging by directly measuring the T_2 relaxation time (5,8).

In this study, we evaluated the T_2 -mapping sequence by (i) measuring the intra- and inter-observer reproducibility in healthy volunteers in two separate scanning sessions with a special focus on a segmental analysis, and (ii) by comparing the location of the infarct-related myocardial edema with the infarct-related coronary artery as documented by X-ray coronary angiography in patients with subacute myocardial infarctions.

4 Method

4.1 T_2 -mapping sequence

As described by van Heeswijk et al. (7), the sequence was first tested numerically to establish the optimal fitting parameters. The simulation parameters for the T_2 fitting included myocardial relaxation times of $T_2 = 45$ ms and $T_1 = 1,470$ ms (9) at 3 T; a segmented k-space radial GRE acquisition with a repetition time (TR) of 7.6 ms and an echo time (TE) of 2.8 ms; a navigator delay of 40 ms; and 3 different T2prep times (TE_{T2prep}) of 0, 30 and 60 ms.

The T2prep-GRE was implemented on two 3T magnetic resonance scanners (Magnetom Trio and Verio, Siemens Healthcare, Erlangen, Germany) with a 32-channel chest coil (Invivo, Gainesville, Florida) and the sequence parameters as described.

The sequence has a temporal resolution of 97 ms and a spatial resolution of $1.25 \times 1.25 \times 5$ mm³. For respiratory motion suppression during free-breathing, a lung-liver respiratory navigator was used (10). For each T_2 -map, the imaging sequence was repeated with the 3 incremental TE_{T2prep} (0, 30 and 60 ms). After acquisition of the 3 source images, affine coregistration was applied to increase the accuracy of the T_2 -mapping before the final computation of the T_2 -maps was performed using a custom-written Matlab (The Mathworks, Natick, Massachusetts) analysis tool.

4.2 Volunteer study

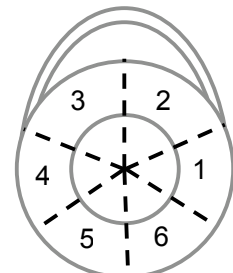
The protocol of our study was reviewed and accepted by the local ethics committee and written informed consent was obtained from all participants prior to the procedure. To assess the reproducibility of the T2prep T_2 -mapping methodology, 8 volunteers (6 men, age: 27 ± 4 years) underwent 2 separate scanning sessions. To evaluate inter-study reproducibility the volunteers had to leave the scanner room between the two sessions and they were then

repositioned in the scanner for the second examination. To obtain an external reference T_2 value in each measurement, a phantom with known T_1 and T_2 values similar to those of the healthy myocardium was positioned on the volunteer. After shimming of the heart based on a local gradient-echo field map (11), T_2 -maps were obtained in a short-axis view. Two different phantoms were used with T_2 relaxation times of 43.1 ms and 48.3 ms in order to find the best shape for the patient's comfort and to facilitate its presence in the field of view.

To calculate the intra- and inter-variability, 2 observers (R.B.v.H., C.B.) used a custom-written Matlab script to semi-automatically select the entire left ventricle (LV) as well as a homogeneous and central area of the phantom. The following analysis procedure was defined: (i) selection of the center of the LV; (ii) selection of the anterior and posterior septal insertions on the LV; (iii) delineation of the outer and the inner myocardium; and (iv) the region of interest in the phantom. The script then divided the myocardium into 6 segments according to the AHA standards (Table 1) (12) and calculated the average T_2 relaxation time for each of the 7 areas. Myocardial segments 1 and 2 are associated to the left anterior descending coronary artery (LAD), 2 and 3 to the left circumflex coronary artery (LCX) and 5 and 6 to the right coronary artery (RCA). Then, using the known T_2 value of the phantom, a corrected myocardial T_2 value was calculated. The inter- and intra-observer variability as well as the percentage difference between the original and the calculated T_2 relaxation for both scanning session was then calculated.

Table 1: basal myocardial segments for CMR according to the AHA standards.

Seg.	Name
1	anterior
2	anteroseptal
3	inferoseptal
4	inferior
5	inferolateral
6	anterolateral



4.3 Patient study

The T_2 -mapping methodology was used in 17 patients (14 men, age: 70 ± 13 years) in a subacute phase after percutaneous coronary intervention (PCI) of a ST-segment elevation myocardial infarction (STEMI) or non-STEMI (NSTEMI). A detailed description of the patients is given in the Table 2. Short axis T_2 maps through the center of the infarct region (as determined on the cine CMR images) were acquired in all patients.

The T_2 maps were processed and the myocardium was segmented in 6 areas semi-automatically as described above but without the use of the phantom as a T_2 relaxation time reference. According to the values obtained in healthy volunteers, the elevated T_2 values were considered to represent the infarcted edema region. Both observers (R.B.v.H., C.B.) collected the average T_2 values and associated standard deviation.

First, to test the reproducibility of the method in patients, the inter-observer variability for each segment was calculated. Then, according to the X-ray coronary angiography results, we classified the patients by the infarct-related coronary artery and compared the T_2 relaxation times of the myocardial segment with the highest value to the upper limit of the 95% confidence interval of the corresponding segment as determined in the volunteers.

4.4 Statistical analyses

Statistical tests were paired or unpaired 2-tailed Student t tests, where $p < 0.05$ was considered statistically significant. Intra- and inter-observer variabilities were calculated by Bland-Altman analysis. Average difference was calculated as the difference between two values divided by their average and expressed as percentage.

Table 2: patient's characteristics.

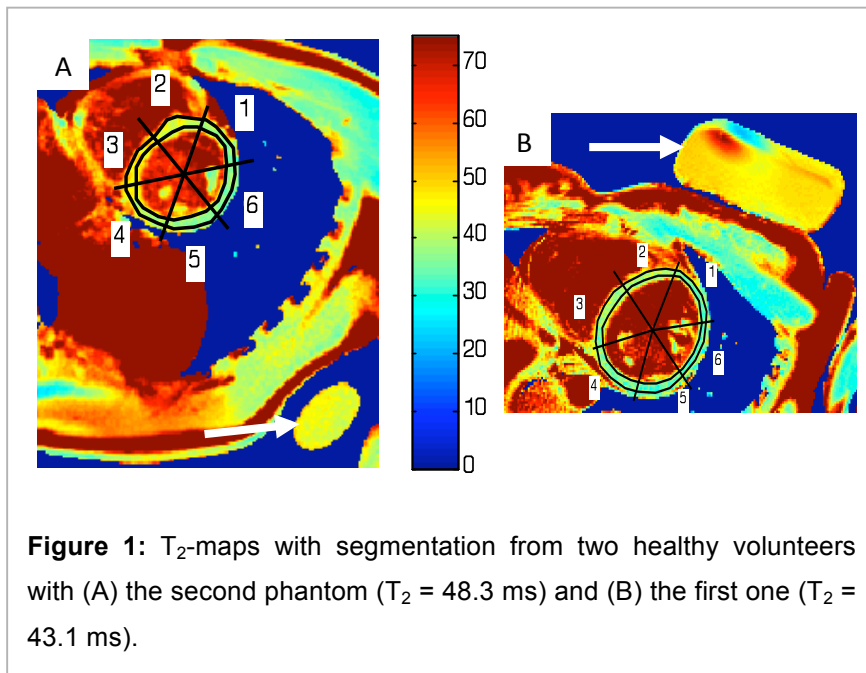
General	
Male / Total [n]	14 / 17
Age [y]	61.9 ± 13.9
Cardiovascular Risk Factors	
BMI [kg/m ²]	26.5 ± 2.7
HTA [n]	12
Hyperlipidemia [n]	14
Diabetes [n]	3
Smoking [n]	6
Previous MI [n]	6
Previous CABG [n]	2
Previous PCI [n]	4
Myocardial infarct	
Type	
STEMI [n]	12
NSTEMI [n]	5
LVEF CMR [%]	49.7 ± 12.3
Treatment	
Thrombectomy [n]	11
Predilatation [n]	5
Bare Metal Stent [n]	2
Drug Eluting Stent [n]	10
ReoPro [n]	6
Clopidogrel [n]	7
Prasugrel [n]	8

BMI: Body Mass Index; HTA, Arterial Hypertension; CABG: Coronary Artery Bypass Graft; PCI: Percutaneous Coronary Intervention, LVEF: Left Ventricular Ejection Fraction.

5 Results

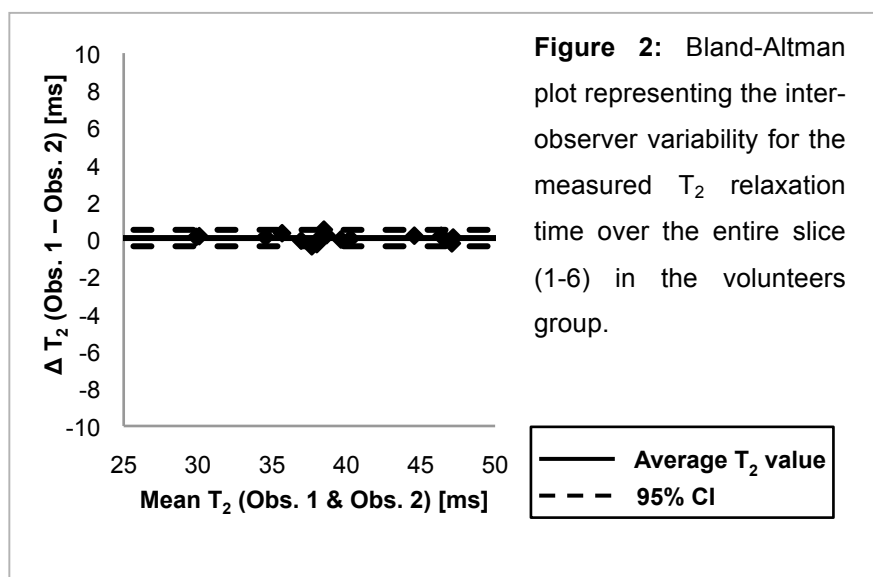
5.1 Volunteer Studies

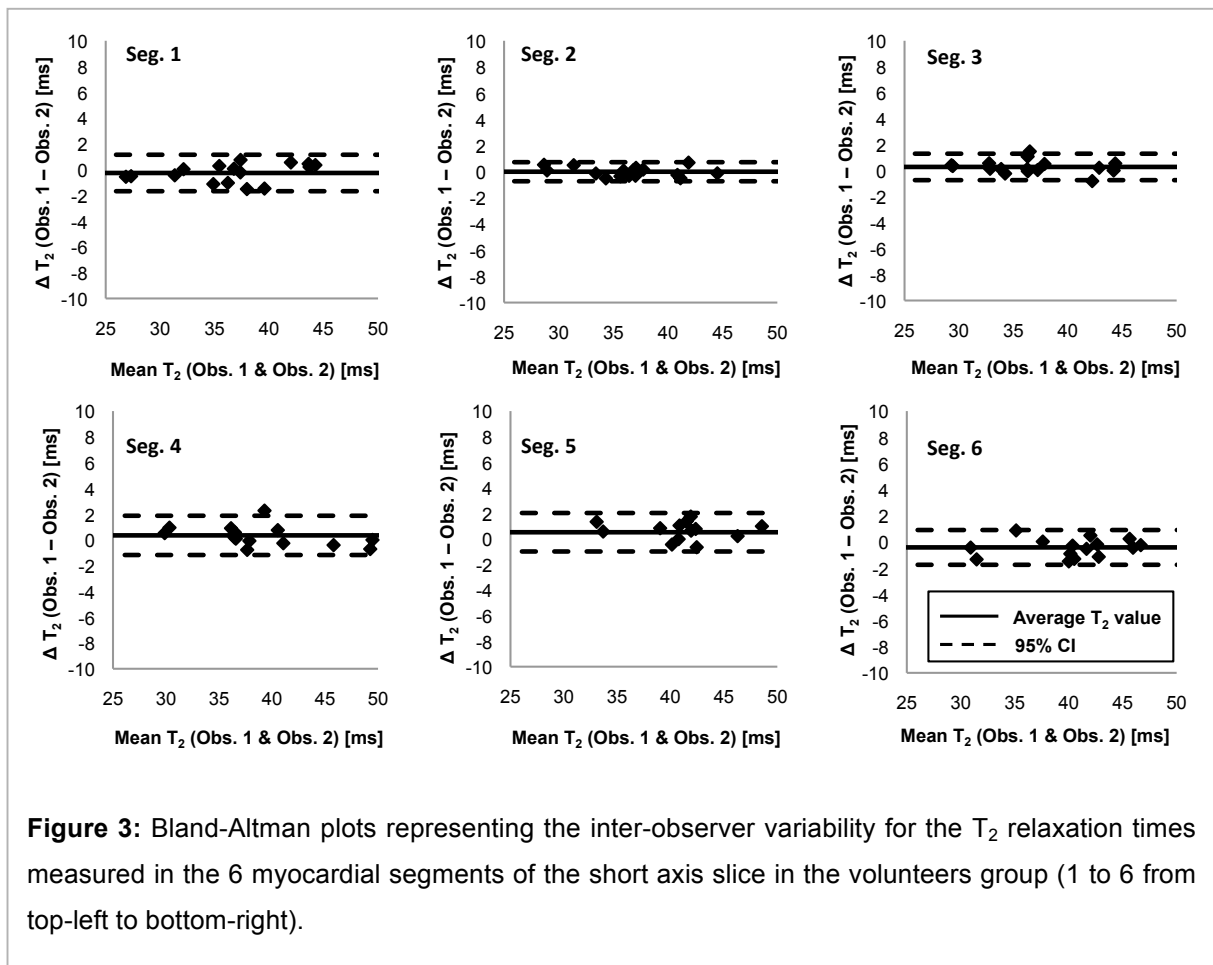
The methodology as described was successfully applied to 8 volunteers and 16 T_2 maps were generated and analyzed with the scripts (Figure 1). The two different phantoms are shown in this figure.



5.1.1 Inter-observer variability

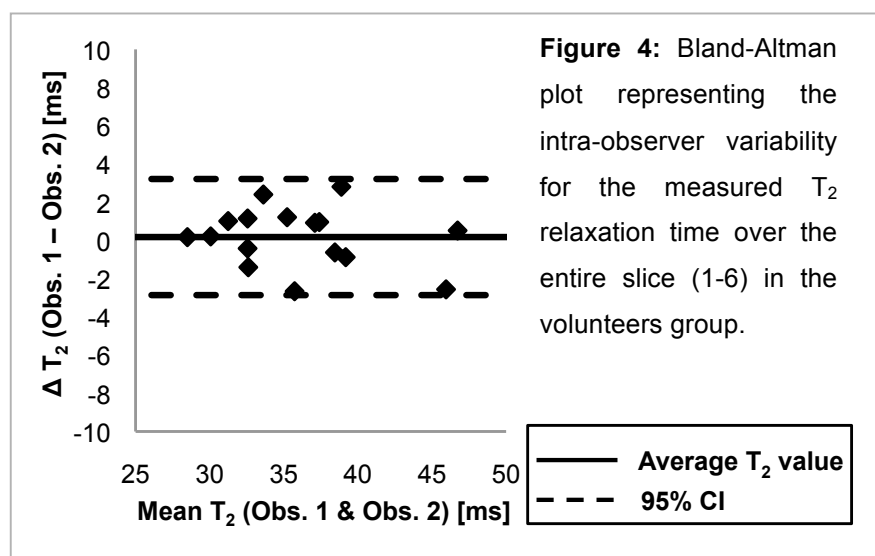
The mean inter-observer variability over the entire short axis slice (segment 1 to 6) was 0.1 ms (95% confidence interval (CI): -0.4 to 0.5, $p = 0.62$) (Figure 2). The results for each segments are -0.3 ms (95% CI: -1.7 to 1.2, $p = 0.21$) for the segment (S) 1, -0.0 ms (95% CI: -0.7 to -0.7, $p = 0.22$) for S2, 0.3 ms (95% CI: -0.7 to 1.3, $p = 0.57$) for S3, 0.4 ms (95% CI: -1.2 to 1.9, $p = 0.47$) for S4, 0.5 ms (95% CI: 1.0 to 2.0, $p = 0.52$) for S5 and -0.4 ms (95% CI: -1.7 to 0.9, $p = 0.39$) for S6 (Figure 3).

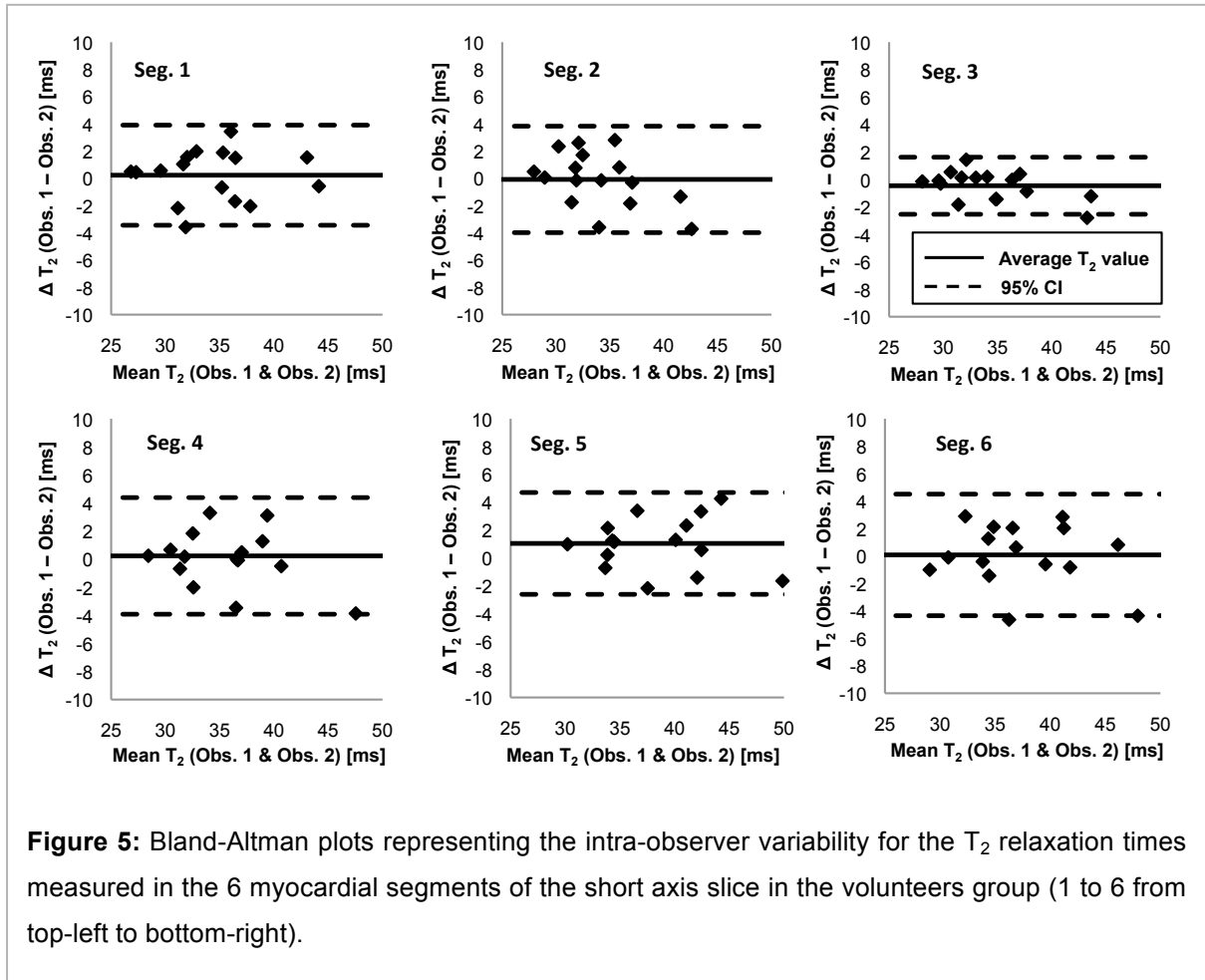




5.1.2 Intra-observer variability

The mean intra-observer variability averaged on the entire short axis slice (segment 1 to 6) is 0.2 ms (95% CI: -2.8 to 3.2, $p = 0.94$) (Figure 4). If we consider the segments, the results were 0.2 ms (95% CI: -3.4 to 3.9, $p = 0.64$) for S1, -0.1 ms (95% CI: -4.0 to 3.8, $p = 0.78$) for S2, -0.5 ms (95% CI: -2.5 to 1.6, $p = 0.78$) for S3, 0.2 ms (95% CI: -3.9 to 4.4, $p = 0.79$) for S4, 1.1 ms (95% CI: -2.6 to 4.7, $p = 0.79$) for S5 and 0.1 ms (95% CI: -4.3 to 4.5, $p = 0.80$) for S6 (Figure 5).





5.1.3 T_2 -maps and phantom use

We compared the T_2 relaxation time with and without the correction of the phantom and obtained an average difference of $3.0 \pm 1.1 \%$ and $3.1 \pm 2.1 \%$ ($p = 0.828$), respectively. The details for each of the 6 segments are shown in Table 3.

Table 3: Average difference between the 2 observers the T_2 relaxation time with and without the correction factor of the phantom known T_2 relaxation time.

Seg.	Average difference [%]		p -value
	T_2	$T_{2, \text{corr}}$	
1	4.6 ± 2.4	4.2 ± 2.5	0.699
2	2.4 ± 1.9	4.3 ± 3.0	0.111
3	4.3 ± 2.4	3.0 ± 2.4	0.131
4	3.1 ± 2.8	3.7 ± 3.1	0.597
5	3.9 ± 2.3	3.1 ± 2.4	0.445
6	2.2 ± 1.7	4.0 ± 3.1	0.091
1-6	3.0 ± 1.1	3.1 ± 2.1	0.828

5.2 Patient study

The protocol was completed in 18 patients and 18 T_2 -maps were processed in all STEMI and NSTEMI patients. Among these, and due to motion artifacts or wrong slice placement, three and two T_2 -maps were judged uninterpretable by the observers, respectively, and thus a total of 15 T_2 -maps were analyzed.

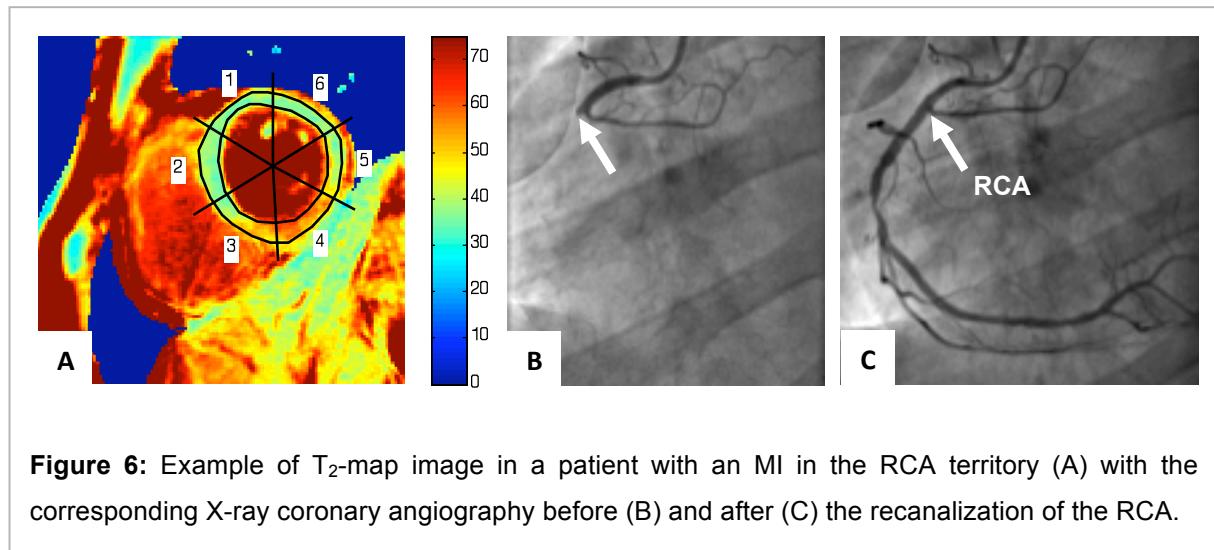


Figure 6: Example of T_2 -map image in a patient with an MI in the RCA territory (A) with the corresponding X-ray coronary angiography before (B) and after (C) the recanalization of the RCA.

5.2.1 Inter-observer variability

The inter-observer variability was also studied in the patient group. For the entire short axis slice (S1-S6), we measured a mean difference of 0.3 ms (95% CI: -1.8 to 2.4, $p = 0.85$) (Figure 8). The results for each segment are 0.4 ms (95% CI: -2.5 to 3.3, $p = 0.88$) for S1, -0.3 ms (95% CI: -4.3 to 3.7, $p = 0.92$) for S2, 0.1 ms (95% CI: -3.1 to 3.3, $p = 0.97$) for S3, 0.3 (95% CI: -3.1 to 3.7, $p = 0.89$), 0.8 ms (95% CI: -1.8 to 3.4, $p = 0.67$) and 0.4 ms (95% CI: -4.1 to 4.9, $p = 0.89$) (Figure 9).

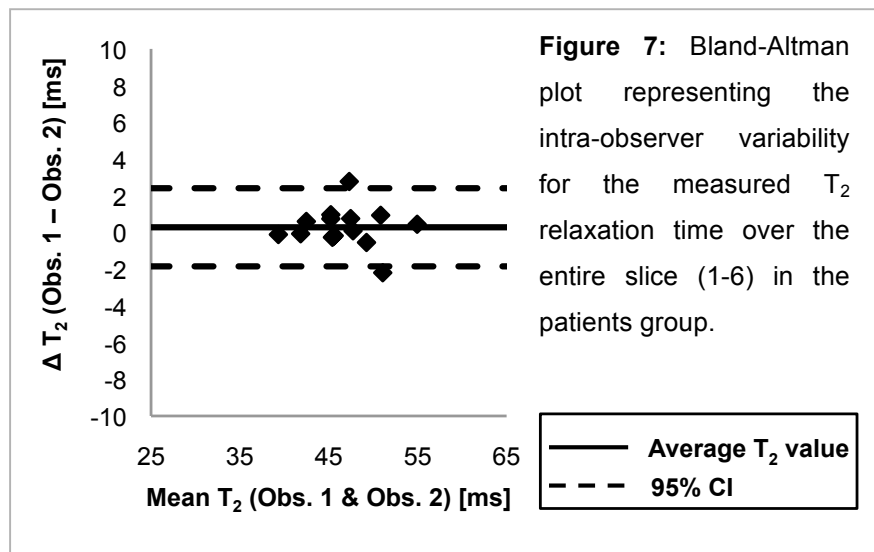
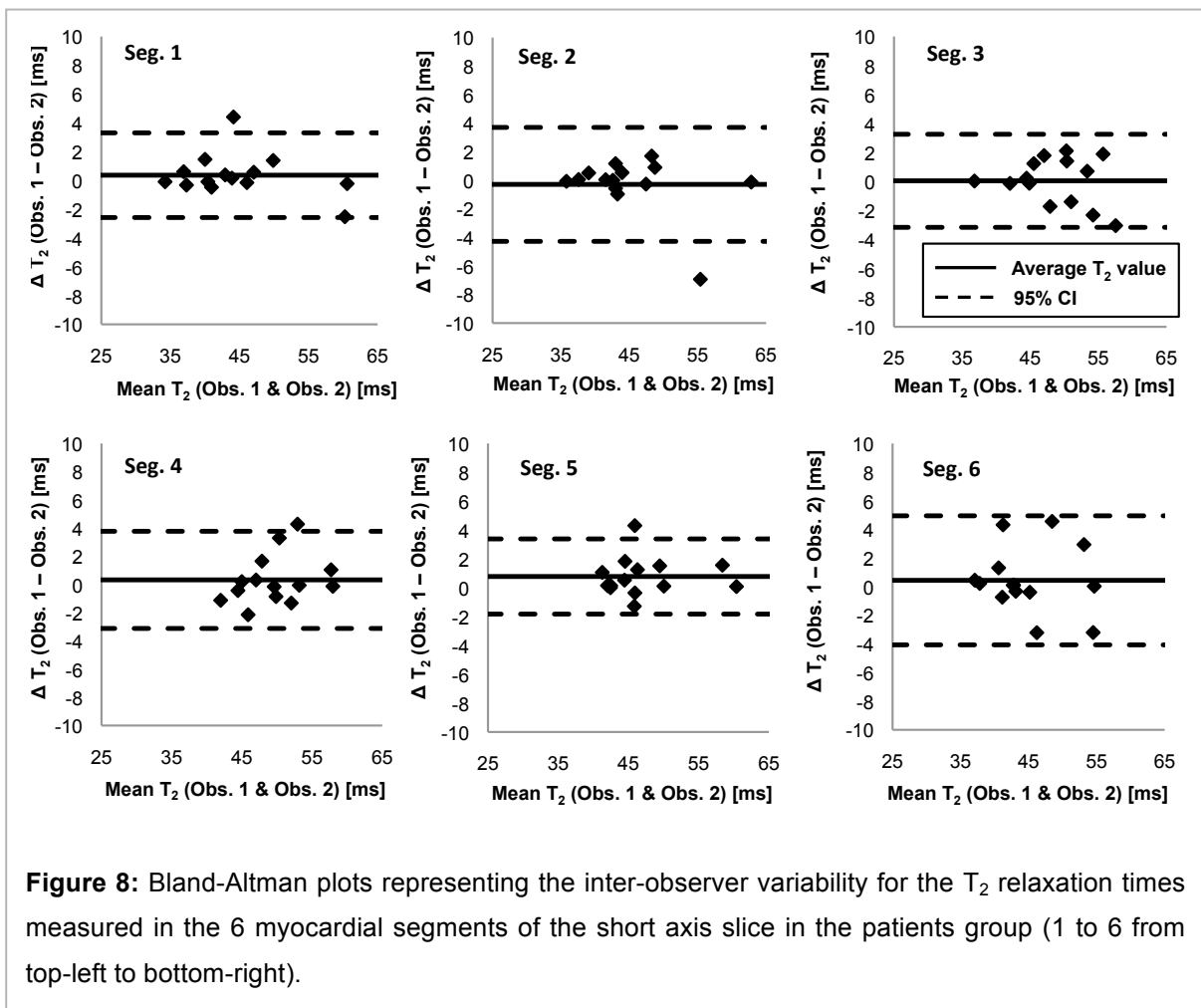
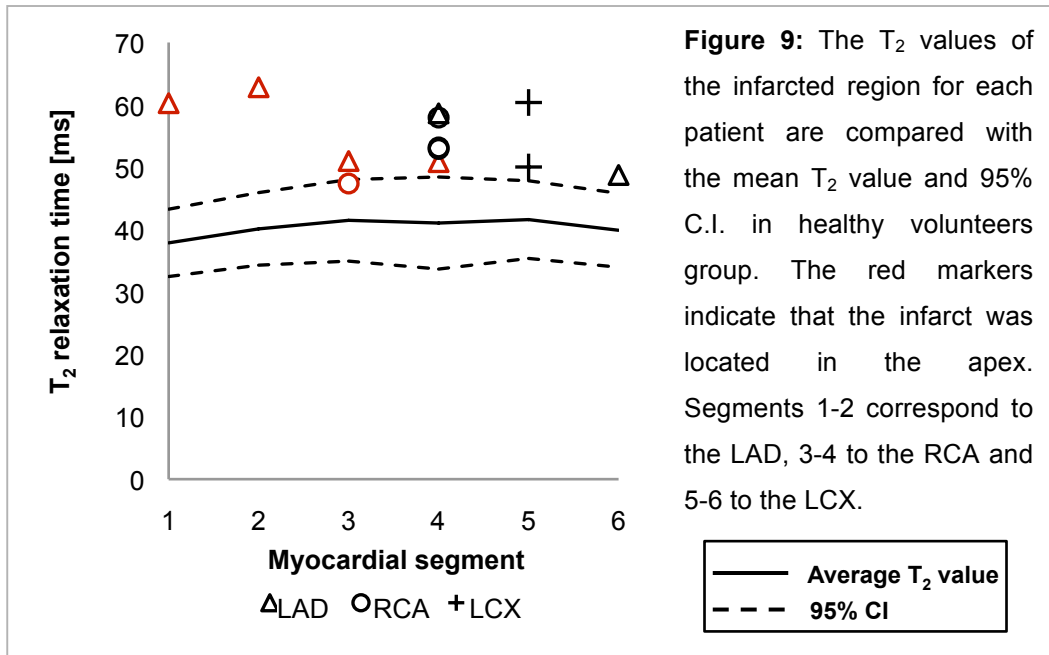


Figure 7: Bland-Altman plot representing the intra-observer variability for the measured T_2 relaxation time over the entire slice (1-6) in the patients group.



5.2.2 Agreement with the X-ray coronary angiography

Finally, to compare the T_2 -mapping method to the X-ray coronary angiography, we considered the patients with a single-vessel disease ($n = 12$). The results shown in Figure 9 indicate that the edema location as determined through the T_2 -mapping and the coronary artery occlusion as determined on X-ray coronary angiography correlated in 78.6% with the segments with the highest mean T_2 values. This proportion increased to 100% if we excluded the patients with an infarct in the LAD territory in which only 50% corresponded to the expected territory. Regarding to the level of the infarct, 33.3% were apical (80% in the LAD territory and 20% in the RCA territory) with only 60% of agreement with the expected culprit coronary artery territory in this subgroup. In addition, all except one of the maximal T_2 values in patients were greater than the upper limit of the 95% confidence interval for normal myocardium.



6 Discussion

6.1 Volunteer studies

6.1.1 Inter-observer variability

The results of the Bland-Altman analysis of the inter-observer variability are acceptable with a mean difference of only 0.1 ± 0.4 ms for the entire slice. This result is comparable to those obtained in each slice with the 95% confidence intervals remaining inferior to ± 1.6 ms. It implies that the T_2 -mapping sequence yields an acceptable reproducibility on a segmental level if the observers follow the protocol to delineate the myocardium.

6.1.2 Intra-observer variability

Considering the intra-observer variability, the mean difference for the entire slice was 0.2 ms (95% CI: -2.9 to 3.2 ms) with no significant differences between the 2 scanning sessions. The variability in each segment was comparable to the inter-observer variability result and the 95% confidence interval was smaller than ± 4.8 ms. This result supports the idea that T_2 -mapping can be used for serial T_2 measurements in order to follow the recovery of the myocardium for example after an acute myocardial infarction.

These promising results on the inter- and intra-observer variability offer the possibility to use this T_2 -mapping methodology in research and clinical practice in order to measure the response to therapeutic interventions and to monitor the infarct healing process over time with representative and quantitative endpoints.

6.1.3 T₂-maps and phantom use

The correction of the T₂ measures with the phantom T₂ relaxation time did not reduce the average inter- and intra-observer differences, thus, indicating that the T₂-mapping methodology (without a phantom correction) is robust enough to be used in a follow-up setting. This result can be explained by the use of the same MRI system, thus reducing the benefits of a reference T₂ relaxation time to correct the ones measured in the myocardium. A further study including different systems should offer to evaluate the use of a phantom in serial scanning sessions.

6.2 Patient studies

6.2.1 Inter-observer variability

We repeated the inter-observer analysis in the patient group and obtained a mean difference of 0.3 ms (95% CI: -1.8 to 2.4, $p = 0.85$) on the entire slice, which is similar to the results of the volunteers study where we obtained 0.1 ms (95% CI: -0.4 to 0.5, $p = 0.62$), thus showing no significant differences between the observers. Considering the segments separately, the mean difference did not exceed 0.4 ms with a maximum 95% confidence interval of ± 4.6 ms. These measures were realized without a phantom correction according to the results given above.

6.2.2 Agreement with the X-ray coronary angiography

The results obtained in this comparison are promising. Except for one case, all the maximum T₂ values were superior to 48.3 ms, which is the upper limit of the 95% confidence interval for the segmental T₂ (as measured in the 8 volunteers). This means that the T₂ relaxation time of the infarcted area can be measured with sufficient precision and reproducibility with this novel methodology to discriminate infarct edema from the healthy regions on a segmental basis.

Moreover, accordingly to the AHA standards, the comparison with the X-ray coronary angiography shows that 100% of our measures to detect infarct edema matched the infarcted territory in patients with an occlusion of the RCA and the LCX. However, this proportion dropped to 78.6% when we included the LAD. Considering the infarct level in the left ventricle, the agreement for the basal and mid-ventricular infarcts was high with 88.9%, but was lower for the apical infarcts with only 60% of agreement. An explanation to this ascertainment could be the anatomical variation of the coronary arteries vascularization patterns, particularly for the LAD, which often is the main coronary artery with a large associated territory. Despite this, these mismatches cannot be entirely explained by this fact. Our conclusions are limited by the fact that we acquired one slice only at the basal or mid-

ventricular level and thus, we are not able to evaluate adequately the edema at the apical level. Nevertheless, these results are promising with a high agreement level with the X-ray coronary angiography, considering the limits of our methodology that did not allow to evaluate the edema along the left ventricle's long axis and that used a standardized myocardial segmentation classification not accounting for the inter-individual variability of the coronary arteries. To address these limitations, a more detailed review of the coronary arteries based on the X-ray angiography and a multi-slice acquisition scanning protocol should be undertaken.

6.3 Study limitations

The first limitation of this study is that the scans were performed in a single centre. The same study in another centre might yield different results. Another limitation is that the two scanning sessions to assess the reproducibility of the methodology in the volunteer studies were performed the same day, meaning that it did not consider the potential differences of T_2 relaxation time over a longer time interval. In addition, since we acquired only a single slice, reproducibility might be different in different slice positions. Finally, we lack a direct edema imaging method as a standard reference to prove that this new technique accurately detect myocardial edema, but so far as we know, such a technique for in vivo studies is not available.

7 Conclusion

This study demonstrated that the novel T_2 -mapping methodology is accurate in detecting infarcted, i.e. edematous tissue in patients with subacute infarcts. This study further demonstrated that this T_2 -mapping technique is reproducible and robust enough to be used on a segmental basis for edema detection without the need of a phantom to yield a T_2 correction factor.

A comparison with the conventionally used TSE T_2 -weighted imaging should be performed to assess the potential superiority of this quantitative T_2 -mapping presented in this work.

This new quantitative T_2 -mapping technique is promising and is likely to allow for serial follow-up studies in patients to improve our knowledge on infarct pathophysiology, on infarct healing, and for the assessment of novel treatment strategies for acute infarctions.

Finally, this new quantitative T_2 -mapping approach could also be useful in the setting of myocarditis, cardiomyopathies, or heart transplant rejection, as these disease entities are suspected to involve tissue edema formation.

8 References

1. Roger VL, Go AS, Lloyd-Jones DM, Benjamin EJ, Berry JD, Borden WB, et al. Executive Summary: Heart Disease and Stroke Statistics--2012 Update: A Report From the American Heart Association. *Circulation*. 2012 Jan 3;125(1):188–97.
2. Higgins CB, Herfkens R, Lipton MJ, Sievers R, Sheldon P, Kaufman L, et al. Nuclear magnetic resonance imaging of acute myocardial infarction in dogs: alterations in magnetic relaxation times. *The American journal of cardiology*. 1983 Jul;52(1):184–8.
3. Abdel-Aty H, Tillmanns C. The use of cardiovascular magnetic resonance in acute myocardial infarction. *Curr Cardiol Rep*. 2010 Jan;12(1):76–81.
4. Raman S V, Simonetti OP, Winner 3rd MW, Dickerson JA, He X, Mazzaferri Jr EL, et al. Cardiac magnetic resonance with edema imaging identifies myocardium at risk and predicts worse outcome in patients with non-ST-segment elevation acute coronary syndrome. *J Am Coll Cardiol*. 2010;55(22):2480–8.
5. Eitel I, Friedrich M. T2-weighted cardiovascular magnetic resonance in acute cardiac disease. *Journal of Cardiovascular Magnetic Resonance*. 2011;13(1):13.
6. Verhaert D, Thavendiranathan P, Giri S, Mihai G, Rajagopalan S, Simonetti OP, et al. Direct T2 quantification of myocardial edema in acute ischemic injury. *JACC: Cardiovascular imaging*. Elsevier Inc.; 2011 Mar;4(3):269–78.
7. Van Heeswijk RB, Feliciano H, Bongard C, et al. Free-Breathing Magnetic Resonance T2-mapping of the Heart for Longitudinal Studies at 3T. *JACC: imaging*. 2012 Dec;5(12):1231-9.
8. Giri S, Chung Y, Merchant A, Mihai G, Rajagopalan S, Raman S V, et al. T2 quantification for improved detection of myocardial edema. *Journal of Cardiovascular Magnetic Resonance*. 2009;13:1–13.
9. Stanisz GJ, Odobina EE, Pun J, Escaravage M, Graham SJ, Bronskill MJ, et al. T1, T2 relaxation and magnetization transfer in tissue at 3T. *Magnetic Resonance in Medicine*; 2005;54(3):507–12.
10. Ehman RL, Felmlee JP. Adaptive technique for high-definition MR imaging of moving structures. *Radiology*. 1989 Oct 1;173 (1):255–63.
11. Schär M, Vonken E-J, Stuber M. Simultaneous B0- and B1+-Map acquisition for fast localized shim, frequency, and RF power determination in the heart at 3 T. *Magnetic Resonance in Medicine*; 2010;63(2):419–26.
12. Cerqueira MD, Weissman NJ, Dilsizian V, Jacobs AK, Kaul S, Laskey WK, et al. Standardized Myocardial Segmentation and Nomenclature for Tomographic Imaging of the Heart A Statement for Healthcare Professionals From the Cardiac Imaging Committee of the Council on Clinical Cardiology of the American Heart Association. *Circulation*. 2002;105:539–42.