

available at www.sciencedirect.com
journal homepage: www.europeanurology.com/eufocus



Prostate Cancer

Is There an Impact of Transperineal Versus Transrectal Magnetic Resonance Imaging–targeted Biopsy on the Risk of Upgrading in Final Pathology in Prostate Cancer Patients Undergoing Radical Prostatectomy? An European Association of Urology-Young Academic Urologists Prostate Cancer Working Group Multi-institutional Study

Fabio Zattoni^{a,*}, Giancarlo Marra^b, Alberto Martini^c, Veeru Kasivisvanathan^{d,e}, Jeremy Grummet^f, Timothy Harkin^f, Guillaume Ploussard^g, Jonathan Olivier^h, Peter K. Chiuⁱ, Massimo Valerio^j, Alessandro Marquis^k, Paolo Gontero^k, Hongqian Guo^l, Junlong Zhuang^l, Mark Frydenberg^{m,n}, Daniel Moon^{o,p}, Alessandro Morlacco^a, Alexander Kretschmer^q, Francesco Barletta^c, Isabel Heidegger^r, Derya Tilki^{s,t,u}, Roderick van den Bergh^v, Fabrizio Dal Moro^a, Alberto Briganti^c, Francesco Montorsi^c, Giacomo Novara^a, Giorgio Gandaglia^c, on behalf of the EAU-YAU Prostate Cancer Working Party

^a Department Surgery, Oncology and Gastroenterology, Urologic Unit, University of Padova, Padova, Italy; ^b Department of Urology, Institut Mutualiste Montsouris, Paris, France; ^c Unit of Urology/Division of Oncology, Gianfranco Soldera Prostate Cancer Laboratory, IRCCS San Raffaele Scientific Institute, Milan, Italy; ^d Division of Surgery and Interventional Science, University College London, London, UK; ^e Department of Urology, University College London Hospitals NHS Foundation Trust, London, UK; ^f Department of Surgery, Monash University, Melbourne, Australia; ^g Department of Urology, La Croix du Sud Hospital, Toulouse, France; ^h Department of Urology, Lille University, Lille, France; ⁱ Division of Urology, Department of Surgery, The Chinese University of Hong Kong, Hong Kong; ^j Urology Department, Lausanne University Hospital, Lausanne, Switzerland; ^k University of Turin, Molinette Hospital, Turin, Italy; ^l Department of Urology, Nanjing Drum Tower Hospital, Medical School of Nanjing University, Institute of Urology, Nanjing University, Nanjing, Jiangsu, People's Republic of China; ^m Department of Surgery, Faculty of medicine, Nursing and Health Sciences, Monash University, Melbourne, Australia; ⁿ Cabrini Institute, Cabrini Health, Malvern, VIC, Australia; ^o Royal Melbourne Clinical School, University of Melbourne, Melbourne, Australia; ^p Peter MacCallum Cancer Centre, Melbourne, Australia; ^q Department of Urology, University Hospital Munich, Campus Großhadern, Ludwig-Maximilians University, Munich, Germany; ^r Department of Urology, Medical University Innsbruck, Innsbruck, Austria; ^s Martini-Klinik Prostate Cancer Center, University Hospital Hamburg-Eppendorf, Hamburg, Germany; ^t Department of Urology, University Hospital Hamburg-Eppendorf, Hamburg, Germany; ^u Department of Urology, Koc University Hospital, Istanbul, Turkey; ^v Department of Urology, St Antonius Hospital, Utrecht, The Netherlands

Article info

Article history:

Accepted January 25, 2023
Available online 4 February 2023

Abstract

Background: The concordance rates of transperineal (TP) versus transrectal (TR) prostate biopsies with radical prostatectomy (RP) specimen have been assessed poorly in men diagnosed with magnetic resonance imaging (MRI)-targeted biopsy (TBx).

* Corresponding author. Department Surgery, Oncology and Gastroenterology, Urologic Unit, University of Padova, Via VIII Febbraio, 2, 35122 Padova, Italy. Tel. +39 0498 212 931.

<https://doi.org/10.1016/j.euf.2023.01.016>

2405-4569/© 2023 The Authors. Published by Elsevier B.V. on behalf of European Association of Urology. This is an open access article under the CC BY license (<http://creativecommons.org/licenses/by/4.0/>).

Associate Editor: Christian Gratzke

Keywords:

Prostate Cancer
Diagnosis
Transrectal
Transperineal
Prostate biopsy
Targeted biopsy

Objective: To evaluate International Society of Urological Pathology (ISUP) concordance rates between the final pathology at RP and MRI-TBx or MRI-TBx + random biopsy (RB) according to the biopsy approach.

Design, setting, and participants: A multi-institutional database included patients diagnosed with TP or TR treated with RP.

Intervention: TP-TBx or TR-TBx of the prostate.

Outcome measurements and statistical analysis: The ISUP grade at biopsy was compared with the final pathology. A multivariable logistic regression analysis (MVA) was performed to assess the association between the biopsy approach (TP-TBx vs TR-TBx) and ISUP upgrading, downgrading, concordance, and clinically relevant increase (CRI).

Results and limitations: Overall, 752 (59%) versus 530 (41%) patients underwent TR versus TP. At the MVA, TP-TBx was an independent predictor of upgrading (odds ratio [OR] 0.6, 95% confidence interval [CI] 0.4–0.9, $p < 0.01$) and improved concordance relative to the final pathology (OR 1.7, 95% CI 1.2–2.5, $p < 0.01$) after adjusting for age, cT stage, Prostate Imaging Reporting and Data System, number of targeted cores, prostate-specific antigen, and prostate volume. Moreover, TP-TBx was associated with a lower risk of CRI than TR-TBx (OR 0.7, $p < 0.01$). This held true when considering patients who underwent MRI-TBx + RB (OR 0.6, $p < 0.01$). The inclusion of men who had RP represents a potential selection bias.

Conclusions: The adoption of TP-TBx compared with TR-TBx may reduce the risk of upgrading and improve the concordance of biopsy grade with the final pathology. The TP approach decreases the odds of CRI with improved patient selection for the correct active treatment.

Patient summary: In this report, we evaluated whether transperineal (TP) targeted biopsy (TBx) may improve the concordance of clinically significant prostate cancer with the final pathology in comparison with transrectal (TR) TBx in a large worldwide population. We found that TP-TBx might increase concordance compared with TR-TBx. Adding random biopsies to target one increases accuracy; however, concordance with the final pathology is overall suboptimal even with the TP approach.

© 2023 The Authors. Published by Elsevier B.V. on behalf of European Association of Urology. This is an open access article under the CC BY license (<http://creativecommons.org/licenses/by/4.0/>).

1. Introduction

The widespread diffusion of multiparametric magnetic resonance imaging (MRI) recently revolutionized the diagnostic pathway of prostate cancer (PCa), where its implementation allowed clinicians to target regions of interest for biopsy (TBx) with an improved detection of high-grade cancers and fewer low-grade cancers in comparison with systematic transrectal ultrasound (TRUS) biopsy alone [1,2]. MRI-based predictive models can individualize the likelihood of clinically significant PCa, improve the selection of candidates for prostate biopsy, and reduce the number of unnecessary biopsies performed [3]. Moreover, some authors hypothesized that information obtained at MRI could be used for prognostic and staging purposes. To this end, an MRI-targeted approach might improve preoperative stratification in PCa patients who are candidates for radical prostatectomy (RP) and reduce the risk of pathologic upgrading compared with a random biopsy (RB) [4].

The use of a transperineal (TP) biopsy is currently recommended by international guidelines including those of the European Association of Urology (EAU) [5] to decrease the risk of severe infections. Furthermore, a targeted biopsy performed with a TP route (TP-TBx) might increase the detection rate of clinically significant PCa in men with MRI-visible lesions compared with transrectal (TR) TBx [6,7]. However, it remains unclear whether TP-TBx may also have some advantages compared with TR-TBx in detecting

higher-grade lesions, which are otherwise occult, or whether this increase in biopsy grade results from selective sampling of higher-grade areas within an otherwise low-grade cancer. Maximization of the rate of concordance between biopsy and final pathology might reduce to the minimum tumor grade misclassification, allowing for the optimal application of staging modalities and treatment allocation. Despite the described advantages of a TBx, this approach alone has also shown downsides by missing a significant number of high-risk cancers [8,9]. The balance of over- and underdetection is challenging. Whether a TBx alone is sufficient or additional systematic biopsies are still needed is an ongoing debate [10,11]. Only limited data suggest that TP-TBx is as good as systematic template TP biopsy [12,13] and that the TP approach may confer an advantage for detecting anterior tumors [14], even in the MRI-TBx era. Owing to these uncertainties, the present study aims to evaluate the rates and risk factors of International Society of Urological Pathology (ISUP) misclassification with either TP-TBx or TR-TBx, and RBs in a contemporary cohort of patients treated with RP.

2. Patients and methods

Internal review board approval for the present study and for retrospective data collection was obtained according to each institution's policy, when required. A total of 1282 patients managed with RP at ten tertiary referral centers were included. [Supplementary Figure 1](#) shows the

patient selection process. All included patients undergoing radical treatment provided written informed consent for surgery. All procedures performed in studies involving human participants were in accordance with the ethical standards of the institutional and/or national research committee and with the 1964 Helsinki Declaration and its later amendments or comparable ethical standards. Institutional review board approval requirement applies to each center due to the observational and retrospective nature of the study.

Patients diagnosed with TP-TBx and TR-TBx were identified, and represented the study and control groups, respectively. Patients with previous treatment for PCa were excluded. For patients who had undergone multiple biopsy sessions, only the last one was considered in this study. Specimen handling was in accordance with the recommendations of the 2019 ISUP consensus [15,16]. Only dedicated urologists with over 5 yr of experience reviewed prostate histology specimens.

2.1. Prostate biopsy techniques

Multiparametric MRI was performed before biopsy according to each institution protocol. MRI was scored in most centers by the Prostate Imaging Reporting and Data System (PI-RADS) version 2 scoring system [17]. All MRI scans were reviewed in each center by expert genitourinary radiologists according to the ESUR/ESUI consensus for the quality requirements for image acquisition, interpretation, and radiologists' training. TBx was performed by experienced urologists with their preferred biopsy approach (TR or TP). Each center contributed only one biopsy approach to reduce the potential selection bias. All TR-TBx and TP-TBx events used a dedicated biopsy fusion software. A median number of 3 (Q1-Q4: 2–4, interquartile range [IQR]: 2) TBx samples were taken from each suspicious lesion. TP-TBx was performed with a brachytherapy grid or freehand technique under general or local anesthesia.

2.2. Covariates and outcomes

Age, prostate-specific antigen (PSA), prostate volume, clinical stage at digital rectal examination, and MRI information were available for all patients included in our study. The outcome of interest was represented by ISUP concordance, upgrading, and downgrading between RP and TBx. Upgrading, downgrading, and concordance were defined, respectively, as an ISUP increase from, decrease from, or equalization to prostate biopsy to final pathology. The ISUP concordance, upgrading, and downgrading were evaluated considering both the greatest ISUP at MRI-TBx and the greatest ISUP at MRI-TBx + RB. Since not every upgrading can be considered equally relevant (ie, upgrades from ISUP 3 to 4 or from 4 to 5 may be considered of limited clinical relevance in most clinical scenarios), a clinically relevant increase (CRI) was defined as any increase from ISUP ≤ 2 to any higher ISUP.

2.3. Statistical analysis

Categorical variables were reported as frequencies, while continuous variables were reported as mean standard deviation for variables with a normal distribution, and as median and IQR for variables with a non-normal distribution. Differences between categorical variables were assessed by using the chi-square test. Differences between continuous variables were assessed by the *t* test or Mann-Whitney *U* test, as appropriate. A multivariable logistic regression analysis for predicting concordance, upgrading, downgrading, and CRI was performed to evaluate the odds ratio (OR) for TP-TBx relative to TR-TBx. The model was adjusted for age, biopsy status (naïve/repeated biopsy), cT stage (cT ≥ 2 vs cT <2), PI-RADS, number of biopsy cores targeted, PSA at biopsy, and prostate volume. Sensitivity analyses were performed after stratifying patients according to the index lesion tumor location (mid/base, apex, peripheral zone, or transition/central zone). Intraclass correlation coefficient

(ICC) and 95% confidence interval (CI) were calculated for MRI-TBx/RB and TBx, respectively, for TR and TP biopsies. The per-patient sensitivity for ISUP score were calculated separately for TR-TBx and TP-TBx. A fusion biopsy reported as negative with a corresponding positive RP specimen was considered as false negative.

The significance for all tests was set at $p < 0.05$. Analyses were performed using SPSS version 23 (IBM, Armonk, NY, USA) and MedCal version 20.210.

3. Results

From December 2014 to November 2020, ten centers (seven from Europe, two from China, and one from Australia) participated in the study. A total of 752 TR-TBx and 530 TP-TBx cases were included. [Table 1](#) lists general demographics and patients' characteristics of the two groups. The overall TBx concordance, upgrading, and downgrading with the final pathology were 47.6% (611/1282), 42.4% (544/1282), and 9.9% (127/1282), respectively.

3.1. Target biopsy alone

[Figure 1](#) shows the concordance, upgrading, and downgrading rates of ISUP scores at biopsy for TR-TBx ([Fig. 1A](#)) and TP-TBx ([Fig. 1B](#)). ISUP upgrading and downgrading were more frequent for TR-TBx than for TP-TBx (respectively, 501% vs 31% and 11% vs 7.7%; $p < 0.01$). ISUP concordance was higher for TP-TBx than for TR-TBx (61% vs 38%; $p < 0.01$). With TBx, an higher CRI was found for TR versus TP (43% vs 24%; $p < 0.01$). [Supplementary Table 1](#) shows the distribution of biopsy ISUP grading by pathologic ISUP grading at RP. A higher ICC was observed for TP-MRI-TBx than for TR-MRI-TBx (0.7 [0.6–0.8] vs 0.6 [0.4–0.7]; [Supplementary Table 1](#)).

The per-patient sensitivity to detect the correct ISUP score was 0.6 (range: 0.41–0.69) and 0.9 (0.88–0.94), respectively, for TR-TBx and TP-TBx ([Supplementary Table 2](#)). At a multivariate analysis, TP-TBx was associated independently with a lower odd of ISUP upgrading (OR 0.6, 95% CI 0.4–0.9, $p < 0.01$) and a higher odd of concordance with the final pathology (OR 1.7, 95% CI 1.2–2.5, $p < 0.01$) than TR-TBx ([Table 2](#)). At the multivariate analysis, a lower odd of CRI was found for TP-TBx than for TR-TBx (OR 0.7, 95% CI 0.5–0.9, $p < 0.01$; [Table 3](#)).

3.2. Target and random biopsy

[Figure 2](#) shows the concordance, upgrading, and downgrading rates of ISUP scores at biopsy for TR-TBx/RB ([Fig. 2A](#)) and TP-TBx/RB ([Fig. 2B](#)). [Supplementary Table 3](#) shows the distribution of biopsy ISUP grading by pathologic ISUP grading at RP. A higher ICC was observed for TP-MRI-TBx/RB than for TR-MRI-TBx/RB (0.8 [0.8–0.9] vs 0.7 [0.7–0.8]; [Supplementary Table 3](#)).

When considering MRI-TBx/RB, a higher CRI was found for TR versus TP (27% vs 12.8%; $p < 0.01$). At the multivariate analysis assessing predictors of concordance, upgrading, and downgrading, TP-TBx/RB had a lower odd of tumor upgrading (OR 0.5, 95% CI 0.3–0.8, $p < 0.01$) than for TR-TBx/RB ([Table 4](#)). At the multivariate analysis assessing

Table 1 – Patients' characteristics^a

	TR (752)	TP (530)	p value
Age, mean (SD)	67.2 (7.5)	66.8 (7.0)	0.2
PSA (ng/ml) at biopsy, median (IQR)	7.5 (5.2–11.7)	6.8 (4.98–10.1)	0.03
PSA density, median (IQR)	0.16 (0.1–0.27)	0.19 (0.13–0.28)	<0.01
Prostate volume (ml), median (IQR)	42 (31–61)	32 (25–54)	<0.01
Biopsy naïve, n (%)	496 (66)	402 (76.3)	<0.01
cT ≥, n (%)	220 (30.5)	287 (54.2)	<0.01
PI-RADS, n (%)			<0.01
3	125 (16.7)	57 (10.7)	
4	375 (49.9)	237 (44.7)	
5	252 (33.5)	236 (44.5)	
Tumor located in the peripheral zone at MRI ^b , n (%)	267 (56.0)	325 (62.4)	0.04
Tumor located in the transition zone/central zone at MRI ^b , n (%)	147 (30.8)	169 (32.4)	0.6
Tumor located in the anterior zone at MRI ^b , n (%)	122 (25.6)	64 (12.3)	<0.01
Tumor located in the apex at MRI, n (%) ^b	90 (30.4)	76 (16.3)	<0.01
Tumor located in the mid-base, n (%) ^b	172 (58.1)	187 (40.0)	<0.01
Type of anesthesia, n (%)			<0.01
Local	751 (99.9)	127 (24.0)	
General	1 (0.1)	403 (76.0)	
ISUP at fusion biopsy, n (%)			<0.01
GG1	117 (15.6)	44 (8.3)	
GG2	222 (29.5)	235 (44.3)	
GG3	69 (9.2)	141 (26.6)	
GG4	90 (12.0)	47 (8.9)	
GG5	79 (10.5)	34 (6.4)	
Negative fusion biopsy and positive standard biopsy, n (%)	175 (23.3)	29 (5.5)	
Greatest ISUP at random + fusion biopsy, n (%)			<0.01
GG1	178 (23.7)	35 (6.6)	
GG2	269 (35.8)	221 (41.7)	
GG3	105 (14.0)	170 (32.1)	
GG4	112 (14.9)	53 (10.0)	
GG5	88 (11.7)	51 (9.6)	
ISUP at RP, n (%)			<0.01
GG1	70 (9.3)	15 (2.8)	
GG2	305 (40.6)	230 (43.4)	
GG3	208 (27.7)	188 (35.5)	
GG4	90 (12.0)	30 (5.7)	
GG5	79 (10.5)	67 (12.6)	
pT ≥3, n (%)	227 (30.2)	287 (54.2)	<0.01
Positive surgical margin at RP specimen, n (%)	195 (26.3)	135 (25.9)	0.9
Concordance (greatest ISUP at MRI-TBx), n (%)	285 (37.9)	326 (61.5)	<0.01
Upgrading (greatest ISUP at MRI-TBx), n (%)	381 (50.7)	163 (30.8)	<0.01
Downgrading (greatest ISUP at MRI-TBx), n (%)	86 (11.4)	41 (7.7)	0.03
Concordance (greatest ISUP at MRI-TBx/RB), n (%)	384 (51.1)	366 (69.1)	<0.01
Upgrading (greatest ISUP at MRI-TBx/RB), n (%)	258 (34.3)	99 (18.7)	<0.01
Downgrading (greatest ISUP at MRI-TBx/RB), n (%)	110 (14.6)	65 (12.3)	0.2
Clinically relevant increase for MRI-TBx, n (%)	327 (43.5)	128 (24.2)	<0.01
Clinically relevant increase for MRI-TBx/RB, n (%)	203 (27)	68 (12.8)	<0.01

GG = grading group; IQR = interquartile range; ISUP = International Society of Urological Pathology; MRI = magnetic resonance imaging; MRI-TBx = MRI-targeted biopsy; MRI-TBx/RB = MRI-targeted biopsy + random biopsy; PI-RADS = Prostate Imaging Reporting and Data System; PSA = prostate-specific antigen; RP = radical prostatectomy; SD = standard deviation; TP = transperineal prostate biopsy; TR = transrectal prostate biopsy.

^a All analyses were performed on available data.

^b Lesions located in overlapping areas were counted independently.

CRI, a lower odd was found for TP-TBx/RB than for TR-MRI-TBx/RB (OR 0.6, 95% CI 0.3–0.9, $p < 0.01$; [Table 3](#)).

3.3. Subgroup analyses

When stratifying patients according to the index lesion location, the use of TP-TBx was associated with significantly higher ORs of ISUP concordance (OR 2.2, 95% CI 1.4–3.5, $p < 0.01$) and lower ORs of ISUP upgrading in the peripheral zone (OR 0.4, 95% CI 0.2–0.7, $p < 0.01$; [Supplementary Table 4](#)). Although the multivariate analysis was adjusted for the biopsy set, a separate analysis was performed

including only biopsy-naïve patients, obtaining similar results (data not shown).

[Supplementary Figure 2](#) shows the concordance, upgrading, and downgrading for TP and TR biopsies in the respective EAU risk groups. The results are presented separately for MRI-TBx/RB and MRI-TBx. Again, TP biopsies have a higher percentage of concordance and lower percentage of upgrading than TR for both intermediate and high EAU risk patients ($p < 0.01$; [Supplementary Tables 5 and 6](#)). Finally, in a subgroup analysis evaluating exclusively biopsies performed under local anesthesia, TP-MRI-TBx confirmed to be an independent predictor of CRI.

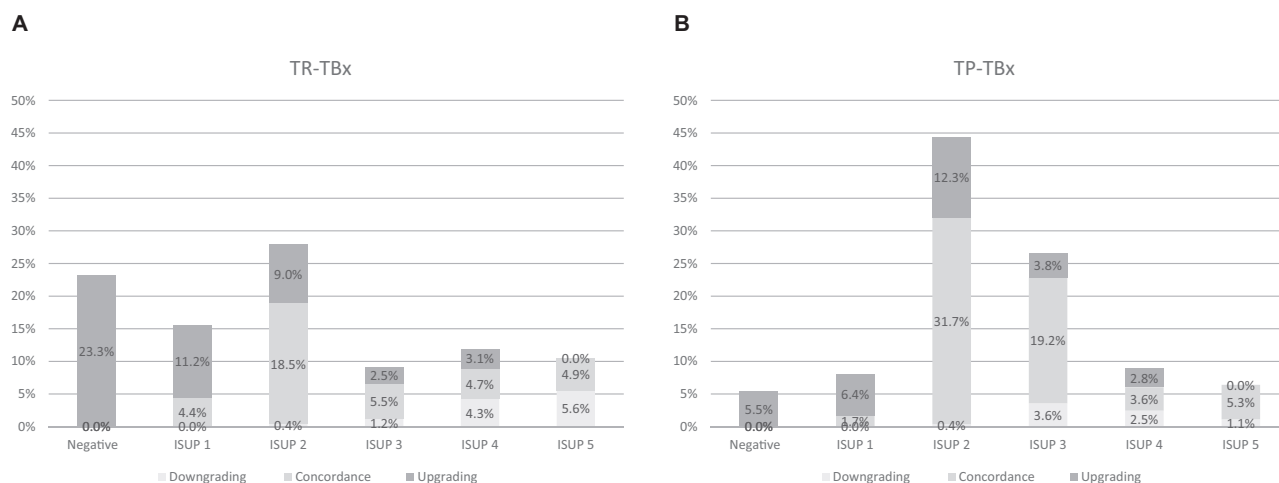


Fig. 1 – Downgrading, concordance, and upgrading rates by ISUP score at biopsy for (A) TR-TBx and (B) TP-TBx. ISUP = International Society of Urological Pathology; TP-TBx = transperineal targeted biopsy; TR-TBx = transrectal targeted biopsy.

Table 2 – Independent predictors of downgrading, upgrading, and concordance with final pathology for MRI-targeted biopsy

Parameter	Downgrading			Concordance			Upgrading		
	OR	95% CI	p value	OR	95% CI	p value	OR	95% CI	p value
TP vs TR	0.9	0.4–1.9	0.9	1.7	1.2–2.5	<0.01	0.6	0.4–0.9	<0.01
Age	1.0	0.9–1.0	0.9	1.0	0.9–1.0	0.8	1.0	0.9–1.0	0.8
Biopsy naïve vs repeated biopsy	1.0	0.5–2.0	0.9	0.8	0.7–1.3	0.8	0.7	0.5–1.5	0.8
cT ≥2 vs cT <2	1.1	0.6–2.1	0.7	1.26	0.9–1.7	0.1	0.7	0.5–1.1	0.1
PI-RADS			0.9			0.03			0.02
3	1	Ref	–	1	Ref	–	1	Ref	–
4	0.8	0.3–2.1	0.6	0.5	0.3–0.8	<0.01	1.9	1.2–3.2	<0.01
5	0.9	0.5–1.8	0.9	0.8	0.6–1.1	0.2	1.2	0.9–1.8	0.2
Number of biopsy cores targeted	1.0	0.9–1.2	0.5	1.1	0.9–1.1	0.1	0.9	0.8–1.0	0.03
PSA at biopsy	1.0	0.9–1.0	0.1	0.6	0.9–1.0	0.6	0.9	0.9–1.0	0.13
Prostate volume	0.9	0.9–1.0	0.4	1.0	0.9–1.0	0.6	1.0	0.9–1.0	0.2

CI = confidence interval; MRI = magnetic resonance imaging; PI-RADS = Prostate Imaging Reporting and Data System; OR = odds ratio; PSA = prostate-specific antigen; Ref = reference; TP = transperineal prostate biopsy; TR = transrectal prostate biopsy.

Table 3 – Independent predictors of clinically relevant increase for MRI-targeted biopsy (MRI-TBx) and fusion biopsy + random biopsy (MRI-TBx/RB)

Parameter	MRI-TBx			MRI-TBx/RB		
	OR	95% CI	p value	OR	95% CI	p value
TP vs TR	0.7	0.5–0.9	0.049	0.6	0.3–0.9	0.01
Age	1.0	0.9–1.1	0.9	0.9	0.9–1.02	0.8
Biopsy naïve vs repeated biopsy	1.2	0.8–1.7	0.3	1.4	0.9–2.2	0.08
cT ≥2 vs cT <2	0.6	0.4–0.8	<0.01	0.5	0.3–0.8	<0.01
PI-RADS			<0.01			<0.01
3	1	Ref	–	1	Ref	–
4	3.5	2.1–5.8	<0.01	2.9	1.6–5.2	<0.01
5	1.7	1.1–2.5	<0.01	1.3	0.8–2.0	<0.01
Number of biopsy cores targeted	0.9	0.9–1.0	0.2	1.0	0.9–1.1	0.6
PSA at biopsy	0.9	0.8–0.9	0.04	0.9	0.9–1.0	0.6
Prostate volume	1.0	0.9–1.0	0.4	0.9	0.9–1.0	0.9

CI = confidence interval; MRI = magnetic resonance imaging; PI-RADS = Prostate Imaging Reporting and Data System; OR = odds ratio; PSA = prostate-specific antigen; Ref = reference; TP = transperineal prostate biopsy; TR = transrectal prostate biopsy.

4. Discussion

The interest towards the TP approach remains high not only in terms of reduction of infections, but also for the ability to define the exact PCa aggressiveness and location within the prostate. This is especially true for patients who are candidates for active treatment or focal treatments as well as in surgical planning for a nerve-sparing RP.

The findings of our study, which evaluated a large cohort from referral centers, are several-fold. First, we demonstrate that TP-TBx is characterized by a higher concordance with the final pathology at RP compared with TR-TBx. Although the overall concordance is in line with previous TBx studies with a value ranging from 40% to 50% [4,18], TP-TBx results in a lower risk of upgrading than TR-TBx. High-level evidence from the PRECISION trial indicates that TBx better

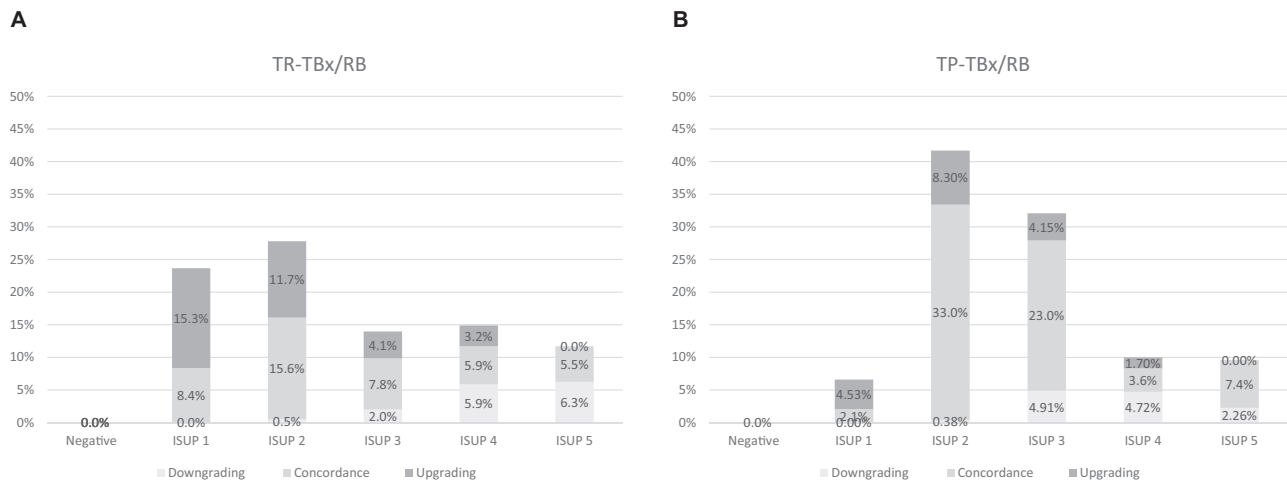


Fig. 2 – Downgrading, concordance, and upgrading rates by ISUP score at biopsy for (A) TR-TBx/RB and (B) TP-TBx/RB. ISUP = International Society of Urological Pathology; RB = random biopsy; TBx = targeted biopsy; TP = transperineal; TR = transrectal.

Table 4 – Independent predictors of downgrading, upgrading, and concordance with final pathology for MRI-targeted + random biopsy (TBx/RB)

Parameter	Downgrading			Concordance			Upgrading		
	OR	95% CI	p value	OR	95% CI	p value	OR	95% CI	p value
TP vs TR	0.9	0.5–1.6	0.8	0.9	0.6–1.5	0.8	0.5	0.3–0.8	<0.01
Age	1.0	0.9–1.1	0.1	1.0	0.9–1.0	0.1	1.0	0.9–1.0	0.9
Biopsy naïve vs repeated biopsy	0.9	0.6–1.6	0.9	0.7	0.5–1.0	0.1	1.2	0.8–1.7	0.3
cT ≥ 2 vs cT <2	1.0	0.6–1.7	0.8	0.9	0.6–1.4	0.6	0.8	0.5–1.2	0.8
PI-RADS			0.6						0.11
3	1	Ref	–	1	Ref	–	1	Ref	–
4	1.0	0.5–2.2	0.9	1.2	0.6–2.1	0.8	1.5	0.9–2.6	0.1
5	1.3	0.8–2.1	0.3	1.1	0.8–1.0	0.6	0.9	0.6–1.3	0.6
Number of biopsy cores targeted	0.9	0.9–1.1	0.9	0.9	0.8–1.1	0.2	0.9	0.9–1.0	0.5
PSA at biopsy	1.0	0.9–1.0	0.3	1.1	0.9–1.0	0.6	1.0	0.9–1.0	0.5
Prostate volume	0.9	0.9–1.0	0.1	1.0	0.9–1.0	0.1	1.0	0.9–1.0	0.8

CI = confidence interval; MRI = magnetic resonance imaging; PI-RADS = Prostate Imaging Reporting and Data System; OR = odds ratio; PSA = prostate-specific antigen; Ref = reference.

detects clinically significant, grade group 2 or higher PCa than the standard TRUS biopsy [2]. With the limitation of the use of high-grade cancer detection as a surrogate for oncologic efficacy in the context of TBx, our results show that TP-TBx better detects aggressive cancers and is not just selective sampling of higher-grade areas within low-grade cancer. TR-TBx may potentially lead to undertreatment of those patients who are undergraded at the initial biopsy. However, if missing or delaying the detection of a high-grade cancer on TR-TBx may raise the risk, only studies with adequate follow-up will be able to really assess the impact of these findings on survival. Second, MRI-TBx might increase the detection of occult or upgrade cancers in patients following biopsy containing low-grade cancer only. This is explained by selective sampling of higher-grade areas inflating ISUP risk groups, resulting in pathologic downgrading at RP [19,20]. Again, TP-TBx had a lower incidence of downgrading at RP (11% of TR-TBx vs 7.7% of TP-TBx). However, we were not able to find a definite preoperative predictor of downgrading. Thus, the selection of patients who could eventually be observed or be eligible for less aggressive therapy rather than proceeding to radical treatment is still to be clarified. Third, MRI-TBx may miss some cancers, but this is compensated by the identification

of lesions that would be missed by a systematic biopsy. There is some evidence that MRI-detected cancers are not oncologically equivalent to those detected by a systematic biopsy. Studies have shown that patients with low-grade tumors on biopsy that are found to have high-grade cancer on surgical pathology have recurrence and death rates close to those for low-risk patients [21]. In our study, the combination of the greatest ISUP grade of MRI-TBx/RB increases the concordance with the final pathology for both TR and TP biopsy. In particular, the main advantage of TP-TBx and TP-TBx/RB is a lower rate of CRI than that of TR-TBx and TR-TBx/RB. This will allow better patient selection for active treatments.

Overall, the diagnostic advantage of TP biopsies compared with TR can be explained by the largest diameter of most prostate tumors along the longitudinal axis (apex to base) [22]. The TP needle is inserted along the same axis. Contrarily, in TR biopsies, the needle penetrates through the anterior-posterior axis and thus even TBx events are centered on a narrower axis. Sampling larger tumor volume may also improve detection of higher-grade tumors, reducing sampling errors associated with tumor heterogeneity [23]. A grade group 2 cancer detected at TR-TBx could be in average a different tumor from a grade group 2 lesions

found at TP-TBx; it is likely to be in average smaller (and if risk is a combination of grade and tumor size, also of lower risk), and this may induce stage/grade migration due to the Will Rogers effect. Fourth, TP-TBx showed improved concordance in the peripheral zone. In the remaining aspect of the gland, after adjusting for confounders, no differences were found in terms of concordance, upgrading, and downgrading. To date, no large multicenter series assessed whether the TP route may improve cancer concordance with the final pathology in the MRI era, with special attention to the location of the tumor with MRI. These results may seem in contradiction to available literature where TP-TBx improves the detection of tumors located in the apex and the anterior zone of the gland. For instance, in a study by Schouten et al [24], TR-TBx missed a non-negligible number of significant cancers (7% at a patient-level and 35% at a segment-level analysis) that were mainly located at the apex and in dorsolateral regions. In the present study, only positive prostate biopsies were included, and tumors located in the anterior portion of the gland were correctly diagnosed even with the transrectal route. Of note, TP-MRI-TBx has a lower risk of upgrading and a higher risk of concordance in the peripheral zone. Finally, the improved prostate sampling using TP-TBx/RB provides a more sensitive test for ISUP score (one of the most robust predictors of clinical outcomes). However, it must be noted that the concordance with the final pathology is overall suboptimal, since only TP-MRI-TBx/RB results have a moderate agreement with the gold standard. Although TP is better than TR, the accuracy is still relatively low with a significant percentage of patients being downgraded even by TP. Hence, it may help implement the clinical pathway with a different imaging technology. There is some recent evidence of the utility of prostate-specific membrane antigen positron emission tomography scanning as a potential tool to improve PCa detection in MRI-negative patients [25], and improve grading accuracy by utilizing SUVmax [26].

Despite being the largest series of RP patients diagnosed with MRI-TBx assessing the impact of the TR versus TP approach, our study is not devoid of limitations. There is a wide array of biopsy options available for comparison (different biopsy techniques, software used for the fusion biopsies, number of TBx) as well as the different clinical settings in which these were used without any randomization (biopsy naïve vs repeated biopsies). Furthermore, patients who were candidates to radiation therapy or without available final pathology were not considered for the analyses. Thus, there is a risk of a selection bias, also considering the widespread diffusion of active surveillance protocols. Specifically, the population with low-risk disease that had surgery might have been negatively selected according to the presence of unfavorable prognostic factors. Moreover, the study was conducted in two separate cohorts with significantly different prostate volumes, PSA, and PSA density between the two groups, which might have contributed to higher PCa detection rates in the TP biopsies. In particular, TP biopsies are limited to smaller prostates since large ones may be shadowed by the pubic bone. This is particularly true for the biopsies performed with a brachytherapy grid, while freehand technique seems to have overall better pros-

tate sampling [27]. There is a well-known inverse relationship between prostate volume and the incidence of PCa, and this further supports the hypothesis that large prostate size may be protective against PCa when compared with smaller prostates, even in the MRI era [28]. There is heterogeneity of techniques, anesthesia, and software used, which is consistent with the retrospective study design and the heterogeneity of the sample. Although the comparison was not performed in concurrent TR-TBx and TP-TBx, the results from this study represent a real clinical practice scenario and therefore must be considered generalizable. Furthermore, multivariable analyses were performed to diminish potential confounders. Finally, although images and final pathologies were not centrally reviewed, our results apply to experienced centers where both TP-TBx and TR-TBx as well as RP are performed routinely.

5. Conclusions

In the current standard practice of MRI-TBx, TP-TBx improves concordance compared with TR-TBx and reduces the risk of tumor upgrading at the final pathology. TP-MRI-TBx in the peripheral zone has higher odds of concordance and lower odds of upgrading in comparison with TR-MRI-TBx, and it better retrieves information to adequately risk stratify the patients for the clinical decision-making process.

Author contributions: Fabio Zattoni had full access to all the data in the study and takes responsibility for the integrity of the data and the accuracy of the data analysis.

Study concept and design: Zattoni, Marra.

Acquisition of data: Martini, Kasivisvanathan, Grummet, Harkin, Plousard, Olivier, Chiu, Marquis, Guo, Zhuang, Frydenberg, Moon, Kretschmer, Barletta, Heidegger, Morlacco.

Analysis and interpretation of data: Zattoni, Marra, Martini, Gandaglia.

Drafting of the manuscript: Zattoni, Marra, Martini, Gandaglia.

Critical revision of the manuscript for important intellectual content: van den Bergh, Dal Moro, Briganti, Montorsi, Novara.

Statistical analysis: Zattoni, Marra.

Obtaining funding: None.

Administrative, technical, or material support: None.

Supervision: Kasivisvanathan, Gontero.

Other: None.

Financial disclosures: Fabio Zattoni certifies that all conflicts of interest, including specific financial interests and relationships and affiliations relevant to the subject matter or materials discussed in the manuscript (eg, employment/affiliation, grants or funding, consultancies, honoraria, stock ownership or options, expert testimony, royalties, or patents filed, received, or pending), are the following: None.

Funding/Support and role of the sponsor: None.

Appendix A. Supplementary data

Supplementary data to this article can be found online at <https://doi.org/10.1016/j.euf.2023.01.016>.

References

- [1] Kasivisvanathan V, Stabile A, Neves JB, et al. Magnetic resonance imaging-targeted biopsy versus systematic biopsy in the detection of prostate cancer: a systematic review and meta-analysis. *Eur Urol* 2019;76:284–303.
- [2] Kasivisvanathan V, Rannikko AS, Borghi M, et al. MRI-targeted or standard biopsy for prostate-cancer diagnosis. *N Engl J Med* 2018;378:1767–77.
- [3] Mannaerts CK, Gayet M, Verbeek JF, et al. Prostate cancer risk assessment in biopsy-naïve patients: the Rotterdam Prostate Cancer Risk Calculator in multiparametric magnetic resonance imaging-transrectal ultrasound (TRUS) fusion biopsy and systematic TRUS biopsy. *Eur Urol Oncol* 2018;1:109–17.
- [4] Goel S, Shoag JE, Gross MD, et al. Concordance between biopsy and radical prostatectomy pathology in the era of targeted biopsy: a systematic review and meta-analysis. *Eur Urol Oncol* 2020;3:10–20.
- [5] Mottet N, van den Bergh RCN, Briers E, et al. EAU-EANM-ESTRO-ESUR-SIOG guidelines on prostate cancer—2020 update. Part 1: screening, diagnosis, and local treatment with curative intent. *Eur Urol* 2021;79:243–62.
- [6] Hansen NL, Barrett T, Kesch C, et al. Multicentre evaluation of magnetic resonance imaging supported transperineal prostate biopsy in biopsy-naïve men with suspicion of prostate cancer. *BJU Int* 2018;122:40–9.
- [7] Zattoni F, Marra G, Kasivisvanathan V, et al. The detection of prostate cancer with magnetic resonance imaging-targeted prostate biopsies is superior with the transperineal vs the transrectal approach. *A European Association of Urology-Young Academic Urologists Prostate Cancer Working Group multi-institutional study*. *J Urol* 2022;208:830–7.
- [8] Rouvière O, Puech P, Renard-Penna R, et al. Use of prostate systematic and targeted biopsy on the basis of multiparametric MRI in biopsy-naïve patients (MRI-FIRST): a prospective, multicentre, paired diagnostic study. *Lancet Oncol* 2019;20:100–9.
- [9] Kaufmann B, Saba K, Schmidli TS, et al. Prostate cancer detection rate in men undergoing transperineal template-guided saturation and targeted prostate biopsy. *Prostate* 2022;82:388–96.
- [10] Hansen NL, Barrett T, Lloyd T, et al. Optimising the number of cores for magnetic resonance imaging-guided targeted and systematic transperineal prostate biopsy. *BJU Int* 2020;125:260–9.
- [11] van der Leest M, Cornel E, Israël B, et al. Head-to-head comparison of transrectal ultrasound-guided prostate biopsy versus multiparametric prostate resonance imaging with subsequent magnetic resonance-guided biopsy in biopsy-naïve men with elevated prostate-specific antigen: a large prospective multicenter clinical study. *Eur Urol* 2019;75:570–8.
- [12] Kasivisvanathan V, Dufour R, Moore CM, et al. Transperineal magnetic resonance image targeted prostate biopsy versus transperineal template prostate biopsy in the detection of clinically significant prostate cancer. *J Urol* 2013;189:860–6.
- [13] Loy LM, Lim GH, Leow JJ, Lee CH, Tan TW, Tan CH. A systematic review and meta-analysis of magnetic resonance imaging and ultrasound guided fusion biopsy of prostate for cancer detection—comparing transrectal with transperineal approaches. *Urol Oncol* 2020;38:650–60.
- [14] Pepe P, Garufi A, Priolo GD, Pennisi M. Multiparametric MRI/TRUS fusion prostate biopsy: advantages of a transperineal approach. *Anticancer Res* 2017;37:3291–4.
- [15] van Leenders GJLH, Kweldam CF, Schoots IG, et al. The 2019 International Society of Urological Pathology (ISUP) consensus conference on grading of prostatic carcinoma. *Am J Surg Pathol* 2020;44:E87–99.
- [16] Tan PH, Cheng L, Strigley JR, et al. International Society of Urological Pathology (ISUP) consensus conference on handling and staging of radical prostatectomy specimens. Working group 5: surgical margins. *Mod Pathol* 2011;24:48–57.
- [17] Weinreb JC, Barentsz JO, Choyke PL, et al. PI-RADS Prostate Imaging – Reporting and Data System: 2015, version 2. *Eur Urol* 2016;69:16–40.
- [18] Shoag JE, Cai PY, Gross MD, et al. Impact of prebiopsy magnetic resonance imaging on biopsy and radical prostatectomy grade concordance. *Cancer* 2020;126:2986–90.
- [19] Gansler T, Fedewa S, Qi R, Lin CC, Jemal A, Moul JW. Most Gleason 8 biopsies are downgraded at prostatectomy—does 4 + 4 = 7? *J Urol* 2018;199:706–12.
- [20] Vickers A, Carlsson SV, Cooperberg M. Routine use of magnetic resonance imaging for early detection of prostate cancer is not justified by the clinical trial evidence. *Eur Urol* 2020;78:304–6.
- [21] Kovac E, Vertosick EA, Sjöberg DD, Vickers AJ, Stephenson AJ. Effects of pathological upstaging or upgrading on metastasis and cancer-specific mortality in men with clinical low-risk prostate cancer. *BJU Int* 2018;122:1003–9.
- [22] Mai Z, Zhou Z, Yan W, et al. The transverse and vertical distribution of prostate cancer in biopsy and radical prostatectomy specimens. *BMC Cancer* 2018;18:1205.
- [23] Cyll K, Ersvær E, Vlatkovic L, et al. Tumour heterogeneity poses a significant challenge to cancer biomarker research. *Br J Cancer* 2017;117:367–75.
- [24] Schouten MG, van der Leest M, Pokorny M, et al. Why and where do we miss significant prostate cancer with multi-parametric magnetic resonance imaging followed by magnetic resonance-guided and transrectal ultrasound-guided biopsy in biopsy-naïve men? *Eur Urol* 2017;71:896–903.
- [25] Emmett L, Buteau J, Papa N, et al. The additive diagnostic value of prostate-specific membrane antigen positron emission tomography computed tomography to multiparametric magnetic resonance imaging triage in the diagnosis of prostate cancer (PRIMARY): a prospective multicentre study. *Eur Urol* 2021;80:682–9.
- [26] Kalapara AA, Ballok ZE, Ramdave S, et al. Combined utility of 68Ga-prostate-specific membrane antigen positron emission tomography/computed tomography and multiparametric magnetic resonance imaging in predicting prostate biopsy pathology. *Eur Urol Oncol* 2022;5:314–20.
- [27] Urkmez A, Demirel C, Altok M, Bathala TK, Shapiro DD, Davis JW. Freehand versus grid-based transperineal prostate biopsy: a comparison of anatomical region yield and complications. *J Urol* 2021;206:894–902.
- [28] Knight AS, Sharma P, de Riese WTW. MRI determined prostate volume and the incidence of prostate cancer on MRI-fusion biopsy: a systemic review of reported data for the last 20 years. *Int Urol Nephrol* 2022;54:3047–54.