

## Central serous chorioretinopathy: Recent findings and new physiopathology hypothesis



Alejandra Daruich <sup>a,1</sup>, Alexandre Matet <sup>a,1</sup>, Ali Dirani <sup>a</sup>, Elodie Bousquet <sup>b,c,d,e</sup>,  
Min Zhao <sup>b,c,d</sup>, Nicolette Farman <sup>b,c,d</sup>, Frédéric Jaisser <sup>b,c,d</sup>, Francine Behar-Cohen <sup>a,b,c,d,\*</sup>

<sup>a</sup> Department of Ophthalmology, University of Lausanne, Jules-Gonin Eye Hospital, Fondation Asile des Aveugles, Lausanne, Switzerland

<sup>b</sup> Sorbonne Universités, UPMC Université Paris 06, UMR 1138, Centre de Recherche des Cordeliers, Team 1 and 17, Paris, France

<sup>c</sup> INSERM, UMR 1138, Centre de Recherche des Cordeliers, Paris, France

<sup>d</sup> Université Paris Descartes, Sorbonne Paris Cité, UMR 1138, Centre de Recherche des Cordeliers, Paris, France

<sup>e</sup> AP-HP, Hôpital Hôtel-Dieu, Service d'ophtalmologie, Paris, France

### ARTICLE INFO

#### Article history:

Received 12 February 2015

Received in revised form

10 May 2015

Accepted 14 May 2015

Available online 27 May 2015

#### Keywords:

Central serous chorioretinopathy

Mineralocorticoid receptor

Retina

Physiopathology

Mineralocorticoid receptor antagonists

Glucocorticoids

Corticosteroids

### ABSTRACT

Central serous chorioretinopathy (CSCR) is a major cause of vision threat among middle-aged male individuals. Multimodal imaging led to the description of a wide range of CSCR manifestations, and highlighted the contribution of the choroid and pigment epithelium in CSCR pathogenesis. However, the exact molecular mechanisms of CSCR have remained uncertain. The aim of this review is to recapitulate the clinical understanding of CSCR, with an emphasis on the most recent findings on epidemiology, risk factors, clinical and imaging diagnosis, and treatments options. It also gives an overview of the novel mineralocorticoid pathway hypothesis, from animal data to clinical evidences of the biological efficacy of oral mineralocorticoid antagonists in acute and chronic CSCR patients. In rodents, activation of the mineralocorticoid pathway in ocular cells either by intravitreal injection of its specific ligand, aldosterone, or by over-expression of the receptor specifically in the vascular endothelium, induced ocular phenotypes carrying many features of acute CSCR. Molecular mechanisms include expression of the calcium-dependent potassium channel (KCa2.3) in the endothelium of choroidal vessels, inducing subsequent vasodilation. Inappropriate or over-activation of the mineralocorticoid receptor in ocular cells and other tissues (such as brain, vessels) could link CSCR with the known co-morbidities observed in CSCR patients, including hypertension, coronary disease and psychological stress.

© 2015 The Authors. Published by Elsevier Ltd. This is an open access article under the CC BY-NC-ND license (<http://creativecommons.org/licenses/by-nc-nd/4.0/>).

### Contents

1. Introduction .....	83
2. General overview of CSCR .....	85
2.1. Epidemiology .....	85
2.2. Risk factors .....	86
2.2.1. Genetic predisposition .....	86
2.2.2. Cardiovascular diseases and hypertension .....	87
2.2.3. Sympathetic-parasympathetic activity and reactivity .....	87
2.2.4. Corticosteroids .....	88
2.2.5. Endocrine changes .....	88
2.2.6. Psychopathology .....	89
2.2.7. Gastroesophageal disorders .....	89
2.2.8. Drug-induced CSCR (other than steroids) .....	89

\* Corresponding author. Hôpital Ophtalmique Jules-Gonin, Avenue de France 15, CP 133, 1000 Lausanne 7, Switzerland.

E-mail address: [francine.behar@gmail.com](mailto:francine.behar@gmail.com) (F. Behar-Cohen).

<sup>1</sup> Both authors have contributed equally to this work.

2.2.9.	Sleep disturbances .....	89
2.3.	Clinical presentation: forms and definitions .....	89
2.4.	Multimodal imaging of CSCR .....	90
2.4.1.	Spectral-domain optical coherence tomography .....	90
2.4.2.	Fundus autofluorescence .....	95
2.4.3.	Fluorescein angiography .....	97
2.4.4.	Indocyanine green angiography .....	98
2.4.5.	Adaptive optics .....	99
2.4.6.	Choroidal blood flow .....	100
2.5.	CSCR related entities and differential diagnosis .....	102
2.5.1.	Polypoidal choroidal vasculopathy (PCV) .....	102
2.5.2.	CSCR-associated choroidal neovascularization .....	103
2.5.3.	Type 1 CNV, chronic CSCR and “pachychoroid neovascularopathy” .....	103
2.5.4.	Cavitary optic disc anomalies .....	103
2.5.5.	Circumscribed choroidal hemangioma .....	103
2.5.6.	Dome-shaped macula .....	105
2.6.	Treatments .....	105
2.6.1.	Exclusion of risk factors .....	105
2.6.2.	Physical treatments .....	105
2.6.3.	Medical treatments .....	106
3.	CSCR: the mineralocorticoid pathway hypothesis .....	108
3.1.	The aldosterone/mineralocorticoid receptor pathway and rationale for potential involvement in CSCR pathogenesis .....	108
3.2.	The different MR antagonists .....	109
3.3.	Hypothesis: links between CSCR characteristics and MR/aldosterone pathway pathogenesis .....	110
3.4.	Scientific evidences .....	111
3.4.1.	Preclinical studies .....	111
3.4.2.	Preliminary clinical results .....	111
4.	Conclusions and future directions .....	111
	Authors contribution .....	111
	Acknowledgments .....	111
	References .....	112

## 1. Introduction

Central serous chorioretinopathy (CSCR or CSC) is a posterior segment disease characterized by localized and limited serous detachments of the neurosensory retina often associated with focal detachments of an altered retinal pigment epithelium. The term “central” refers to the form of the disease causing visual symptoms due to the presence of serous detachments in the macular area. But asymptomatic subjects may have presented one or multiple episodes of extra macular serous detachments, as often observed in the contralateral eye of an active CSCR patient or when systematically examining relatives of CSCR patients (Lehmann et al., 2015; Weenink et al., 2001) (Figs. 1 and 5D). The prevalence of CSCR is therefore likely to have been underestimated.

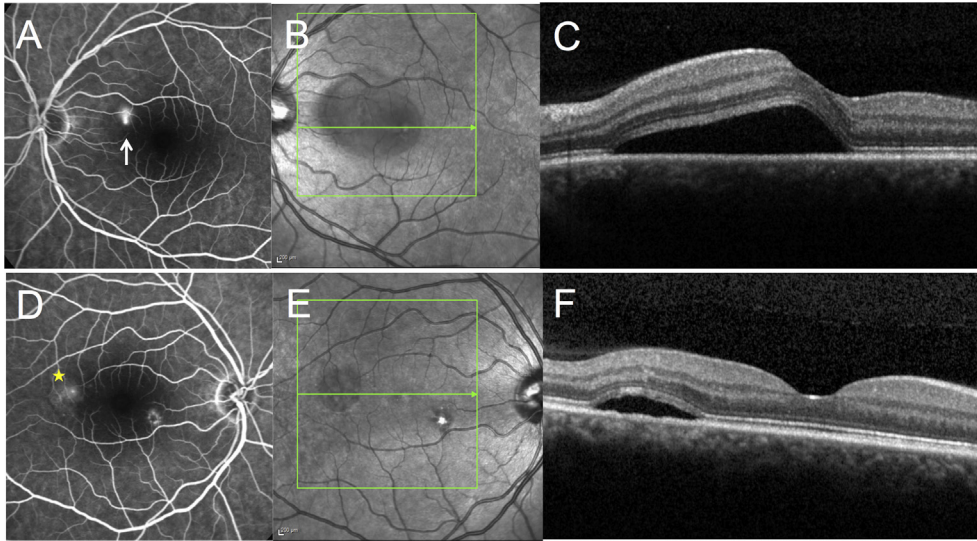
Whilst the acute CSCR form is clinically obvious especially in middle-aged men, the clinical diagnosis in older patients is more challenging, as chronic CSCR often resembles age-related macular degeneration (AMD) or can be complicated by choroidal neovascularization (CNV) (Fung et al., 2012; Inhoffen et al., 2012; Pang and Freund, 2015; Schatz et al., 1992). CSCR diagnosis is also difficult when occurring secondarily to steroid treatments administered for other retinal diseases (Khairallah et al., 2012). Recently, enhanced visualization of the choroid with spectral-domain optical coherence tomography (SD-OCT) has facilitated a more robust assessment of the role played by the choroid in CSCR, which in the past five years has resulted in more than 100 publications (Mrejen and Spaide, 2013). Based on these observations, it was recently proposed that “pachychoroid pigment epitheliopathy” could be a subclinical phenotype potentially complicated by serous detachments and/or choroidal vasculopathy, including type 1 CNV and polypoidal vasculopathy (Pang and Freund, 2015; Warrow et al., 2013). The segregation of the CSCR phenotypes becomes

unclear. In particular, whether there is a continuum between acute simple CSCR associated or not with pachychoroid (Fig. 2), and the chronic variants of the disease (referred to as Diffuse Retinal Pigment Epitheliopathy, DRPE) is yet to be prospectively investigated. Sparse or unique acute episodes of CSCR have a favorable visual prognosis but DRPE is associated with progressive and bilateral vision impairment, and has been estimated as the fourth most frequent non-surgical retinopathy (Wang et al., 2008). To date, the genetic, environmental, biological or clinical factors that favor one or the other form of this disease have not been established.

The relation between CSCR and corticoids is probably one of the most intriguing aspects of the disease. Glucocorticoids efficiently reduce macular edema of many origins, even when associated with subretinal fluid (Noma et al., 2012; Ossewaarde-van Norel et al., 2011), but glucocorticoids can aggravate subretinal fluid accumulation in CSCR patients. Even exposure to low-dose non-ocular corticosteroids has been associated with the occurrence of CSCR (Bouzas et al., 2002; Thinda et al., 2015). But high-dose intraocular injection of glucocorticoids, routinely administered for the treatment of macular edema, has not been associated with increased incidence of CSCR. Such discrepancies reflect the still non-elucidated complexity of steroids regulation on ocular physiopathology.

Since glucocorticoids aggravate rather than improve CSCR, inflammation was disregarded among potential disease mechanisms. This should be re-examined from the time when inflammation is recognized as a key player in the pathogenesis of AMD, in which unexpectedly glucocorticoid treatments did not show any major benefit (Geltzer et al., 2013).

Specific psychological and personality profiles have been associated with CSCR (Piskunowicz et al., 2014; Yannuzzi, 1986) but the

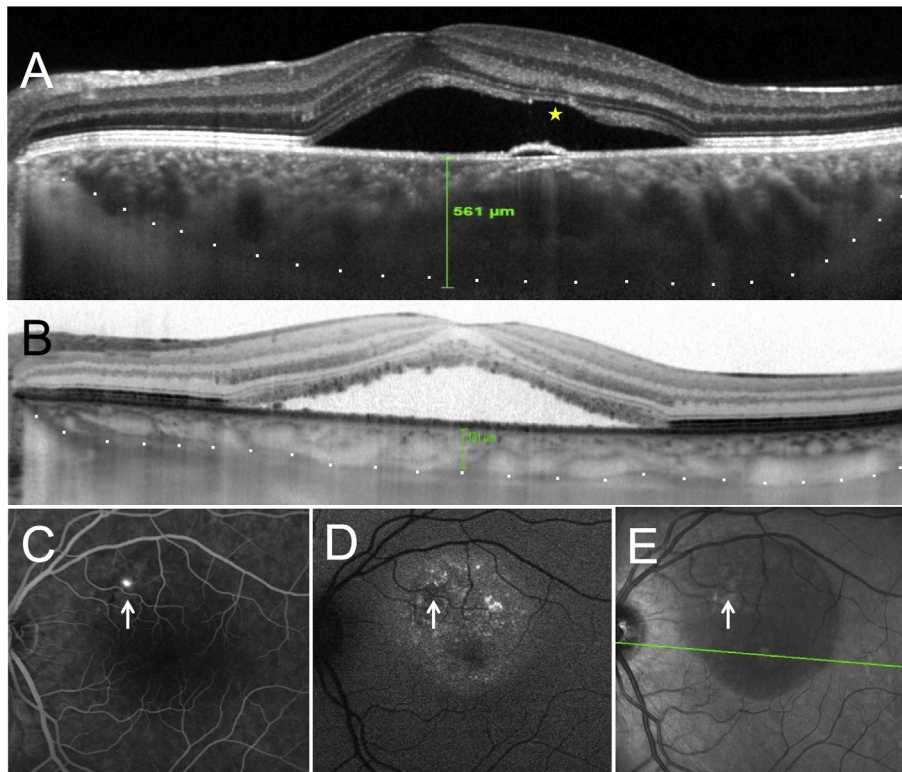


**Fig. 1.** Acute central serous chorioretinopathy with asymptomatic involvement of the contralateral eye. Thirty-nine year old man complaining of blurred central vision in his left eye for 2 weeks. Midphase fluorescein angiogram (A) identifies a single leaking point (arrow). Near-infrared reflectance (B) shows a circular hyporeflectivity corresponding to the subretinal detachment, involving the fovea as confirmed by SD-OCT (C). The same imaging of his asymptomatic right eye (D, E and F, respectively) revealed an extrafoveal unnoticed subretinal detachment, associated to a leakage point (star) and an area of RPE defect, probably resulting from a previous episode.

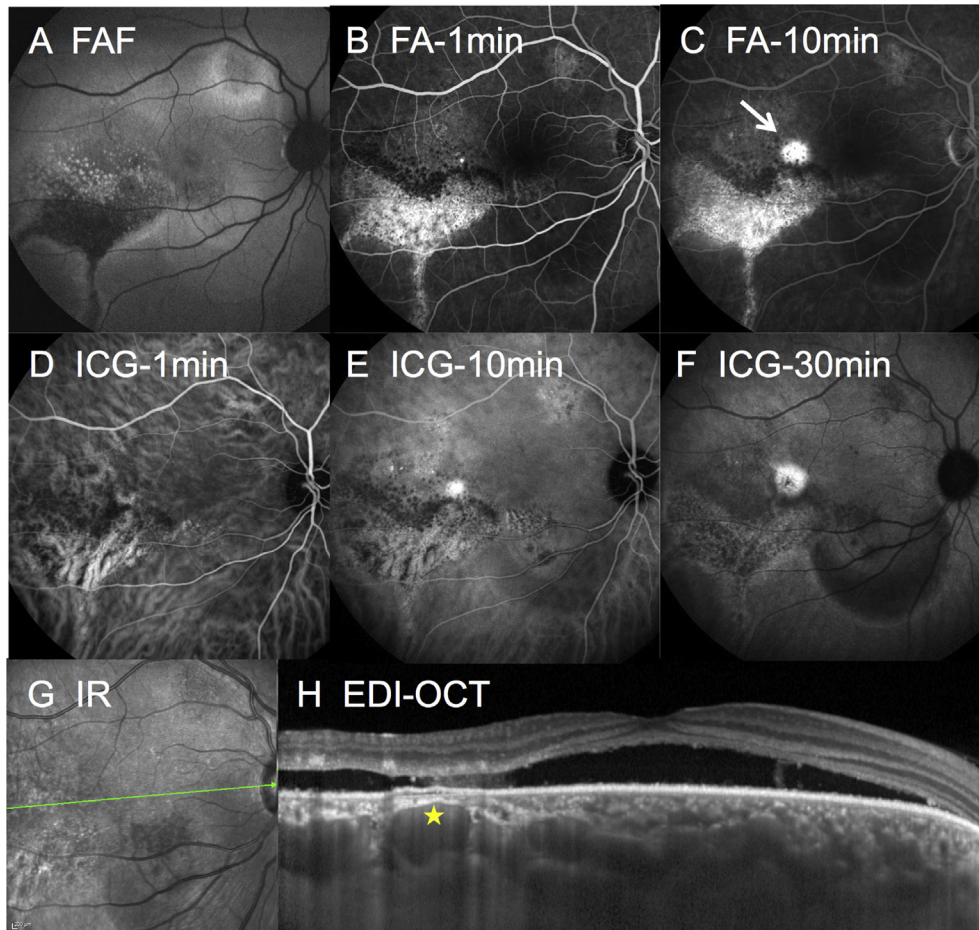
exact link between anxiety-sensitive personalities and steroid biology has not been elucidated and the full ocular and systemic steroid hormonal profile of CSCR patients has been only partially explored (Zakir et al., 2009). More determinants should be now considered in light of recent discoveries linking stress,

corticosteroids, epigenetic modifications and cardiovascular risk factors (Hunter, 2012; Reynolds, 2013).

All this considered, it is clear that complex links between CSCR and corticosteroids are yet to be described. In this context, we have investigated and identified the mineralocorticoid receptor as a



**Fig. 2.** Acute central serous chorioretinopathy in two cases, with increased and normal choroidal thickness. (A) SD-OCT in a 32-year old male patient with acute CSCR showing increased choroidal thickness (measured subfoveally at 560  $\mu\text{m}$ ) and eroded photoreceptor outer segments over the leakage site (star), visible as a small pigment epithelial detachment. (B) SD-OCT of a 36-year old male patient with normal refractive status showing acute CSCR and a subfoveal choroidal thickness within normal range (181  $\mu\text{m}$ ). At the leakage site (arrow) evidenced by fluorescein angiography (C), a diminished fundus autofluorescence (D) and a moderate increased infrared reflectance (E) indicated local RPE modifications. Autofluorescence was globally increased over the detached area due to the accumulation of autofluorescent material in the non-phagocytized photoreceptor outer segments.



**Fig. 3.** Multimodal imaging of active chronic CSCR in the right eye of a 45-year old man. FAF showed hypo-autofluorescent gravitational tracks (A). FA revealed a corresponding increased transmission of fluorescence related to the extended RPE alterations, and an active leakage site (arrow) corresponding to the RPE elevation on EDI-OCT (H, star). ICG showed dilated choroidal vessels and hyperpermeability (D, E), and late hyperfluorescence of the leakage site (F). EDI-OCT (H) visualized a RPE elevation and a hyper-reflective flow within the subretinal fluid. Beneath the RPE elevation, the choroidal vessels were more dilated, with hyper-reflective walls, and the choriocapillaris was thinner than in adjacent areas (star). FAF: fundus autofluorescence; FA: fluorescein angiography; ICG: indocyanine green angiography; IR: infrared reflectance; EDI-OCT: enhance-depth imaging optical coherence tomography.

potential player in CSCR pathogenesis. This review will focus on recent findings that have furthered the epidemiology, the clinical understanding and the management of CSCR and will detail the possible role of the mineralocorticoid pathway in CSCR pathogenesis and treatment.

## 2. General overview of CSCR

Several comprehensive reviews dealing with CSCR diagnosis, pathophysiology and therapeutic interventions have been recently published (Liew et al., 2013; Nicholson et al., 2013; Quin et al., 2013; Ross et al., 2011). We will therefore focus on the more recent findings and debated issues regarding CSCR. General and essential evidence-based knowledge will be compiled in tables to facilitate a broad overview of the available literature.

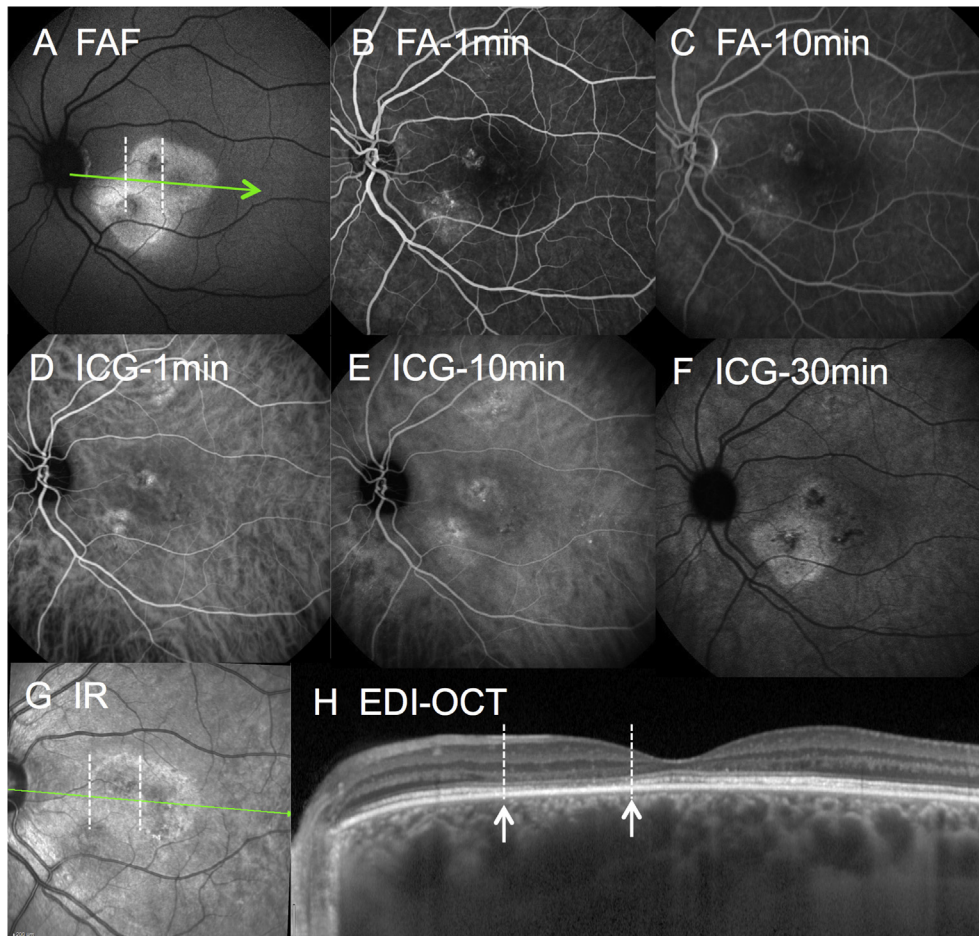
### 2.1. Epidemiology

CSCR ranks among the most common vision-threatening retinopathies after AMD, diabetic retinopathy and branch retinal vein occlusion (Wang et al., 2008). A higher prevalence among men was observed in several studies, with 72%–88% of cases occurring in male subjects (Spaide et al., 1996a; Tittl et al., 1999). In a population-based study carried out in Olmsted County, Minnesota,

the reported annual incidence was 9.9 per 100,000 individuals for men and 1.7 for women, indicating a 6-times higher incidence in men than in women (Kitzmann et al., 2008).

There is a variability in the reported age of affected patients, the more recent epidemiological data reporting a higher mean age than generally assumed, ranging between 39 and 51 years (Kitzmann et al., 2008; Tsai et al., 2013a). CSCR can occur at later ages, particularly in women and patients affected by atypical chronic forms (Cohen et al., 1983; Kitzmann et al., 2008; Lafaut et al., 1998; Perkins et al., 2002; Quillen et al., 1996). Noteworthy, CSCR has been rarely reported in children (Kim et al., 2012).

Variations of CSCR incidence among various ethnic groups remain controversial. A suspected higher frequency among Asians, Caucasians and Hispanics as compared to African Americans (Chan et al., 2010; Yannuzzi, 1987) was not confirmed in all studies (Desai et al., 2003). A more severe form of CSCR with lower visual acuity seems to affect the African American subjects. In the Asian population, CSCR is frequent and severe, with bilateral and multifocal forms being reported more frequently than in other ethnic groups (How and Koh, 2006). In a Taiwanese population-based study, the mean annual incidence of non-steroid induced CSCR was 21/100,000 (twice the incidence reported in Olmsted County, Minnesota) with a male/female ratio of 1.74. The incidence was highest in the 35–39 year-old age group, followed by the 40–44 year-old



**Fig. 4.** Multimodal imaging of inactive chronic CSCR in the left eye of a 45-year old man (same patient as Fig. 3). FAF exhibited two circular patchy areas of increased autofluorescence related to previous CSCR episodes (A). FA revealed two areas of mild residual RPE window defect (B, C). ICG showed two areas of persistent hyperpermeability (D, E) during early and midphase, with centrifugal expansion and central hypofluorescence at late phase. EDI-OCT confirmed the absence of active episode (H). It also showed a pachychoroid with dilated choroidal vessels, and a mild photoreceptor outer segments atrophy (between arrows and dotted lines). This atrophy corresponded partially to the hyperautofluorescence (A), possibly via a window defect in photopigment density. FAF: fundus autofluorescence; FA: fluorescein angiography; ICG: indocyanine green angiography; IR: infrared reflectance; EDI-OCT: enhance-depth imaging optical coherence tomography.

group. Males had a higher mean annual incidence than females, but this difference was significant only in the younger age groups, suggesting that women present CSCR at older ages (Tsai et al., 2013a). Finally, in the Asian population, large pigment epithelial detachments and highly elevated serous retinal detachments are more frequently observed, which might be misdiagnosed as Harada disease and aggravated by high-dose systemic corticosteroids (Kunavisarut et al., 2009).

## 2.2. Risk factors

### 2.2.1. Genetic predisposition

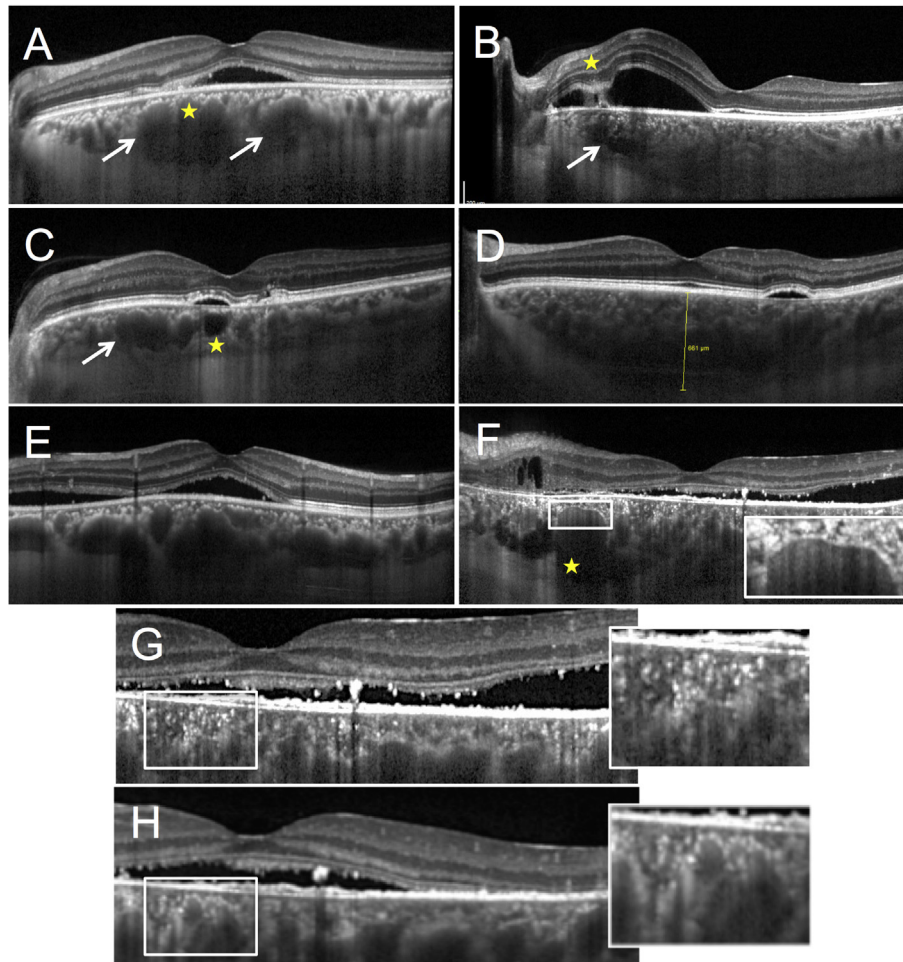
Several sporadic cases of familial CSCR have been reported in the literature (Amalric et al., 1971; Haik et al., 1968; Lin et al., 2000; Oosterhuis, 1996; Park et al., 1998; Wyman, 1963). Stronger evidence for a genetic contribution to the pathogenesis of CSCR comes from the observation that in 14 out of 27 families of CSCR patients (52%), at least one relative presented multiple areas of RPE atrophy or fundus lesions suggestive of chronic CSCR (Weenink et al., 2001). To date, no clear transmission pattern and no specific genotype have been associated to CSCR. In a recent analysis of five families, 50% of the eyes from relatives of CSCR patients had a choroid thicker than 395  $\mu\text{m}$ , suggesting that pachychoroid could be an inherited condition with a possible dominant transmission pattern

(Lehmann et al., 2015).

If confirmed, this hypothesis would suggest that a genetic background may predispose to CSCR and that thick choroids could be one of its phenotypic indicators.

Genetic studies based on single nucleotide polymorphisms have been performed on different cohorts of CSCR subjects. Complement factor H (CFH) was chosen as a candidate susceptibility gene for CSCR because the protein binds to adrenomedullin, a peptide that belongs to the calcitonin family and elicits a vasodilator action on the choroid. An association was found in 5 common polymorphisms of the CFH gene in a group of 140 Asian CSCR cases (compared to 934 population-based and 335 hospital-based controls), suggesting in this population a potential involvement of CFH in CSCR pathogenesis (Miki et al., 2013). In a larger cohort of 292 chronic CSCR patients (compared to 1147 AMD cases and 1311 healthy individuals), single nucleotide polymorphisms at 19 loci previously associated with AMD have been investigated. An association of chronic CSCR with genetic variants in ARMS2 and CFH was demonstrated, suggesting a genetic and pathogenic overlap between chronic CSCR and AMD (De Jong et al., 2014). However, in this study, alleles in ARMS2 and CFH that confer risks for AMD were protective for CSCR and alleles in CFH that were protective for AMD were associated to CSCR.

Interestingly, we have analyzed the subretinal fluid obtained



**Fig. 5.** Spectrum of choroidal changes in central serous chorioretinopathy on enhanced-depth imaging SD-OCT. (A) Increased subfoveal choroidal thickness (480  $\mu\text{m}$ ) with dilatation of large vessels from Haller's layer (arrows) and compression of overlying choriocapillaris (star), at the level of the subretinal detachment. (B) Increased subfoveal choroidal thickness (566  $\mu\text{m}$ ) without compression of the choriocapillaris. Hyporeflective dilated choroidal vessel (arrow) underlying a leakage site with a RPE elevation and locally thickened neurosensory retina ("retinal dipping", star), connected by a hyper-reflective flow, suggesting a high fibrin or protein content. (C) Dilated choroidal vessels despite normal subfoveal choroidal thickness (295  $\mu\text{m}$ ) in a resolved CSCR case. Beneath the pigment epithelial detachment, a hyporeflective choroidal vessel with square borders is visible, most likely a reflectivity artifact due to choroidal flow changes. (D) Asymptomatic fellow eye in a patient with unilateral active CSCR exhibiting a thickened choroid (subfoveally, 661  $\mu\text{m}$ ) despite a moderate dilatation of choroidal vessels, and an extrafoveal pigment epithelial detachment. (E) Vertical enhanced depth imaging SD-OCT section showing a pronounced, diffuse dilatation of large and medium choroidal vessels. (F) Extremely increased subfoveal choroidal thickness (675  $\mu\text{m}$ ) and dilated large vessel spanning the whole choroid (star) with thin hyper-reflective vascular walls (box) suggesting parietal structural changes. Shallow wavy RPE detachment and intraretinal cystoid cavities indicate chronic CSCR. (G) Magnification of case F demonstrating hyper-reflective dots at the level of choriocapillaris (box). (H) Magnification of case F showing 2 months later partial reapplication of the detached neurosensory retina. There is a rarefaction and a displacement of the choroidal hyper-reflective dots (box), possibly reflecting a cellular process related to the disease activity.

from a patient with chronic CSCR and found higher levels of CFH and lower levels of all other complement fractions compared to the subretinal fluid of control patients with rhegmatogenous retinal detachments (unpublished personal data). This observation is in agreement with the previous genetic findings.

Finally, in a cohort of 400 CSCR cases (compared to 1400 matched controls), a significant association was found with 4 common cadherin 5 single-nucleotide polymorphisms in CSCR male patients. Since cadherin 5 contributes to intercellular adhesions in the vascular endothelium, and is down-regulated by corticosteroids, genetic variations in cadherin 5, combined with triggering events such as corticosteroid treatment, could explain a proportion of CSCR occurrences among male patients (Schubert et al., 2014).

### 2.2.2. Cardiovascular diseases and hypertension

Patients with hypertension have a higher risk of developing CSCR (Odds Ratio (OR): 2.25–2.3) (Eom et al., 2012; Tittl et al., 1999). As compared to control patients, males with CSCR have a

significantly higher rate of coronary heart disease (Hazard Ratio (HR): 1.72), indicating that CSCR may be a potential risk factor for the development of coronary heart disease in men (Chen et al., 2014). CSCR was also shown to be an independent risk factor for ischemic stroke (HR: 1.56; 95% confidence interval (CI), 1.11–2.18) (Tsai et al., 2012), and for organic and psychogenic erectile dysfunction (HR: 2.14; 95% CI, 1.34–3.44 and 3.83; 95% CI, 1.47–10.01, respectively) (Tsai et al., 2013b). Consequently, the choroidal vasculopathy described in CSCR may not be isolated but rather part of a more diffuse vascular dysfunction that is yet to be better characterized.

### 2.2.3. Sympathetic-parasympathetic activity and reactivity

Compared to healthy subjects, CSCR patients present a significant sympathetic-parasympathetic imbalance. There is sympathetic over-activation and a decreased parasympathetic activity, as assessed by measures of blood pressure and heart rate variability (Tewari et al., 2006). This may be related to the modulation of the choroidal blood flow by the autonomic nervous system, and

appears consistent with the damages induced in vitro by epinephrine on RPE cells, ultimately leading to apoptosis (Sibayan et al., 2000).

#### 2.2.4. Corticosteroids

CSCR patients are more likely to have been previously exposed to oral corticosteroid medications, and patients under corticosteroid therapy are at higher risk for developing CSCR (Carvalho-Recchia et al., 2002; Haimovici et al., 2004; Karadimas and Bouzas, 2004; Kitzmann et al., 2008; Tittl et al., 1999; Tsai et al., 2014; Wakakura et al., 1997). When considering the route of administration, most series have clearly reported that systemic intake (oral or intravenous) is an independent risk factor for CSCR (Haimovici et al., 2004; Tittl et al., 1999; Tsai et al., 2014; Wakakura et al., 1997). CSCR has also been described after local administration of corticosteroids via the following routes: inhaled and intranasal (Haimovici et al., 1997; Kleinberger et al., 2011), epidural (Iida et al., 2001; Kao, 1998; Pizzimenti and Daniel, 2005), intra-articular (Hurvitz et al., 2009; Kassam et al., 2011; Mondal et al., 2005), topical dermal (Ezra et al., 2011; Fernandez et al., 2004; Karadimas and Bouzas, 2004; Romero et al., 2005) and periocular (Baumal et al., 2004). Whether intraocular steroids induce CSCR remains to be demonstrated. The aggravation of a pre-existing CSCR and the induction of a CSCR after vitrectomy and triamcinolone injection have been described in two case reports (Imasawa et al., 2005; Kocabora et al., 2008). A systematic literature search of corticosteroid-induced CSCR reports is summarized in Table 1, indicating the incriminated drugs, routes of intake and doses.

Systemic corticosteroids have been associated with occurrences, prolongation, exacerbation and recurrences of CSCR (Khairallah et al., 2012). Steroid-induced CSCR has less male predilection than idiopathic CSCR, and has frequently a bilateral and atypical presentation (Bouzas et al., 2002; Khairallah et al., 2012). It was

suggested that steroid-induced CSCR may be related to an idiosyncratic response in selected vulnerable individuals rather than to a dose-dependent effect, since very low doses can induce CSCR episodes (Han et al., 2014). During corticosteroid treatment for posterior uveitis, the discrimination between steroid-induced serous retinal detachments and uveitis-related manifestations can be challenging (Khairallah et al., 2012). Some studies have suggested that concomitant use of steroid and catecholamines may have additive effects in animal models of serous retinal detachment (Falkenstein et al., 2000; Jampol et al., 2002; Walker et al., 1996; Yoshioka et al., 1982). Organ transplant procedures require treatments with high doses of glucocorticoids and vasopressive catecholamines and stimulate the endogenous production of stress hormones increasing the risk of CSCR. Indeed, there are numerous reports of CSCR following organ transplantation, the more frequently involved interventions being: kidney, bone marrow and heart transplantations (Chaine et al., 2001; Cheng et al., 2002; Chung et al., 2007; Farzan et al., 2014; Fawzi et al., 2006; Fawzi and Cunningham, 2001; Friberg and Eller, 1990; Kamoun et al., 2005; Karashima et al., 2002; Kian-Ersi et al., 2008; Moon and Mieler, 2003; Oliaei et al., 2007; Polak et al., 1995; Sabet-Peyman et al., 2012; Singh et al., 2003). Finally, allergy has been suggested to favor CSCR, yet various allergic manifestations are managed with local or systemic corticosteroids and the distinction between the contribution of allergy or its treatment remains to be determined (Edalati et al., 2009).

#### 2.2.5. Endocrine changes

The risk of CSCR is higher in case of prior or current pregnancy (adjusted OR: 7.1; 95% CI, 1.0–50.7) (Haimovici et al., 2004), particularly during the third semester. It can resolve spontaneously after delivery (Chumbley and Frank, 1974; Errera et al., 2013; Schultz et al., 2014), linking cortisol levels and/or pregnancy-associated hormonal variations to CSCR (Cousins et al., 1983;

**Table 1**  
Corticosteroids-induced CSCR.

Route	Type of corticosteroid	Dose	Author and publication date
Oral	Prednisolone	5–60 mg/day	(Chaine et al., 2001) (Koyama et al., 2004) (Loo et al., 2006) (Spraul et al., 1998) (Spraul et al., 1997) (Tsai et al., 2014) (Wakakura et al., 1997)
	Prednisone	10–80 mg/day	(Gass and Little, 1995) (Bouzas et al., 1999) (Bandello et al., 2002) (Levy et al., 2005) (Bevis et al., 2005)
Intravenous	Betamethasone	10 mg/day	(Wakakura and Ishikawa, 1984)
	Methylprednisolone	16–1000 mg/day	(Bevis et al., 2005) (Spraul et al., 1998)
Intravitreal	Triamcinolone acetonide	4 mg/0.1 mL	(Imasawa et al., 2005) (Kocabora et al., 2008)
Epidural	Triamcinolone acetonide	2 mL Triamcinolone acetonide	(Kao, 1998)
	Methylprednisolone acetate	40–120 mg Methylprednisolone acetate	(Iida et al., 2001) (Pizzimenti and Daniel, 2005)
Periocular Dermal	Triamcinolone acetonide	1.0-mL(40 mg/mL)	(Baumal et al., 2004)
	Mometasone furoate 0.1%	0.1% (mometasone furoate cream)	(Fernandez et al., 2004)
	Bethamethasone + calcitriol	NA	(Karadimas and Bouzas, 2004) (Romero et al., 2005) (Ezra et al., 2011)
Intra-articular	Triamcinolone acetonide	1–2 ml (40–80 mg)	(Mondal et al., 2005) (Hurvitz et al., 2009) (Kassam et al., 2011)
Intranasal	Fluticasone propionate	NA	(Haimovici et al., 1997)
	Beclomethasone	NA	(Kleinberger et al., 2011)

NA = Data not provided.

Errera et al., 2013; Schultz et al., 2014).

CSCR develops in up to 5% of patients with endogenous Cushing syndrome (Bouzas et al., 1993; Carvalho-Recchia et al., 2002). The relationship between endogenous steroids and CSCR was evaluated in several comparative studies: the 8-am and 11-pm serum cortisol levels (Garg et al., 1997; Zakir et al., 2009) and total 24-h urine cortisol level (Garg et al., 1997; Kapetanios et al., 1998) were increased in acute CSCR patients as compared to normal subjects. In an observational series of 24 acute CSCR cases (Haimovici et al., 2003), 50% of patients had elevated 24-h urine cortisol and tetrahydroaldosterone levels, whereas serum aldosterone levels were low in 29% of patients, indicating that mineralocorticoid regulation could also intervene in the pathogenesis of CSCR. Twenty-nine percent of patients exhibited elevated single morning plasma catecholamine level, but normal 24-h urine metanephrines, the byproducts of catecholamine breakdown. Serum testosterone levels were not raised in a cohort of CSCR patients compared to controls (Zakir et al., 2009).

### 2.2.6. Psychopathology

In 1986, Yannuzzi observed an association between CSCR and “type-A” personality pattern, characterized by a competitive drive, a sense of urgency, an aggressive nature and a hostile temperament (Yannuzzi, 1986). Subsequently, anti-psychotropic medication use and psychological stress were described as independent risk factors for CSCR (OR: 2.6; 95% CI, 1.30–5.19) (Tittl et al., 1999) and psychiatric illness (depression) was associated with an increased risk of recurrence (HR: 3.50; 95% CI, 1.33–9.23) (Fok et al., 2011). In a questionnaire-based study of 31 CSCR cases compared to 31 matched controls, no excess of critical life events (regarding social, professional, health and financial categories) was observed among CSCR patients, but higher levels of emotional distress, somatization, depression and hostility were observed (Conrad et al., 2007). More recently, the possible association between narcissistic personality (characterized by an extreme gratification of self) and CSCR was suggested (Carlesimo et al., 2014). Indeed, a systematic analysis of 57 CSCR patients and 57 age- and gender-matched controls was performed using psychometric questionnaires, which evaluate the emotional distress and psychopathology (i.e., somatization, obsessive-compulsive disorder, interpersonal sensitivity, depression, anxiety, hostility, phobic anxiety, paranoid ideation, and psychoticism) and the personality (based on the Temperament and Character Inventory). Compared to healthy controls, CSCR patients presented with significant higher emotional distress index in all psychopathological categories and lower cooperativeness and reward dependence. Such individuals are hostile, critical, unhelpful, and opportunistic, have low consideration of other people's rights or feelings with a tendency to manipulate others for their own gain. This trait is in line with type-A personality that is associated with opportunistic competitiveness, aggression, hostility and low threshold of frustration tolerance. CSCR patients are particularly at risk of the development of stress-induced vision threat in their working environment and may have low therapeutic compliance (Conrad et al., 2014).

### 2.2.7. Gastroesophageal disorders

Gastroesophageal reflux and CSCR share stress and adaptive response to stress as risk factors. In a retrospective case–control study, CSCR patients had a higher risk of gastroesophageal reflux (OR: 6.05; 95% CI, 2.14–17.11) and of anti-acid or anti-reflux medication use (OR: 15.00; 95% CI, 1.91–117.58) (Mansuetta et al., 2004). Interestingly, a recent population-based retrospective study investigating the risk factors of CSCR in Taiwan identified peptic ulcer (adjusted OR: 1.39; 95% CI, 1.14–1.70) and higher monthly income (adjusted OR: 1.30; 95% CI, 1.08–1.57) as

independent risk factors (Chen et al., 2014). Among CSCR patients, the risk of peptic ulcer was higher after the diagnosis of CSCR. Several studies also reported a high prevalence of *Helicobacter pylori* infection in CSCR patients (Ahnouh-Zabsonre et al., 2004; Cotticelli et al., 2006; Giusti, 2001; Mateo-Montoya and Mauguet-Fajse, 2014; Mauguet-Fajse et al., 2002; Roshani et al., 2014). *H. pylori*-dependent immune mechanism and molecular mimicry between pathogenic antigens and host proteins (Giusti, 2004) has been hypothesized but additional studies are needed to confirm the relationship between CSCR and *H. pylori*, and the benefit of *H. pylori* treatment on the course of CSCR, as suggested by some studies (Casella et al., 2012; Dang et al., 2013; Rahbani-Nobar et al., 2011).

### 2.2.8. Drug-induced CSCR (other than steroids)

CSCR episodes have been associated to the use of sympathomimetic drugs, which can be related to the altered reactivity profile of CSCR patients to sympathetic stimuli (see 2.2.3). In two separate case series, CSCR has been linked to the following adrenergic receptor antagonists: pseudoephedrine and oxymetazoline (contained in nasal sprays prescribed for upper airways congestion), MMDA (an illicit amphetamine) and ephedra (contained in body-building dietary products) (Michael et al., 2003; Pierce and Lane, 2009).

CSCR has also been described after the use of phosphodiesterase-5 inhibitors (sildenafil, tadalafil, vardenafil), but there is conflicting evidence regarding CSCR resolution after treatment discontinuation (Aliferis et al., 2012; Fraunfelder and Fraunfelder, 2008).

Up to 65% of patients receiving oral MEK-inhibitors (binimetinib) for metastatic cancer, develop transient bilateral serous retinal detachments and moderately blurred vision (McCannel et al., 2014; Urner-Bloch et al., 2014). Clinical manifestations occurred within days after initiation of MEK-inhibitor therapy and, with a dose-dependent effect on central retinal thickness on OCT imaging. In all reports, symptoms and subretinal fluid spontaneously resolved without treatment interruption. In part of these cases, an associated anterior uveitis suggests the hypothesis of an inflammation-induced serous detachment. Interestingly, no abnormalities were found on fluorescein or indocyanine green (ICG) angiography.

### 2.2.9. Sleep disturbances

The role of sleep disturbances and particularly obstructive sleep apnea in CSCR is controversial. Obstructive sleep apnea has been reported in 22% of CSCR patients, which is markedly elevated compared to 2–4% reported in the general population (Eom et al., 2012; Kloos et al., 2008). But the retrospective questionnaire-based analysis of 48 CSCR patients and 48 age-, gender- and body mass index-matched control subjects revealed a similar rate of obstructive sleep apnea in CSCR (46%) and controls (44%) (Brodie et al., 2015). This discrepancy can be explained by neutralization of the body mass index co-factor, an established risk of obstructive sleep apnea.

## 2.3. Clinical presentation: forms and definitions

The term “CSCR” covers two distinct entities, classically defined as the acute and chronic forms of the disease. This distinction is somewhat ambiguous because it relies on a temporal criteria (the duration of the serous retinal detachment), and on the presence of extended RPE changes. In the acute form (Figs. 1 and 2), patients report symptoms related to the localization of the subretinal detachment (SRD) in the macular area: blurred vision, relative central scotoma, metamorphopsia, moderate dyschromatopsia, hypermetropization, micropsia and reduced contrast sensitivity, which have been already extensively investigated (Wang et al.,



2008). The acute form is characterized by the presence of SRD, clinically detectable on fundus examination and on OCT, with limited focal or multifocal RPE alterations that may be limited to small pigment epithelial detachments (PEDs), and leakage through the RPE on fluorescein angiography (FA). The SRD usually resolves within 3–4 months, leaving in most cases no long-term symptoms, except color discrimination defects in some patients (Baran et al., 2005). Possible permanent functional changes were described on ERGs. The term “classic” CSCR has been also used to describe these patients with a circumscribed area of subretinal fluid associated with one or a few leaks seen on FA.

No consensus exists over the duration threshold that differentiates acute and chronic CSCR, arbitrarily set between 4 and 6 months in most published reports. This limit is critical for therapeutic studies since it determines the appropriate timing for intervention, when self-resolution is no longer to be expected. Authors have referred to acute CSCR with persistent SRD after this initial period as “chronic” CSCR. However, we suggest that the terms “non-resolving” or “persistent” CSCR are more appropriate to describe these cases with long-lasting SRD, preventing confusion with the chronic form characterized by a diffuse pigment epitheliopathy.

This chronic form (Figs. 3 and 4), which had been initially termed “diffuse retinal epitheliopathy” and was described as a variant of CSCR (Yannuzzi et al., 1992) is characterized by widespread tracks of RPE atrophy characterized by their decreased fundus autofluorescence (FAF) (Imamura et al., 2011; Teke et al., 2014). Symptoms are permanent with moderate to severe visual acuity loss and decreased light sensitivity depending on the degree of photoreceptors outer segments damage (Ooto et al., 2010b; Piccolino et al., 2005). In addition to chronic SRD, OCT shows multifocal RPE atrophy in areas corresponding to the hypo-autofluorescent tracks, and irregular RPE detachments. Intra-retinal cystoid cavities can also be observed (Iida et al., 2003; Piccolino et al., 2008a) and are associated with disease duration longer than 5 years (Piccolino et al., 2008b). Aggressive forms of chronic CSCR characterized by bullous SRD and massive exudation with subretinal fibrin deposits have been referred to as “multifocal posterior pigment epitheliopathy” (Uyama et al., 1999), a term rarely employed in the recent literature. As detailed in 2.1.3, bullous serous detachments seem more frequent in the Asian population, and are exacerbated by systemic corticosteroid treatment, as it occurs when CSCR is misdiagnosed for an inflammatory chorioretinal disorder.

A consensual definition of the various clinical subtypes of CSCR and their exact limits is critical in the prospect of clinical trial design. We suggest the following definitions and indicate the main issues raised for each entity:

- Acute CSCR: self-resolving SRD within 4 months from the onset of symptoms. Should we consider it differently if pachychoroid and/or epitheliopathy are present in the contralateral eye? Or if signs of previous episodes are present in the diseased eye?
- Non-resolving CSCR (or “persistent” CSCR): acute CSCR with duration of SRD longer than 4 months after onset of symptoms, often associated with elongated photoreceptor outer segments on SD-OCT. Should we consider the existence of a new leaky point on FA as an exclusion criteria, classifying thus the patient as recurrent CSCR?
- Recurrent CSCR: episode of acute CSCR following a previous episode with complete SRD resolution. Should recurrent CSCR be regarded differently if they originate from the same or from new leaky point on FA?
- Chronic CSCR (formerly “diffuse retinal epitheliopathy”): chronic chorioretinopathy with widespread RPE

decompensation with or without SRD, associated or not with active leakage sites. Should we include in this definition the recently introduced “pachychoroid pigment epitheliopathy” (Warrow et al., 2013), or should it be considered as a separate entity?

- Inactive CSCR: patients with history of acute CSCR but without SRD at the time of evaluation

An important point of terminology is the distinction between non-resolving and chronic CSCR. Whether uncomplicated acute CSCR can evolve into chronic CSCR with diffuse RPE disease, or whether they are two different entities, is still debated. Evidence of this connection relies on illustrative case reports and case series (Bujarborua, 2001; Katsimpris et al., 2007). In one report, 8 of 50 patients demonstrate three years after initial evaluation a more extended surface of RPE defects on FA (Castro-Correia et al., 1992). Noticeably, most reports include cases from ethnic groups in which CSCR often follows a more aggressive course (African, Indian and Portuguese patients), as discussed in 2.1.3.

Although disease manifestations are usually reported by patients in one eye due to the presence of a macular SRD, CSCR presents often as a bilateral condition. Bilateral involvement has been reported in up to 40% of cases (Gäckle et al., 1998). In an analysis of 74 cases, 4% presented bilateral CSCR at the time of diagnosis. 8% of unilateral cases had either a history of CSCR or FA findings indicative of CSCR in the contralateral eye, and 9% of patients initially diagnosed with unilateral disease developed CSCR in the other eye during follow-up (Kitzmann et al., 2008). In a retrospective case series of 229 patients, 32% of asymptomatic fellow eyes presented fluorescein angiographic features indicating healed or subclinical CSCR, including SRD, PEDs, depigmented or atrophic RPE patches, drusen-like deposits, or pigment clumps (Bujarborua et al., 2005).

#### 2.4. Multimodal imaging of CSCR

The diagnosis and follow-up of CSCR relies mostly on multimodal imaging. While SD-OCT is the primary modality, FAF is useful to non-invasively identify RPE alterations from previous episodes, and FA indicates the origin of leakage at baseline. Recurrent, non-resolving and chronic cases should benefit from comprehensive multimodal imaging with SD-OCT, FAF, FA and ICG angiography in order to guide treatment, follow extension and detect neovascular or polypoidal components.

##### 2.4.1. Spectral-domain optical coherence tomography

SD-OCT is the primary imaging modality for the diagnosis and follow-up of CSCR. State-of-the-art SD-OCT devices provide quick, non-invasive and reproducible high-definition images of the retinal layers and pathological modifications occurring in the macular area, facilitated by eye-tracking and landmark alignment algorithms which correlate serial images. Recently, enhanced-depth imaging and swept-source technologies have allowed full-depth visualization of the choroid, improving the morphological analysis of choroidal vessels and choroidal thickness measurements. Beyond subretinal fluid and PEDs associated or not to RPE leakage sites, other changes observed with SD-OCT imaging have given insight into the pathogenesis of CSCR. A review of the retinal and choroidal alterations identified by SD-OCT in CSCR patients is summarized in Table 2.

**2.4.1.1. Choroid.** Compared to healthy subjects, increased choroidal thickness has been reported in both affected (Imamura et al., 2009; Jirarattanasopa et al., 2012b; Kim et al., 2011; Kuroda et al., 2013; Yang et al., 2013a) and fellow eyes of CSCR patients (Goktas, 2014; Maruko et al., 2011c; Yang et al., 2013b) (Fig. 5). In addition,

affected eyes of unilateral cases were shown to have a greater choroidal thickness than fellow eyes (Goktas, 2014; Maruko et al., 2011c; Oh et al., 2014; Yang et al., 2013b). The threshold limit of “normal” choroidal thickness remains to be determined taking into account correction for axial length, age and circadian rhythm. Considering cohort studies measurements, 395  $\mu\text{m}$  could be used as a sensitive value to diagnose “thick choroid” or “pachychoroid” (Lehmann et al., 2015). Table 3 summarizes the reported choroidal thickness measurements in CSCR from the recent literature.

Choroidal thickening can result from focal or diffuse dilatation of large choroidal vessels (Fig. 5A–F). These dilated vessels are commonly localized within areas of increased choroidal vascular permeability on ICG angiography (Jirattanasopa et al., 2012b; Kuroda et al., 2013; Maruko et al., 2011c; Razavi et al., 2014; Yang et al., 2013a). Above these dilated choroidal vessels, the inner

choroidal layer, which includes medium and small vessels, is thinner than in adjacent areas (Yang et al., 2013a) (Fig. 5A). This could result from primary atrophy of the choriocapillaris or compression by the enlarged vessels from the outer choroid. Interestingly, RPE elevations are usually observed at the site of dilated vessels, possibly indicating a mechanical stress on the RPE caused by an underlying compression (Fig. 5B). In some patients, particularly in the contralateral eyes of active CSCR, an extremely thickened choroid is observed, inside which all vascular layers are equally visible without specific vessel enlargements (Fig. 5D). In chronic cases, large vessel walls harbor a granular hyper-reflectivity suggesting possible changes in vascular wall structure (Fig. 5F).

Hyperreflective dots on SD-OCT have been described in the neuroretina and subretinal space of CSCR eyes (see 2.4.1.3). They can also be observed in the choroid, mostly in the inner choroid

**Table 2**  
SD-OCT findings in CSCR patients.

Site	SD-OCT finding	Comments	Reference
Choroid	Thickened subfoveal choroid Dilatated choroidal vessels	More common in areas of midphase hyperfluorescence on ICG angiography.	(Yang et al., 2013a) (Razavi et al., 2014) (Jirattanasopa et al., 2012b) (Kuroda et al., 2013) (Maruko et al., 2011c) (Ferrara et al., 2014) (Yang et al., 2013a)
	Thinning of the “inner choroidal layer” Focal choroidal excavations	2.8–7.8% in all CSCR forms. Possibly more frequent in chronic CSCR	(Ellabban et al., 2013) (Suzuki et al., 2014)
RPE	PED	53–100% in acute and chronic CSCR. More frequent in chronic forms. Colocalizes with choroidal hyperpermeability areas.	(Yang et al., 2013a) (Mitarai et al., 2006) (Ahlers et al., 2009) (Van Velthoven et al., 2005) (Hirami et al., 2007) (Yang et al., 2013a)
	Microrip of the RPE or fissure	12%	(Lim and Wong, 2008)
	RPE hypertrophy	31–50% in resolved or chronic CSCR.	(Lehmann et al., 2013) (Yalcinbayir et al., 2014)
	RPE atrophy	More common in chronic CSCR with cystoid macular degeneration.	(Piccolino et al., 2008a)
Leakage site	Elevation of RPE PED	19–68% in acute CSCR 32–71% in acute CSCR	(Kim et al., 2012) (Fujimoto et al., 2008) (Mitarai et al., 2006) (Shinojima et al., 2010)
	Highly reflective areas suggesting fibrinous exudate in the subretinal space	20.3–52% in acute CSCR	(Kim et al., 2012)
	Sagging or dipping of the posterior retinal layer	13–43% in acute CSCR	(Fujimoto et al., 2008) (Kim et al., 2012)
Serous retinal detachment	Elongated photoreceptor outer segments	73% in acute CSCR. More frequently present when punctate precipitates or white deposits are seen clinically.	(Matsumoto et al., 2011, 2008) (Ahlers et al., 2009)
	Subretinal hyper-reflective deposits	65–82%. Corresponds to fundus punctate precipitates and white-yellow material. Generally associated with punctate hyper-autofluorescence. Increasing with symptom duration. Correlation with lower final BCVA.	(Maruko et al., 2011a) (Kon et al., 2008) (Spaide and Klanicnik, 2005) (Wang et al., 2005) (Landa et al., 2013)
Retina layers	Intraretinal hyper-reflective deposits in the OPL, the ONL, the ELM and the IS/OS band	21–100% in all CSCR forms. Correlation with lower final BCVA. Colocalized with Hyper-AF dots in FAF. Deeping in retinal layers with symptoms duration. More frequent in chronic or recurrent than acute CSCR.	(Ahlers et al., 2009) (Kon et al., 2008) (Yalcinbayir et al., 2014) (Iacono et al., 2015) (Plateroti et al., 2014) (Ojima et al., 2007)
	ONL thinning/discontinuity of the IS/OS line/ELM disruption Decrease in foveal thickness	Correlation with lower final BCVA.	(Matsumoto et al., 2009, 2008) (Ojima et al., 2007) (Piccolino et al., 2005) (Yalcinbayir et al., 2014) (Eandi et al., 2005) (Furuta et al., 2009)
	Cystoid macular degeneration	In chronic CSCR Risk factors: disease duration longer than 5 years and subretinal fibrosis.	(Iida et al., 2003) (Piccolino et al., 2008a, 2008b)

RPE = retinal pigment epithelium, PED = pigment epithelium detachment, BCVA = best-corrected visual acuity, OPL = outer plexiform layer, ONL = outer nuclear layer, ELM = external limiting membrane, IS/OS = Inner segment/outer segment, AF = autofluorescent, FAF = fundus autofluorescence; ICGA = indocyanine green angiography, CSCR = central serous chorioretinopathy.

**Table 3**  
Subfoveal choroidal thickness in CSCR patients.

Author	Number of eyes/CSCR type	Number of control eyes (statistical adjustment/matching)	Country	Mean SFCT ± SD (μm) in CSCR eyes	Mean SFCT ± SD (μm) in fellow eyes	Mean SFCT ± SD (μm) in control eyes	OCT type
(Carrai et al., 2015)	40 active CSCR eyes	–	Italy	478 ± 114	–	–	Wide-field EDI-OCT
(Hamzah et al., 2014)	56 eyes: – 21 acute CSCR eyes – 35 chronic CSCR eyes	–	Indonesia	336.6 ± 91.6 (acute, EDI-OCT) 332.0 ± 96.7 (acute, SS-OCT) 388.0 ± 103.4 (chronic, EDI-OCT) 392.6 ± 101.3 (chronic, SS-OCT)	–	–	EDI-OCT SS-OCT
(Goktas, 2014)	20 acute CSCR eyes	20 (age-matched)	Turkey	461.4 ± 101.4	375.3 ± 103.7 (P < 0.001)	287.6 ± 62.5 (P < 0.001) <sup>a</sup>	EDI-OCT
(Oh et al., 2014)	52 eyes with unilateral classic CSCR	–	Korea	298.4 ± 58.7	264.4 ± 52.1 (P < 0.001)	–	EDI-OCT
(Lehmann et al., 2013)	29 eyes 23 active CSCR 22 quiescent CSCR	–	France	491.5	–	–	EDI-OCT
(Yang et al., 2013a)	68 eyes – 35 acute CSCR – 33 chronic CSCR	3233 (from The Beijing Eye Study (Wei et al., 2013))	China	478 ± 114	–	254 ± 107	EDI-OCT
(Yang et al., 2013b)	15 eyes with unilateral CSCR	15 (age, gender, refractive error matched)	China	455 ± 73	387 ± 94 (P = 0.04)	289 ± 71 (P = 0.005) <sup>a</sup>	EDI-OCT
(Kuroda et al., 2013)	35 classic CSCR	35 (age-matched)	Japan	475 ± 138	–	372 ± 120 (P < 0.01)	SS-OCT
(Jirarattanasopa et al., 2012b)	44 eyes – 23 Classic CSCR – 17 Chronic CSCR – 4 MPPE	17 (age-matched)	Japan	374.3 ± 92.9	–	248.4 ± 77.4 (P < 0.001)	SS-OCT
(Kim et al., 2011)	31 eyes: – 26 acute CSCR – 5 chronic CSCR	29 (age, gender, refractive error adjusted)	Korea	367.81 ± 105.56	–	241.97 ± 66.4 (P < 0.001)	EDI-OCT
(Maruko et al., 2011c)	66 eyes: – 39 acute CSCR – 27 chronic CSCR	177 (age-matched)	Japan	414 ± 109	350 ± 116 (P < 0.001)	250 ± 75 (P < 0.001) <sup>a</sup>	EDI-OCT
(Imamura et al., 2009)	28 eyes: – 6 classic CSCR – 16 DRPE	30 (age-adjusted)	USA	505 ± 114	–	287 ± 76 (P < 0.001)	EDI-OCT

SD = standard deviation, SFCT = Sub foveal choroidal thickness, DRPE = diffuse retinal pigment epitheliopathy, MPPE = multifocal posterior pigment epitheliopathy, WM = whole macula, EDI = enhanced-depth imaging, SS = swept-source, OCT = optical coherence tomography, CSCR = central serous chorioretinopathy.

<sup>a</sup> Compared to the fellow eye group.

(Fig. 5G), and seem to disappear with subretinal fluid resolution (Fig. 5H). Thirty-two cases of unilateral CSCR with non-resolving subretinal fluid for more than 4 months were reviewed internally, revealing choroidal hyper-reflective dots in 72% of CSCR eyes versus 29% of unaffected eyes ( $p = 0.001$ , Fisher exact test). Hyper-reflective choroidal vessel walls were observed in 84% of CSCR eyes versus 16% of unaffected eyes ( $p = 0.001$ , Fisher exact test) (*unpublished data*). This limited observation suggests that beside increased thickness, other qualitative changes in the choroid may indicate an active process. Their significance and prognosis value remain to be prospectively analyzed.

Whether the choroid is thicker in chronic than in acute CSCR is unclear, according to the available literature (Hamzah et al., 2014; Jirarattanasopa et al., 2012b). The discrepancy between reports is due in part to the inconsistency of the definition of chronic CSCR, as discussed in 2.3.1. A decrease in choroidal thickness has been reported following CSCR resolution, or after physical or medical treatments (Table 4). However, a decrease in large dilated vessels diameter may not be associated with a reduction in choroidal thickness (Fig. 6A and C), masking treatment effect and questioning the optimal endpoints for clinical trials.

Whilst increased choroidal thickness is associated with CSCR, it is not mandatory for its diagnosis as typical cases may not present with increased thickness (Fig. 2B) (Jirarattanasopa et al., 2012b; Kuroda et al., 2013). Furthermore, there is limitation to the comparability of choroidal thickness measurements. Firstly there is a reduction in choroidal thickness with age, axial length, and myopic refractive error, and the choroid is also thinner in females

than in males (Fujiwara et al., 2009; Ikuno et al., 2010; Li et al., 2011; Margolis and Spaide, 2009). Secondly, despite recent advances in automated delineation methods, the repeatability of measurements remains questionable. In all available devices the segmentation of the choroidal boundaries is manual and subject to large intra-observer variability (Mrejen and Spaide, 2013), especially in CSCR where increased choroidal thickness further reduces the reflectivity change at the interface between the outer choroid and the sclera (Kim et al., 2013). In CSCR, the reported intra-observer and inter-observer differences in choroidal thickness measurements were 32–38 μm and 46–57 μm, compared to 19–25 μm and 26–35 μm in normal eyes, respectively (Kim et al., 2013). These limitations should be considered when reporting variations of choroidal thickness after therapeutic intervention.

**2.4.1.2. RPE.** PED is encountered in 53%–100% of CSCR-affected eyes (Ahlers et al., 2009; Mitarai et al., 2006; Van Velthoven et al., 2005; Yang et al., 2013a) (Fig. 6). PED is more frequently reported in chronic CSCR, and is observed inside or outside the subretinal fluid area (Van Velthoven et al., 2005). In addition, PEDs may co-localize with areas of dilated, large choroidal vessels and thickened choroid on SD-OCT, and with vascular hyperpermeability on ICG angiography (Hirami et al., 2007; Yang et al., 2013a), suggesting that PED may result from choroidal flow deregulation. In active CSCR cases, combination of SD-OCT with FA identified an elevation of the RPE or a PED at the leakage sites (Fig. 6G) in most (Fujimoto et al., 2008; Kim et al., 2012; Mitarai et al., 2006) or all cases (Shinojima et al., 2010) from reported series.

**Table 4**  
Decrease in choroidal thickness after treatment or spontaneous resolution.

Author	Treatment	No. of eyes	CSCR type	Mean SFCT at baseline $\pm$ SD ( $\mu$ m)	Mean SFCT after treatment $\pm$ SD ( $\mu$ m) (time from treatment)	SFCT variation (%)	P-value	OCT type
(Pitcher et al., 2015)	Intravitreal aflibercept 2.0 mg (4 or 6 injections)	12	Chronic > 3 months	307 $\pm$ 72	263 $\pm$ 63 (6 months)	-12.7	0.0003	EDI-OCT
(Hua et al., 2014)	1/2-fluence PDT	36	Chronic	470	364 (2–3 weeks) 381 (2–3 months)	-22.5 -18.9	<0.0001	EDI-OCT
(Dang et al., 2014)	1/3-dose PDT	62	Acute	422 $\pm$ 132	362 $\pm$ 113 (1 month) 339 $\pm$ 135 (3 months)	-14.2 -19.7	<0.001	EDI-OCT
(Alkin et al., 2014)	1/2-fluence PDT	32	Chronic > 6 months	517 $\pm$ 98	462 $\pm$ 124 (1 month) 457 $\pm$ 123 (2 months)	-10.6 -11.6	0.003	EDI-OCT
(Razavi et al., 2014)	1/2-fluence PDT	12	Acute > 1 month	421 $\pm$ 108	380 $\pm$ 113 (1 week) 362 $\pm$ 111 (1 month)	-9.6 -13.8	0.005 0.002	SS-OCT
(Brandl et al., 2014)	Oral acetazolamide (125 mg tid, 3 month)	11	<6 months	421 $\pm$ 72	360 $\pm$ 65 (3 months)	-14.5	0.0002	EDI-OCT
	Oral acetazolamide (125 mg tid, 3 month)	9	Fellow healthy eyes	308 $\pm$ 67	287 $\pm$ 57 (3 months)	-6.8	NS	
(Kang and Kim, 2013)	Spontaneous resolution	16	Acute	459 $\pm$ 78	419 $\pm$ 54 (NA)	-8.7	0.015	EDI-OCT
	Low-fluence PDT	20	Chronic > 3 months	416 $\pm$ 74	350 $\pm$ 89 (1 month)	-13.7	0.001	
(Uetani et al., 2012)	1/2-dose PDT	10	Chronic > 3 months	387 $\pm$ 24	374 $\pm$ 23 (4 days) 324 $\pm$ 25 (1 month) 325 $\pm$ 25 (3 months)	-3.2 -16.6 -16.4	NS 0.005 0.005	EDI-OCT
	1/3-dose PDT	6	Chronic > 3 months	351 $\pm$ 17	345 $\pm$ 20 (4 days) 343 $\pm$ 25 (1 month) 355 $\pm$ 22 (3 months)	-1.9 -2.7 -2.0	NS NS NS	
(Maruko et al., 2011b)	1/2-dose PDT	13	Chronic > 6 months	397 $\pm$ 108	441 $\pm$ 120 (2 days) 323 $\pm$ 120 (1 month) 312 $\pm$ 117 (3 months) 317 $\pm$ 117 (6 months) 321 $\pm$ 122 (12 months)	+11.1 -18.7 -21.4 -20.1 -19.1	<0.01 <0.01 <0.01 <0.01 <0.01	EDI-OCT
(Pryds and Larsen, 2012)	1/2-light PDT	16	"Classic" > 3–4 months	421	346 (1 month)	-17.8	0.0001	EDI-OCT
(Maruko et al., 2010)	Laser photocoagulation	12	Acute	345 $\pm$ 127	349 $\pm$ 124 (1week) 340 $\pm$ 124 (1 month)	+1.2 -1.4	NS NS	EDI-OCT
	1/2-dose PDT	8	Chronic >6 months	389 $\pm$ 106	462 $\pm$ 124 (2 days) 360 $\pm$ 100 (1 week) 330 $\pm$ 103 (1 month)	+18.8 -7.5 -15.2	0.008 0.001 <0.001	

EDI-OCT = enhanced depth imaging optical coherence tomography, SFCT = subfoveal Choroidal Thickness, SS-OCT = swept-source optical coherence tomography, PDT = photodynamic therapy, CSCR = central serous chorioretinopathy, LP = laser photocoagulation, 1/2-fluence = 25 J/cm<sup>2</sup>, 6 mg/m<sup>2</sup>, 83 s, 689 nm, 1/2-dose = 50 J/cm<sup>2</sup>, 3 mg/m<sup>2</sup>, 83 s, 689 nm, 1/3-dose = 50 J/cm<sup>2</sup>, 2 mg/m<sup>2</sup>, 83 s, 689 nm, low-fluence = 30 J/cm<sup>2</sup>, 6 mg/m<sup>2</sup>, 50 s, 689 nm, 1/2-light = 50 J/cm<sup>2</sup>, 3 mg/m<sup>2</sup>, 42 s, 689 nm.

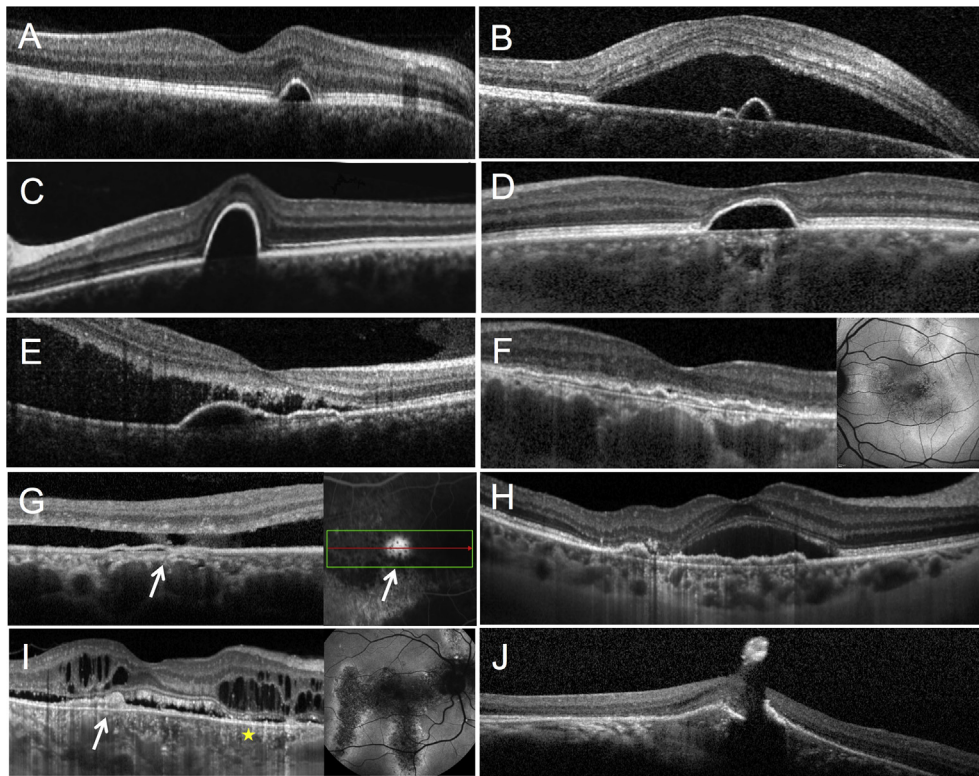
Multiple mechanisms of focal RPE barrier breakdown are likely involved in CSCR progression: mechanical stress resulting from increased intra-choroidal pressure or dilated choroidal vessels, reduced RPE adhesion, alteration of hydro-ionic RPE regulation, and RPE atrophy secondary to choriocapillaris hypoperfusion.

Different types of PED have been described. Whether they result from different mechanisms has not been characterized. Dome-shaped PEDs have a sharply demarcated and protruding appearance, and lack signs of RPE hyperplasia (Fig. 6A–D); en face OCT has been used to assess their morphology and revealed a homogenous hyporeflective circular area with an hyper-reflective border (Ahlers et al., 2009; Van Velthoven et al., 2005). Voluminous dome-shaped PEDs can develop (Fig. 6C), and exceptionally rupture through the neurosensory retina into the vitreous cavity, as observed in an Asian patient (Fig. 6J). This suggests a sustained elevation of the hydrostatic pressure occurring underneath the detached RPE. Irregular or wavy flat PEDs (Fig. 6F–H) have also been described. Irregular PEDs with hyper-reflective content overlying an intact thin hyper-reflective layer (attributed to the Bruch membrane), creating a "double layer sign" are more frequently observed in chronic CSCR (Shin and Lee, 2012; Yang et al., 2013a) (Fig. 6H). Irregular PEDs could result from a loss of elasticity of the adjacent RPE basement membrane, due to chronically elevated RPE. We also have observed shallow PEDs in chronic CSCR cases, as shown in Fig. 6E, suggesting that adhesion of the RPE might be altered in such cases. The exact site of cleavage has not been ascertained by any histologic analysis of a CSCR eye but it seems that the RPE and its own basal membrane (the most inner layer of Bruch membrane)

detach from the other layers of Bruch membrane, which remain attached to the choriocapillaris basal membrane. Abnormal ion and water transport through the RPE could contribute to the formation of a fluid pocket on the basolateral side of the RPE, favoring its subsequent detachment. The mechanisms of RPE reattachment are not well understood, and PED can fluctuate independently from the subretinal fluid. With time, the content of a PED could change and the residual protein content could contribute to the formation of a thicker RPE band as observed on SD-OCTs of long-standing cases.

As mentioned, the formation of PEDs seems to be tightly associated with choroidopathy since PEDs co-localize frequently with areas of choroidal vascular anomalies on SD-OCT and ICG. Recently, a study evaluating 15 eyes by swept-source en face OCT found RPE changes overlying areas of choroidal vascular dilatation in all eyes, further supporting the correlation between epitheliopathy and choroidopathy. Interestingly, these dilatations were mostly focal within the choriocapillaris, equally focal and diffuse at the level of Sattler's layer and mostly diffuse at the level of Haller's layer (Ferrara et al., 2014).

Whether epitheliopathy and choroidopathy both result from a common pathogenic factor or whether the abnormal choroid induces secondary epitheliopathy that in turn permits fluid passage into the subretinal space remains uncertain. In advanced CSCR cases (also termed "diffuse retinal pigment epitheliopathy"), large areas of RPE alterations and detached RPE may not be systematically associated with subretinal fluid (Fig. 6F). In a series of 38 eyes, one third of patients with either active or inactive CSCR had multiple small PEDs located both within and outside the area of serous



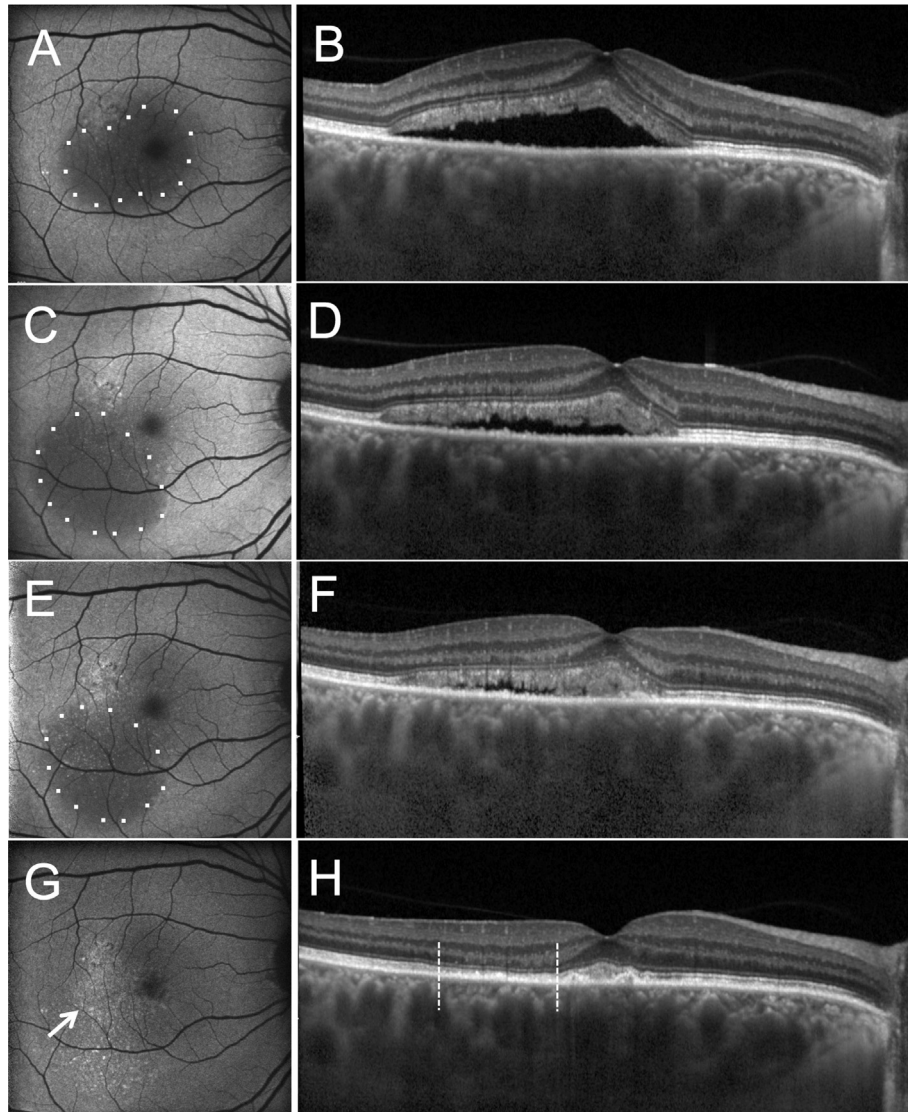
**Fig. 6.** Spectrum of retinal pigment epithelium detachment in central serous chorioretinopathy on SD-OCT. (A) Acute CSCR, two months after regression of symptoms, with a small and localized dome-shaped pigment epithelial detachment (PED) persisting despite the resolution of subretinal fluid. (B) Double dome-shaped PED and otherwise healthy RPE inside a subretinal detachment area. (C) Protruding subfoveal dome-shaped PED despite resolution of subretinal fluid, producing foveal tilting and metamorphopsia. (D) Residual subfoveal dome-shaped PED overlying a pachychoroid. (E) Shallow PED with hyporeflective content in a patient with active CSCR. (F) Extended wavy flat PED with hyper-reflective content overlying a pachychoroid with dilated vessels; granular hypo-autofluorescence corresponding to this diffuse epitheliopathy. (G) Flat PED at the level of a leakage site (arrow, evidenced on the fluorescein angiogram) in active CSCR. Visible hyper-reflective fibrin/protein flow related to the leak. (H) Irregular or wavy flat PED with hyper-reflective content overlying a continuous thin hyper-reflective layer, realizing a “double layer sign”. (I) Chronic CSCR with typical hypo-autofluorescent gravitational tracks (evidenced on fundus autofluorescence), intraretinal cystoid degeneration and intraretinal hyper-reflective dots. There is a diffuse pigment epitheliopathy, with areas of RPE hyperplasia (arrow) and RPE atrophy (star). (J) Spontaneously ruptured PED in a CSCR patient from India, with resulting full-thickness retinal defect and expulsion of hyper-reflective material in the vitreous cavity, suggesting that the hydrostatic pressure was elevated inside the PED.

retinal detachment, suggesting a more diffuse RPE dysfunction (Van Velthoven et al., 2005). The difference between “simple” acute CSCR and chronic cases relies mainly on the extension of RPE involvement. Besides PEDs, focal RPE tears, areas of RPE atrophy and RPE hypertrophy have been described, and may belong to a wider spectrum of localized and diffuse epitheliopathy involved in the different stages of CSCR (Lim and Wong, 2008; Piccolino et al., 2008a; Yalcinbayir et al., 2014; Yang et al., 2013a) (Fig. 6I). With time, the chronic course of the disease associated with aging leads to widespread RPE atrophy and irregular PEDs. Exclusion of a neovascular component can be challenging at this advanced stages. Interestingly, drusen are typically not observed in CSCR eyes, suggesting that epitheliopathy in CSCR and AMD originates from different mechanisms, even if late complications may be similar.

**2.4.1.3. Neurosensory retina.** One of the characteristics of acute CSCR is that despite subretinal fluid, the morphology of retinal layers remains unchanged, except for the elongation of photoreceptor outer segments. No reduction or fluid accumulation is observed in neuronal layers. However after several years of disease duration, intraretinal cysts can form (Fig. 6I). They may disappear or fluctuate, suggesting fluid passage through a compromised RPE contribute to their formation. Interestingly, in the inter-papilomacular region, intraretinal cysts are often observed earlier in the disease evolution, over areas of RPE atrophy (Iida et al., 2003; Piccolino et al., 2008a, 2008b). Hyper-reflective dots frequently

accumulate in the subretinal space below the detached neurosensory retina (Kon et al., 2008; Maruko et al., 2011a; Spaide and Klancnik, 2005) and within several retinal layers (Ahlers et al., 2009; Kon et al., 2008; Yalcinbayir et al., 2014). These dots, identified on SD-OCT, co-localize with hyper-autofluorescent area on FAF (Iacono et al., 2015; Maruko et al., 2011a; Spaide and Klancnik, 2005). As disease persists over time, the number of dots located in the subretinal space tends to increase (Wang et al., 2005) and correlates with worse final visual acuity (Landa et al., 2013, p. 201; Yalcinbayir et al., 2014). The origin and nature of these dots may be multiple depending on their size and location. In the subretinal space, macrophages and microglia are likely to be activated by the photoreceptor outer segments shedding (Maruko et al., 2011a). Concentration of protein-like compounds, fibrin or lipids could also be identified as dots (Kon et al., 2008). During acute CSCR evolution, the intraretinal hyper-reflective dots progress from the inner to the outer retinal layers and slowly resolve upon resolution of SRD (Plateroti et al., 2014). Chronic and recurrent forms of CSCR are more frequently associated with intraretinal hyper-reflective dots (Ojima et al., 2007).

Elongation of photoreceptor outer segments in the area of a macular SRD is a frequent SD-OCT finding in CSCR (Matsumoto et al., 2008). They are more frequent when white-yellowish precipitates are observed on fundus examination, corresponding to patchy increased autofluorescence (Fig. 7) (Matsumoto et al., 2011). Just above the leaking point, an erosion of photoreceptor outer



**Fig. 7.** Progressive elongation of photoreceptor outer segments in acute central serous chorioretinopathy. Acute CSCR in a 61 year-old female patient. SD-OCT at baseline, 1, 2 and 4 months (B, D, F, H, respectively) shows progressive elongation of photoreceptor outer segments over the course of CSCR resolution. Fundus autofluorescence initially showed a decreased autofluorescence (dots) due to the RPE masking by these elongated outer segments (A), which progressively faded due to the accumulation of autofluorescent byproducts in these segments (C, E), and finally left a granular hyper-autofluorescence after episode resolution (G, arrow). This hyper-autofluorescence may originate from outer segments disruption (H, within dotted lines) creating a window defect.

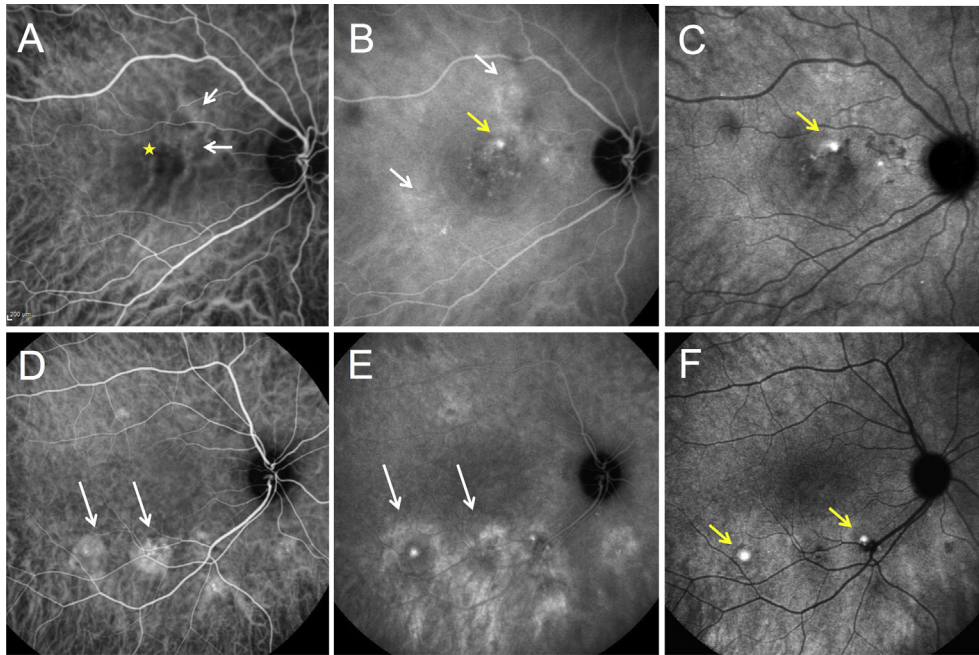
segments may be visible on SD-OCT, suggesting a mechanical abrasion resulting from an active flow through the RPE break (Fig. 2A). Persistent thick outer segments may progress to permanent subretinal deposits with subsequent poor visual prognosis after subretinal fluid absorption. Complete disappearance of outer segments as observed in very long-standing SRD correlates with poor visual outcome. Disruption of the ellipsoid zone (formerly known as the junction between the inner and outer segments of photoreceptors), of the external limiting membrane and thinning of the outer nuclear layer are also negative visual prognosis factors (Eandi et al., 2005; Matsumoto et al., 2009, 2008; Ojima et al., 2007; Piccolino et al., 2005; Yalcinbayir et al., 2014). These findings are consistent with recent observations on adaptive optics scanning laser ophthalmoscopy (see 2.4.5).

#### 2.4.2. Fundus autofluorescence

Short-wavelength FAF mostly originates from the RPE lipofuscin (Delori et al., 1995). Images obtained by confocal FAF provide

information reflecting RPE health and allow a non-invasive detection of a spectrum of changes at different phases and forms of CSCR. Focal areas of hypo-autofluorescence at the level of the leakage points are indeed observed in 70–100% of eyes with acute CSCR (Fig. 2D), which supports the hypothesis of a focal RPE defect or detachment of RPE cells at this site (Ayata et al., 2009; Eandi et al., 2005; Iacono et al., 2015; Kim et al., 2013). In recurrent CSCR, the leakage point is usually different from previous episodes but locates in the vicinity of the first one, reflecting a barrier weakness persisting in this area.

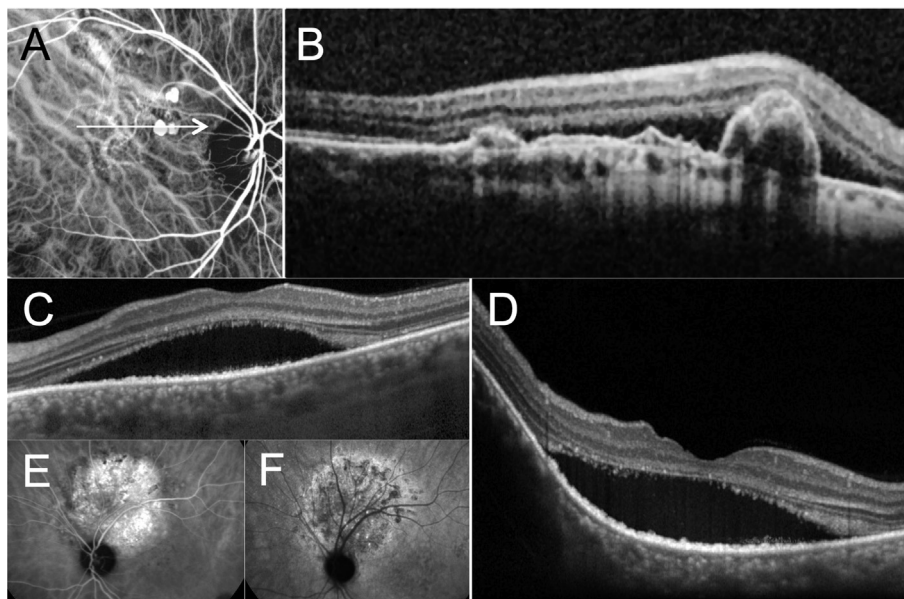
In acute CSCR cases, a diminished FAF is initially seen in an area corresponding to the SRD. It may either return to normal, as observed in a majority of cases after SRD resolution (Iacono et al., 2015), or be progressively replaced by an increased FAF, as observed in episodes persisting more than 4 months (Framme et al., 2005). While the masking produced by the SRD and the elongated photoreceptor outer segments could explain the initial decrease in FAF (Fig. 7), the accumulation of non-shed fluorophores in these



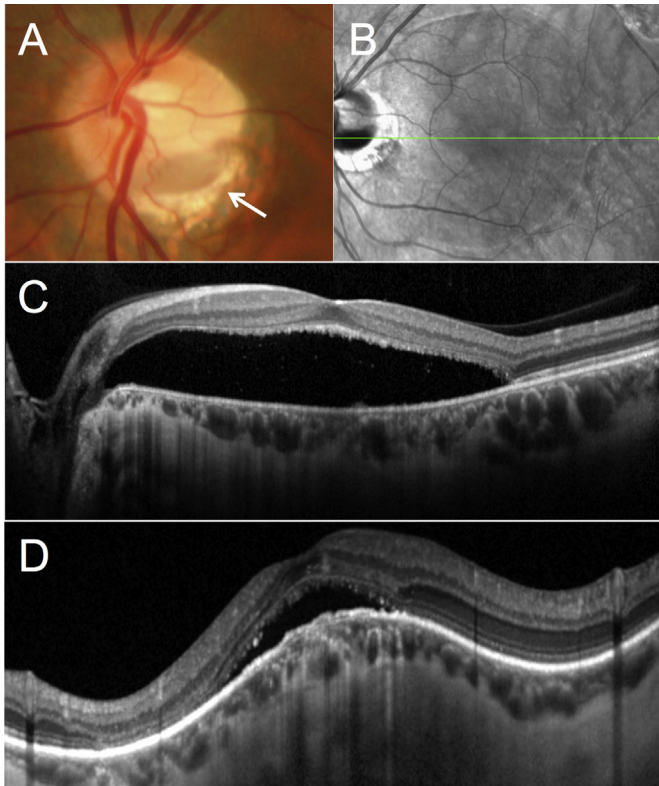
**Fig. 8.** Indocyanine green angiography anomalies in two cases of acute CSCR. In a fifty-year old man with acute CSCR, focal hypofluorescence during early phase (A) indicated delayed choriocapillaris filling (star) and enlarged choroidal veins were visible (arrows). Multifocal hyperfluorescence areas with blurred contours indicating choroidal vascular hyperpermeability (white arrows) appeared during mid phase (B) and faded at late phase (C). A hyperfluorescent punctate spot (yellow arrow) during mid- and late phase corresponded to the leakage point on fluorescein angiography (not shown). In a thirty-two year-old male with acute CSCR, there was multifocal hyperpermeability (arrows) visible during mid phase indocyanine green angiography (D), with a progressive circular extension (E) and fading during the late phase (F). Again, two punctate spots (yellow arrow) with persisting focal hyperfluorescence corresponded to leakage points on the fluorescein angiogram (not shown).

elongated outer segments may account for the subsequent increased patchy FAF in the SRD area of non-resolving cases (Matsumoto et al., 2011). In addition, a residual granular increased FAF may remain visible after resolution and correlates with intraretinal hyper-reflective dots on SD-OCT (Iacono et al., 2015). It has been recently proposed that this residual granular hyper-

autofluorescence after CSCR resolution could originate from a loss of photoreceptor outer segments. Indeed, these outer segments are densely filled by photopigments (opsins in cones and rhodopsin in rods), which absorb the blue light and block partially the RPE autofluorescence in healthy conditions (Freund et al., 2013) (Figs. 4A, H and 7G, H). Finally, in two separate case series involving



**Fig. 9.** Related entities and differential diagnosis of central serous chorioretinopathy. Polypoidal choroidal vasculopathy with multifocal nodular hyperfluorescence and choroidal hyperpermeability on indocyanine green angiography (A), and a subretinal detachment overlying a pigment epithelial detachment with polypoidal hyper-reflective content on SD-OCT (B). Choroidal hemangioma manifesting with a serous retinal detachment (C), suspected by the visualization of a sub-RPE mass on oblique SD-OCT sections (D) and confirmed by indocyanine green angiography with progressive hyperfluorescence (E) and late wash-out (F). (Images 11 C–F: courtesy of Leonidas Zografos, Lausanne, Switzerland).



**Fig. 10.** Related entities and differential diagnosis of central serous chorioretinopathy. Optic disc pit visualized on a fundus photograph (A, arrow) associated with serous retinal detachment on infrared reflectance (B) and SD-OCT (C). Serous retinal detachment complicating dome-shaped macula in a myopic eye (D). (Images 10A–B: courtesy of Jean-Antoine Pournaras, Lausanne, Switzerland).

CSCR patients geographic or granular decrease in foveal FAF correlated with poor visual acuity (Imamura et al., 2011; Spaide and Klancnik, 2005), confirming that FAF provides valuable morphological and functional information regarding RPE health.

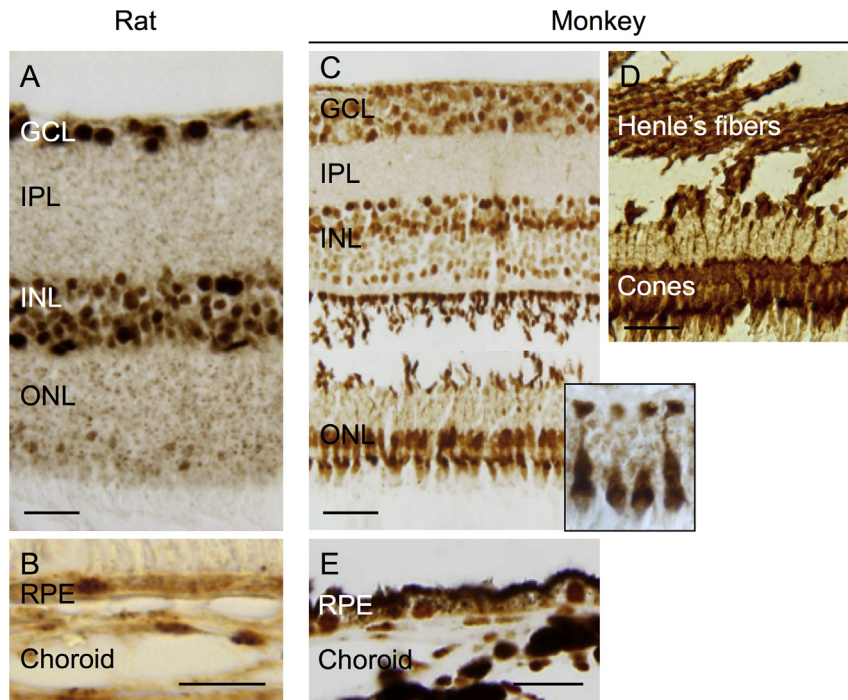
In fellow eyes of unilateral cases, previous unnoticed extramacular episodes or focal RPE alterations may produce variable FAF changes, mostly depending on the age of the lesions, with increased autofluorescence for fresh lesions and decreased autofluorescence for older lesions, frequently associated with punctate hyperautofluorescent spots.

In the chronic forms of CSCR, FAF appearance is pathognomonic with multiple oblong descending tracks of decreased FAF, often originating from the optic disc and the macula, that have been referred to as “gravitational tracks” due to their inferior and vertical topography. They are surrounded by a thin contour of increased FAF (Figs. 3 and 6l). The exact significance of these lesions is not elucidated, although it has been suggested that they may result from chronic movements of residual subretinal fluid (Agarwal, 2012; Framme et al., 2005; Spaide and Klancnik, 2005; von Rückmann et al., 2002).

Near-infrared autofluorescence is another non-invasive imaging modality based on the autofluorescence emanating mostly from choroidal and RPE melanin (Keilhauer and Delori, 2006). Although not routinely employed in the evaluation of patients with CSCR, near-infrared FAF is an interesting imaging modality showing in acute cases an initial autofluorescence decrease. Subsequently it evolves into complete resolution (Kim et al., 2013), or exhibits a granular pattern indicating long-term changes in RPE melanin distribution following a CSCR episode (Ayata et al., 2009; Sekiryu et al., 2010).

2.4.3. Fluorescein angiography

In acute CSCR, FA usually identifies one or several leakage points



**Fig. 11.** Mineralocorticoid receptor immunohistochemistry in rat and monkey retina. Immunohistochemistry of MR on paraffin rat (A and B) and monkey (C–E) retinal sections. The mineralocorticoid receptor (MR) is localized in nuclei (dark brown) in the ganglion cell layer (GCL), the inner nuclear layer (INL) (A), the retinal pigment epithelium (RPE) and the choroidal vascular endothelial cells (B). In the monkey, MR is localized in the same layers (C and E) and is also identified in cone photoreceptors in the macula (C and inset) and in the fovea (D). INL = Inner nuclear layer, IPL, inner plexiform layer; ONL, outer nuclear layer. Bar: A, C and D, 20 µm; B and E, 10 µm.



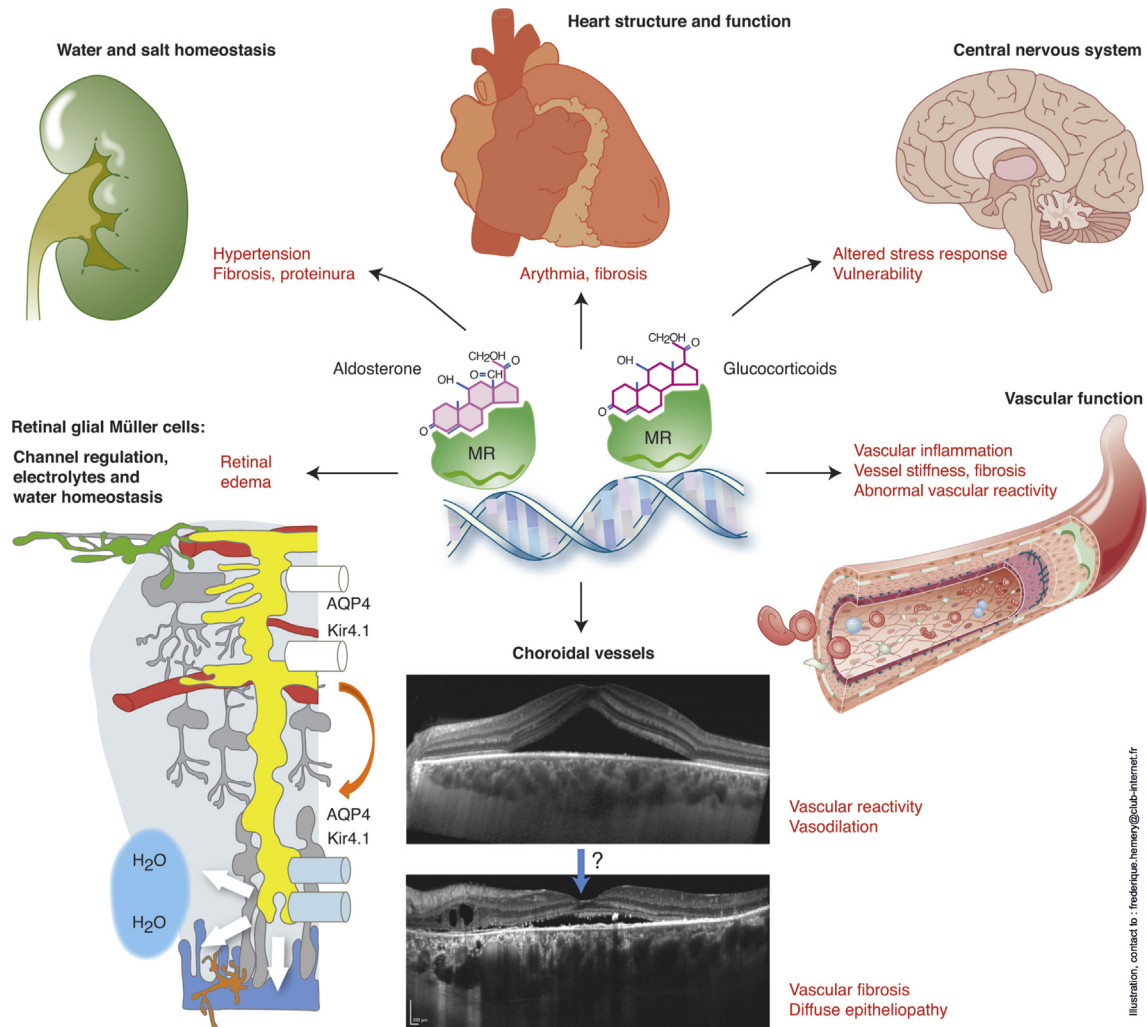


Fig. 12. Scheme of hypothetic links between CSCR and known effects of MR inappropriate activation in various mineralocorticoid-sensitive organs.

localized within or adjacent to areas of SRD (Figs. 1A, D and 2C). Although not mandatory for the diagnosis of CSCR, FA is helpful to confirm the diagnosis and serves as a guide for possible laser treatment of eccentric leaks (Yannuzzi et al., 2000). Acute cases usually present with a single leakage site, rarely two or more (Burumcek et al., 1997). In occurrences where more than one site of leakage is observed, a single site is usually responsible for the ongoing episode and can be identified by FA. In acute CSCR, leakage sites present most frequently as pinpoints of increasing fluorescence along the sequence. They can also follow two classical patterns: the “ink-blot” pattern, with a progressive expansion of a circular hyperfluorescence arising from a central pinpoint, or the “smokestack” pattern, in which the hyperfluorescence ascends with a slight lateral diffusion producing a mushroom-like image above the leaking point. In a study of 479 acute, recurrent and chronic cases, a smokestack leak was observed in 14% of subjects, and was predominantly associated with acute early forms, with a mean of 15 days since onset of symptoms (Bujarborua et al., 2010). In the mid and late phases, dye pooling into the SRD leads to a diffuse circular hyperfluorescence within the SRD area. PED, a frequent feature of CSCR, is characterized by early fluorescein pooling with a resulting hyperfluorescence persisting during late phase.

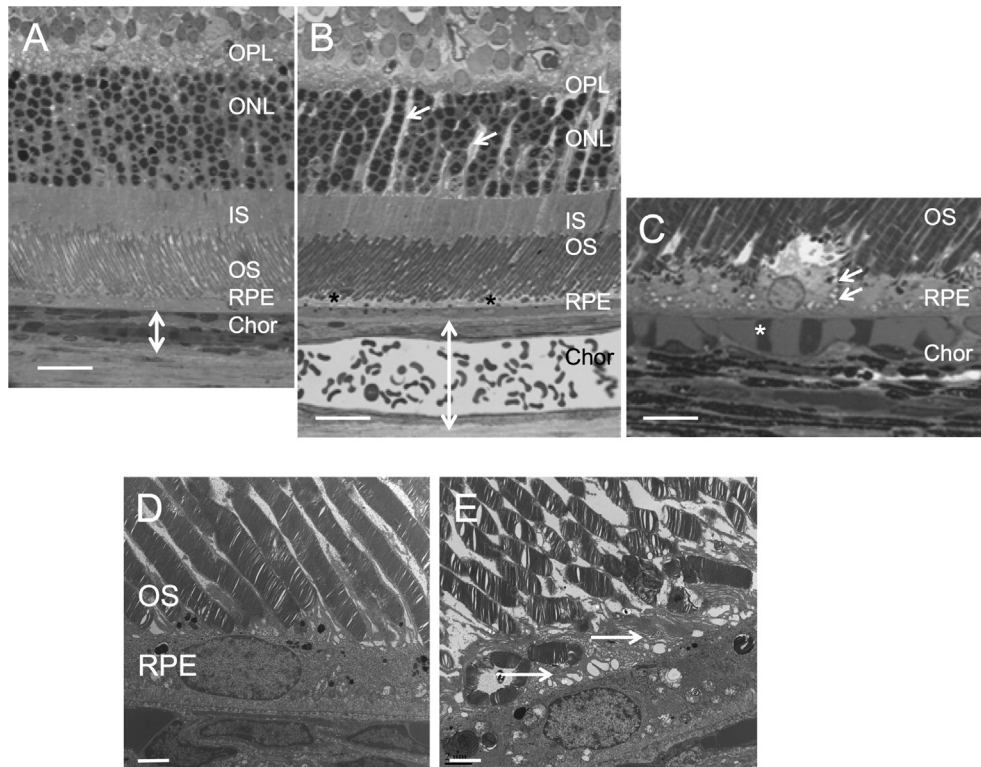
In chronic forms, diffuse RPE defects provoke multifocal leakage points visible in mid- and late phases as patches of granular

hyperfluorescence (Yannuzzi et al., 1984) (Fig. 3B and C).

Finally, sequelae of unnoticed extramacular episodes in affected or fellow eyes appear as hyperfluorescent areas because of increased transmission through localized RPE atrophy (Fig. 4B and C).

#### 2.4.4. Indocyanine green angiography

Since its introduction in the early 1990s, digital, and now confocal ICG angiography has become the gold standard to image the choroidal vasculature. In CSCR, it provides an insight into choroidal changes contributing to the disease process, and essential data to distinguish complex chronic cases from differential entities. In particular, it helps to identify CNV complicating CSCR (Spaide et al., 1996a; Yannuzzi, 2011). Patterns observed on ICG angiography result from the biochemical properties of indocyanine, a molecule with twice the molecular weight of fluorescein. Due to its amphiphilic nature, it possesses affinity for hydrophilic structures (as certain proteins), lipophilic structures (as LDL- and HDL-cholesterol) or both (as membrane phospholipids) and stains the intravascular content, the vascular walls, and extravascular structures like the choroidal stroma. Moreover, its optical absorption/emission spectra is shifted towards near-infrared frequencies compared to the spectrum of fluorescein, which allows the ICG signal to be better transmitted through the RPE (Desmettre et al., 2000).



**Fig. 13.** Aldosterone-induced retinal phenotype. Compared to vehicle-injected eyes (A), aldosterone-injected rat eyes showed retinal glial Müller cells swelling (arrows), increased choroidal thickness (bidirectional arrow) and dilated choroidal vessels (B). Swelling of retinal pigment epithelial (RPE) cells and focal disruption of the RPE tight junctions (arrow) are found adjacent to the dilated choroidal vessels (star, C). Increased thickness of RPE apical microvilli can be observed on semi-thin sections (B, stars) and on transmission electron microscopy (E, arrows) as compared to the vehicle-injected eye (D). INL, inner nuclear layer; IS/OS, inner and outer segments of photoreceptors. Bar: A and B, 20  $\mu$ m; C, 10  $\mu$ m; D and E, 2  $\mu$ m.

The alterations of the choroidal vasculature observed by ICG angiography in CSCR-affected eyes are: (Figs. 3, 4 and 8).

- Early phase: delayed initial filling of arteries and choriocapillaris (Prünte, 1995), hypofluorescent areas resulting from decreased choriocapillaris filling, and persisting in mid- and late phases (Kitaya et al., 2003) (Fig. 8A).
- Midphase: dilation of large choroidal veins in areas correlating to atrophic or elevated RPE on OCT (Hirami et al., 2007), geographic areas of hyperfluorescence with blurred contours classically interpreted as choroidal vascular hyperpermeability, one of the hallmarks of CSCR imaging (Piccolino and Borgia, 1994; Spaide et al., 1996b) (Fig. 8B and D).
- Late-phase: the mid-phase hyperfluorescent areas evolve into either persistent hyperfluorescence, wash-out or centrifugal displacement of the hyperfluorescence, forming hyperfluorescent rings (Tsujikawa et al., 2010) (Fig. 8C, E and F).

The essential role of choroidal hyperpermeability in CSCR pathogenesis is illustrated by the fact that areas of hyperfluorescence in the midphase of ICG angiograms persist after leakage ceases on FA (Scheider et al., 1993), and recurrence of CSCR with new leakage develops in areas of persistent midphase ICG hyperfluorescence (Iida et al., 1999).

The areas of PED also exhibit a typical course along the sequence of ICG angiography:

- Early phase: mild hyperfluorescence
- Mid-phase: variable hyperfluorescence
- Late phase: marked hypofluorescence surrounded by a possible hyperfluorescent ring, attributed to ICG affinity to fibrin

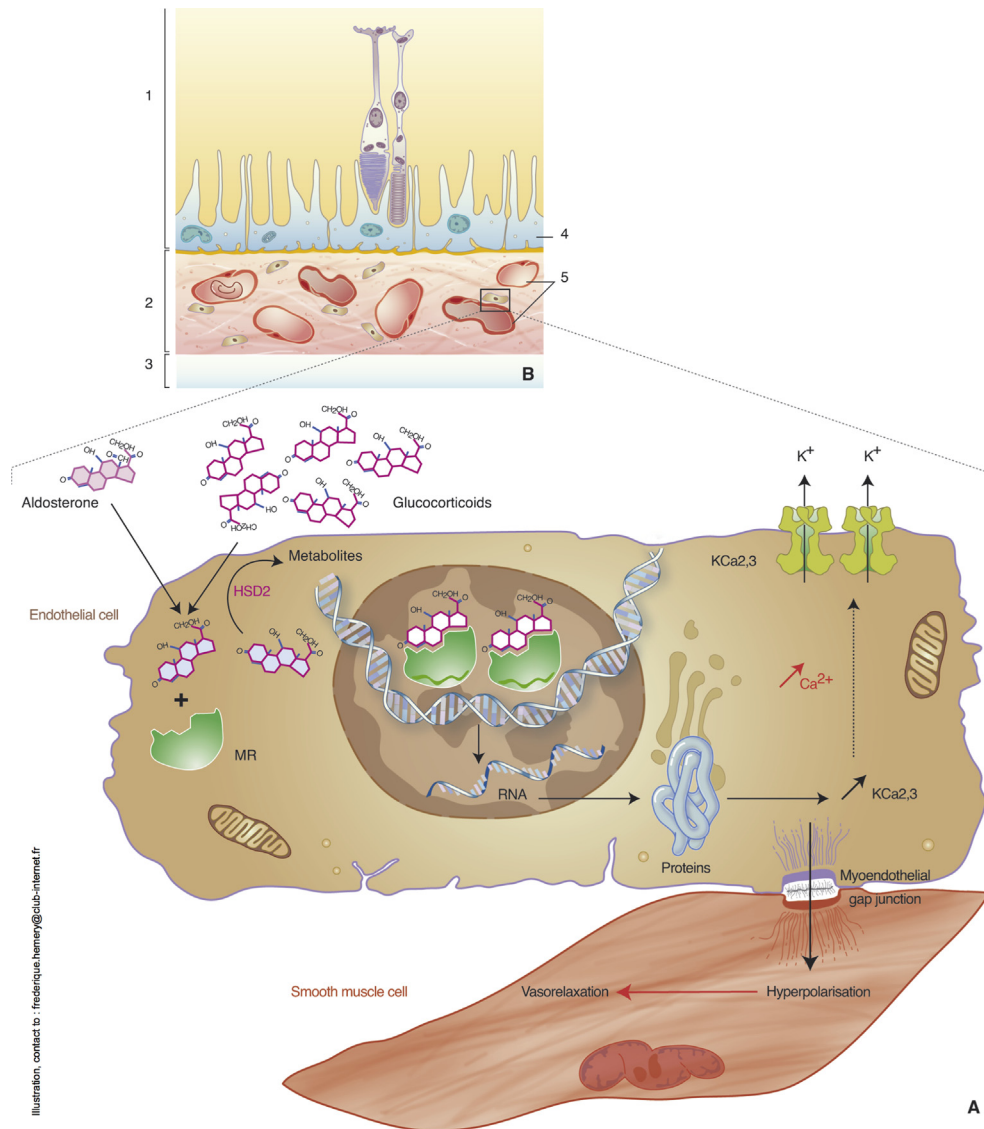
deposits at the margins of the PED (Guyer et al., 1994; Mrejen et al., 2013). Noticeably, a large PED can appear hyperfluorescent if it has an abundant fibrin content stained by ICG, or a PED overlying an area of hyperpermeability.

In addition, punctate hyperfluorescent spots have been detected during mid- and late phases in 80–93% of active CSCR. In 61–66% of eyes they correlated with areas exhibiting one or more of the choroidal vascular changes listed above on ICG angiography. These punctate hyperfluorescent spots were also observed in unaffected retinal areas in 55% of affected eyes, and in more than 80% of contralateral eyes. They were significantly associated with increased choroidal thickness, not only in CSCR, but also in PCV and to a lesser extent in AMD, and may be a manifestation of the increased choroidal hyperpermeability and intrachoroidal hydrostatic pressure (Park et al., 2014; Tsujikawa et al., 2010).

On ICG angiography, choroidal changes similar to those of affected eyes were observed in more than half of asymptomatic fellow eyes (Iida et al., 1999; Tsujikawa et al., 2010).

#### 2.4.5. Adaptive optics

Adaptive optics scanning laser ophthalmoscopy (AO-SLO) is a technique allowing in vivo visualization of individual cone photoreceptors by compensating for the optical aberrations of ocular media. However, this developing imaging modality is limited by the presence of subretinal or intraretinal fluid. In the only published report to date, it has been used to evaluate the photoreceptor layer changes in 38 patients with resolved CSCR, compared to 20 normal subjects (Ooto et al., 2010a). Normal eyes presented a regular photoreceptor mosaic while CSCR eyes exhibited two distinct patterns: a regular cone mosaic with small dark regions, and an



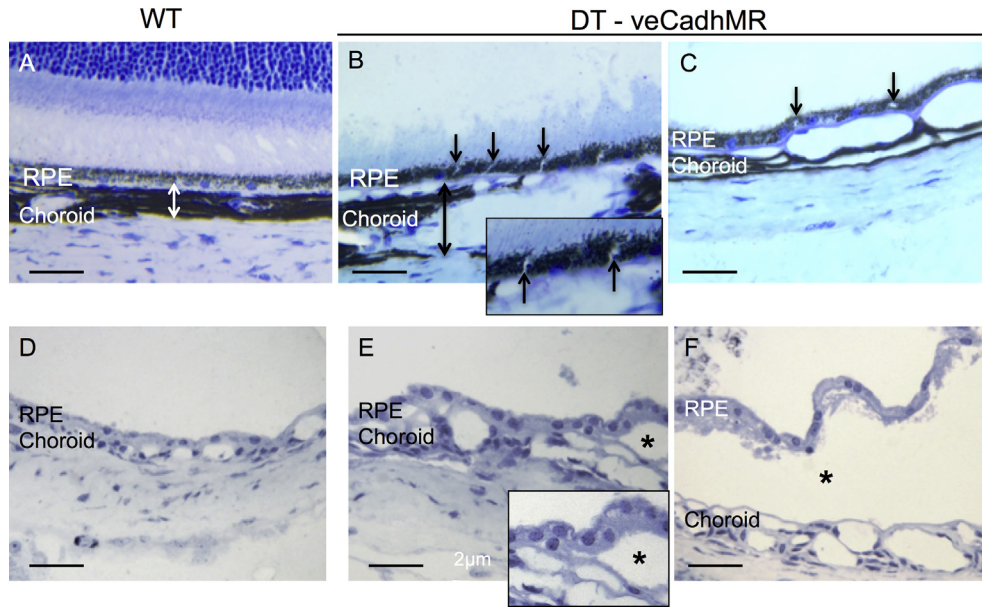
**Fig. 14.** Suggested mechanism of mineralocorticoid receptor (MR) activation by mineralo- and glucocorticoids on the choroidal vascular endothelial cell leading to choroidal vascular dilatation by the up-regulation of KCa2.3. Permanent MR occupancy by glucocorticoids is prevented by the metabolizing enzyme 11-beta hydroxysteroid dehydrogenase type 2 (11 $\beta$ HSD2), which transforms the glucocorticoids into metabolites that have a weak affinity for MR. Activation of the MR pathway by either aldosterone or glucocorticoids induces up-regulation of the endothelial vasodilatory potassium channel KCa2.3 (calcium-dependent channel) that leads to the hyperpolarization of endothelial cells and underlying smooth muscle cells (electric coupling through myo-endothelial gap junctions) resulting in choroid vasodilation. K<sup>+</sup>, potassium; Ca<sup>2+</sup>, calcium.

irregular cone mosaic with large dark regions. These dark regions probably reflect severe disturbances of the photoreceptor layer. Average cone density measured at a distance of 0.2 mm, 0.5 mm and 1 mm from the fovea was higher in normal eyes than in CSCR eyes. Among CSCR patients, eyes harboring an irregular cone mosaic with large dark regions presented lower average cone density and worse average visual acuity, than these eyes with regular cone mosaic and small dark regions. In addition, eyes with disrupted ellipsoid band on SD-OCT had a lower mean cone density than eyes with intact ellipsoid band, a finding consistent with the correlation of outer retinal layers integrity on SD-OCT with favorable visual outcome, as described in 2.4.1.3.

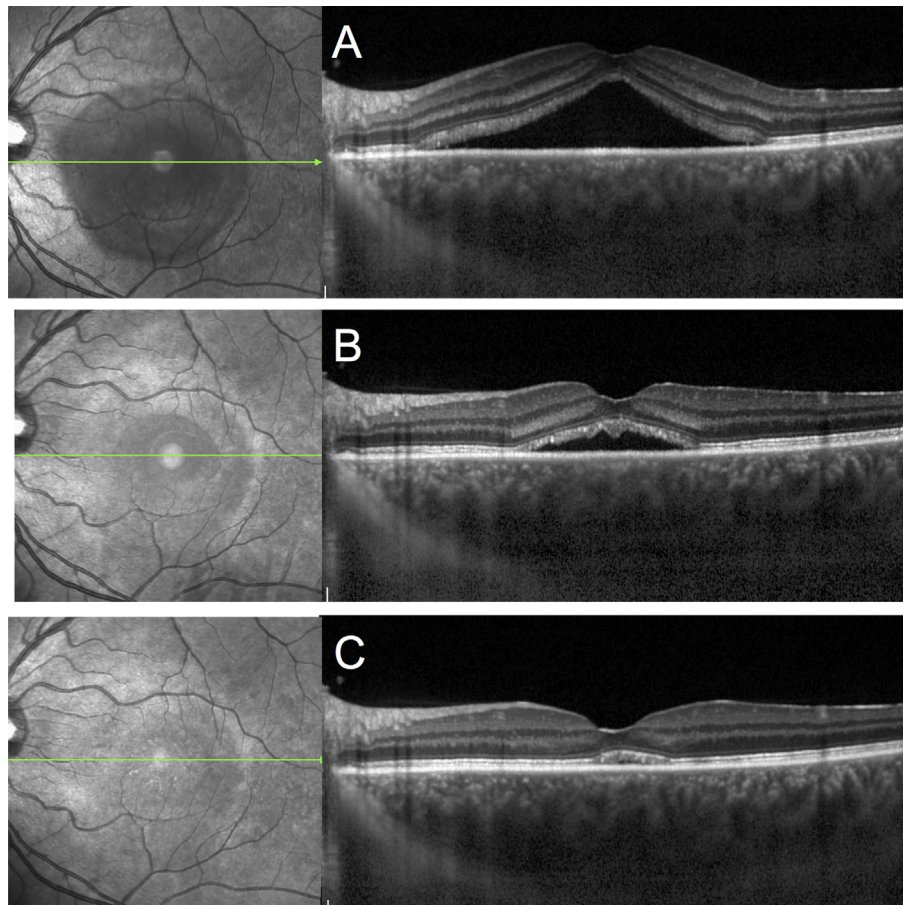
#### 2.4.6. Choroidal blood flow

The measure of choroidal blood flow relies on the interaction between a physical signal (a laser beam) and the movement of red blood cells in the choroidal vasculature. Choroidal blood flow changes have been reported in CSCR patients, based on three

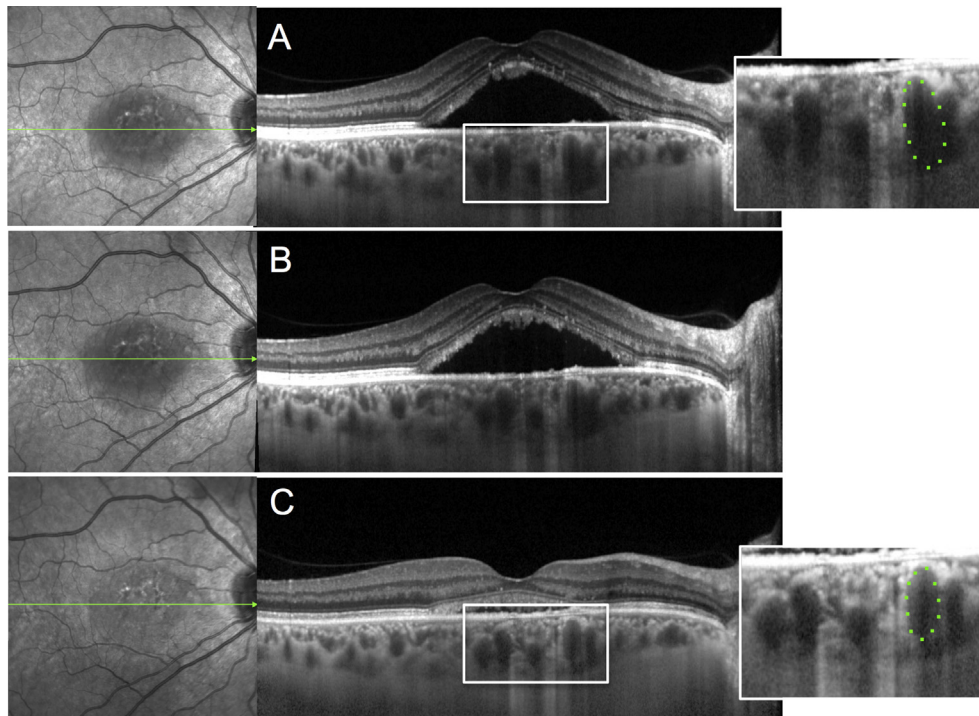
different devices: laser doppler flowmetry, laser interferometry and laser speckle flowgraphy (Table 5). On laser doppler flowmetry, acute CSCR eyes showed a reduction of 45% in foveal choroidal blood flow compared to healthy fellow eyes. The decreased choroidal blood flow might be correlated with the localized, non-perfused areas of the choriocapillaris frequently seen during ICG angiography (Kitaya et al., 2003). However, using a laser interferometry, the foveal fundus pulsation amplitude was significantly higher in CSCR eyes than in control eyes, suggesting choroidal hyperperfusion in CSCR patients (Tittl et al., 2003). The wavelength used in laser doppler flowmetry is shorter than in laser interferometry, which allows for the detection of red blood cells in the choriocapillaris rather than in the deeper large choroidal vessels. Therefore, these results might reflect the variability of the blood flow in the different layers of the choroid. Interestingly, macular mean blur rate, an indicator of relative blood flow velocity, decreased with the regression of CSCR activity; this decrease was inversely correlated with BCVA recovery (Saito et al., 2013).



**Fig. 15.** Choroidal phenotype of double transgenic (DT) *veCadhMR* mice. (A–C) Pigmented mice strain. (D–F) Albinos mice strain. In both strains, the human mineralocorticoid receptor (hMR) is specifically over expressed in the vascular endothelium (*ve* Cadherin promoter). Compared to wild-type (WT, A and D), the double transgenic (DT) mice present choroidal thickening (bidirectional arrow) and choroidal vessel dilation (B, C, E and F). Disruption of tight junctions (arrows) between the retinal pigment epithelial (RPE) cells (B, inset and C) and RPE detachment (asterisk in E, inset and F) are associated with choroidal vasculopathy in DT mice. Bar: 25  $\mu$ m.



**Fig. 16.** Non-resolving recurrent central serous chorioretinopathy treated by mineralocorticoid-receptor antagonist. Thirty-nine-year old patient treated by oral eplerenone (25 mg daily) for recurrent CSCR without improvement after 2-month observation. Enhanced-depth imaging OCT at baseline (A) shows subretinal detachment, and pachychoroid (665  $\mu$ m). A decrease in subretinal fluid was observed 4 and 5 weeks after initiation of treatment (B and C, respectively), with a parallel decrease in subfoveal choroidal thickness (638  $\mu$ m and 623  $\mu$ m, respectively).



**Fig. 17.** Non-resolving central serous chorioretinopathy treated by mineralocorticoid-receptor antagonist. Fifty-year old patient treated by oral eplerenone (25 mg daily) for persistent CSCR with non-resolving subretinal fluid. Enhanced-depth imaging OCT showed a stationary subretinal detachment during a 4-month observation period (A and B). A decrease in subretinal fluid was observed 2 months after initiation of treatment (C). At the level of the subretinal detachment, the choroidal vascular dilatation decreased, as shown in the outlined vessel (white dotted line, inset) with a vascular surface change from 0.08 mm<sup>2</sup> at baseline to 0.05 mm<sup>2</sup> after resolution.

Different interventions modifying the choroidal blood flow have been reported. Isometric exercise induced a more significant increase in choroidal blood flow in patients with chronic, inactive CSCR than in healthy patients, suggesting an inadequate vasoconstrictor response in CSCR patients (Tittl et al., 2005).

## 2.5. CSCR related entities and differential diagnosis

Table 6 recapitulates the most relevant entities that could be misdiagnosed as CSCR, and presents the clinical and imaging features that differentiate them from acute or chronic CSCR.

### 2.5.1. Polypoidal choroidal vasculopathy (PCV)

PCV (Fig. 9A and B) is considered a variant of CNV as the branching vascular network originates from the choroidal vasculature. But whether real neovascular proliferation occurs is yet to be verified. According to recent guidelines, PCV should be suspected when a SRD is associated with at least one of the following features: subretinal orange nodules or massive submacular hemorrhage on fundus examination, serous, sero-sanguineous or notched PEDs on OCT, or non-response to anti-vascular endothelial growth factor (VEGF) therapy. PCV is confirmed by ICG angiography, showing during early-phase an abnormal vascular network with single or

**Table 5**  
Reported methods of choroidal blood flow assessment.

Author	Type of Laser Parameters	No. of CSCR patients	CSCR type	No. of controls (type)	Results	P value
(Kitaya et al., 2003)	Laser Doppler Flowmetry Diode Laser beam = 670 nm Intensity = 20 μW Diameter = 200 μm	11	Acute	11 (fellow eyes)	The foveal CBF in eyes with CSCR was 45% lower than in fellow eyes (6.27 vs 11.41 a.u.)	<0.01
(Tittl et al., 2003)	Laser Interferometry Laser beam = 780 nm Intensity = 80 μW Diameter = 20–50 μm	18	Acute	18 (healthy patients)	The foveal FPA was higher in eyes with CSCR than in control eyes (5.5 μm vs 4.1 μm)	0.005
(Tittl et al., 2005)	Laser Doppler flowmetry Laser beam = 785 nm Intensity = 90 μW Diameter = 50–100 μm	14	Chronic- inactive	14 (healthy patients)	Isometric exercise induced a more significant increase in CBF in patients with CSCR than in controls (20% vs 10%)	0.001
(Saito et al., 2013)	Laser speckle flowgraphy Diode laser beam = 830 nm	21	Acute	—	MBR decreased with the course of CSCR (92.8% of baseline value at 3 month and 82.3% at 6 months) Inverse correlation between BCVA improvement and MBR decrease.	0.016 0.000003

FPA = fundus pulsation amplitude, CBF = choroidal blood flow, MBR = macular mean blur rate, BCVA = best-corrected visual acuity, CSCR = central serous chorioretinopathy.

multiple focal nodular areas of hyperfluorescence identified as “polyps” (Koh et al., 2013). Since PCV and CSCR both present with serous detachments and RPE abnormalities, the distinction between both entities may be complex. Small polyps may be only associated with a SRD or non-specific PEDs, without other exudative manifestations. On the other hand, advanced CSCR cases may harbor diffuse blood-retinal barrier disruption, lipid exudates and even macular hemorrhage when complicated by CNV, possibly fulfilling the criteria of presumed PCV.

The overlap between the two entities has been illustrated in a series of 13 cases initially diagnosed as CSCR, but in which ICG (in 11 cases), or FA (in 2 cases) identified a polypoidal branching network leading to a revised diagnosis of PCV (Yannuzzi et al., 2000).

In addition, PCV may share ICG-angiographic features with CSCR, including choroidal hyperpermeability (Sasahara et al., 2006) and punctate hyperfluorescent spots (Park et al., 2014), which reflects the contribution of choroidal changes in PCV pathogenesis. Increased choroidal thickness in PCV eyes has also been reported in several case series comparing them to healthy eyes (Kim et al., 2011; Rishi et al., 2013) and AMD cases (Jirattanasopa et al., 2012a; Kim et al., 2011; Koizumi et al., 2011; Rishi et al., 2013). In one report, choroidal thickness was lower in PCV than CSCR eyes, although non significantly (Kim et al., 2011).

In addition to clinical and angiographic features differentiating PCV from CSCR, fine tomographic signs related to the more intense exudation are observed in PCV. In a comparative case series based on multimodal imaging and speckle noise-reduced SD-OCT, an enhanced variant of SD-OCT, PCV was more frequently associated with intraretinal cystoid edema, presence of intraretinal lipid deposits, and hemorrhagic PED than CSCR (Ooto et al., 2011). Recently, Baek and colleagues analyzed by SD-OCT the optical density of subretinal fluid (relative to the vitreous, the RPE and the retinal nerve fibers layer), showing that all optical density ratios were higher among patients with PCV compared to those with acute or chronic CSC (Baek and Park, 2015).

The link between CSCR and PCV should be further explored. PCV was found more frequently in Asian patients with a history of CSCR (Toyama et al., 2014). Whether pachychoroid could predispose to either CSCR or PCV depending on associated factors such as genetic background or exogenous factors remains to be determined.

### 2.5.2. CSCR-associated choroidal neovascularization

Choroidal neovascularization (CNV) can complicate CSCR, with reported incidence rates ranging from 2%, in a series of 101 eyes with mean follow-up of 9.8 years (Loo et al., 2002) to 9% in a series of 130 patients, in which 84% of CNV cases occurred in subjects over 50 years of age (Spaide et al., 1996a). Other studies found no association, as for instance a series of 340 eyes with a mean follow-up of 49 months (Mudvari et al., 2007). As occurring in AMD or pathologic myopia, chronic alterations of Bruch membrane and RPE involved in CSCR pathogenesis have been postulated as causative factors for CNV formation. Until recently, in reports where the classification of CSCR-associated CNVs was addressed, they were classified as “Type 2” CNVs (Chan et al., 2003b; Lafaut et al., 1998). The observation of Type 1-CNv in CSCR is more recent and will be detailed in 2.5.3. In CSCR patients treated with laser photocoagulation, CNV may occur as a late complication as high-energy spots can disrupt the RPE (Simon et al., 2001). These cases respond usually very well to a limited number of anti-VEGF injections, as discussed in 2.6.3.1.

### 2.5.3. Type 1 CNV, chronic CSCR and “pachychoroid neovasculopathy”

Although resulting from different pathogenic mechanisms and producing distinct clinical presentations, CSCR and neovascular

AMD both affect the macula and result from pathologic processes at the level of the choroidal vasculature and the RPE. In certain cases, especially middle-aged adults who present exudative processes, the distinction between both entities is complex because of overlapping clinical and imaging features. A form of Type 1 neovascularization related to long-standing CSCR has been recently described in two subgroups of patients (Fung et al., 2012). On one hand, features resembling Type 1 CNV lesions developed over the course of follow-up in 9 patients diagnosed with chronic CSCR. On the other hand, Type 1 neovascularization was detected in 13 patients who presented with associated features closer to chronic CSCR than to AMD. Mean patient age was 61-years old, mean subfoveal choroidal thickness was 354  $\mu\text{m}$  and midphase hyperpermeability was observed in all eyes undergoing ICG angiography. Interestingly, 36% of cases presented polypoidal structures on ICG angiography or SD-OCT.

More recently, the term “Pachychoroid neovasculopathy” has been coined to describe Type 1 CNV overlying focal areas of choroidal thickening on EDI-OCT and choroidal hyperpermeability on ICG angiography, without a history of acute or chronic CSCR. In a detailed account of three cases, all harbored polypoidal-like structures on ICG angiography or SD-OCT (Pang and Freund, 2015). Therefore, long-standing CSCR, Type 1 neovascularization and PCV have been suggested to belong to a spectrum of conditions sharing the “pachychoroid” feature. In this spectrum, pachychoroid neovasculopathy has been postulated as a possible precursor of PCV.

In patients with CNV unresponsive to anti-VEGF and not presenting other signs of AMD, the diagnosis of CSCR should be considered particularly if associated with increased choroidal thickness in both eyes.

### 2.5.4. Cavitory optic disc anomalies

Optic disc pit (Fig. 10A–C) and typical congenital optic disc coloboma are focal excavations located in the optic nerve head virtually creating a communication between the vitreous cavity, the subretinal space and to a variable extent the subarachnoid space. Clinically, they provoke chronic or recurrent serous retinal detachment with variable intraretinal cystoid edema leading in advanced cases to a schisis-like appearance. Although controversial, their pathogenicity probably relies on dynamic fluctuations in the gradient between intraocular and intracranial pressures (Georgalas et al., 2011; Jain and Johnson, 2014). Careful examination of the papillary anatomy should then be performed in patients with chronic SRD or intraretinal edema attributed to CSCR to rule out optic disc cavities anomalies. Among the proposed therapeutic options, laser photocoagulation alone or pars plana vitrectomy with careful juxtapapillary laser photocoagulation and gas tamponade have been attempted to create a permanent peripapillary scar and avoid recurrences (Jain and Johnson, 2014).

### 2.5.5. Circumscribed choroidal hemangioma

Circumscribed choroidal hemangioma (Fig. 9C–F) is a benign tumor of the choroid, characterized by an orange coloration on fundus appearance. It is frequently located in the paramacular area, and presents with serous retinal detachment and focal increased choroidal thickness, and can therefore be misdiagnosed as CSCR. On FAF the lesion can appear iso- or hypofluorescent, with granular hyperfluorescence due to overlying orange pigment (Heimann et al., 2013). FA presents with increasing fluorescence over the sequence that may mimic RPE alterations observed in long-standing CSCR cases. However ICG angiography helps to distinguish both entities since circumscribed choroidal hemangiomas show early hyperfluorescence followed by a classical “wash-out phenomenon” during mid- and late phases (Shields et al., 2001).

**Table 6**  
CSCR related entities and differential diagnosis.

	Acute CSCR	Chronic CSCR	Polypoidal choroidal vasculopathy	CNV complicating CSCR	Pachychoroid neovascularopathy (Type 1 CNV + pachychoroid)	Dome-shaped macula with subfoveal detachment	Optic disc pit	Circumscribed choroidal hemangioma
Gender	M > F	M = F	F > M (Caucasian) M > F (Asian)	M > F	?	F > M	M = F	M > F
Age (y)	30–60	40–80	50–65	>50	55–65	20–85	5–90	5–80
Context	Personality pattern, stress, glucocorticoids	Personality pattern, stress, glucocorticoids	Frequent in Asian men	CSCR history	Misdiagnosed as early AMD, resistance to anti-VEGF	Myopia, fluctuating vision loss	Congenital, sporadic, fluctuating vision loss	Misdiagnosed as melanoma, CSCR etc
Fundus	SRD, grayish leakage site	Pigment clumps, RPE atrophy, subretinal exudates,	Orange nodules, hemorrhage	Possible hemorrhage, lipid exudates	Absence of drusen, reduced fundus tessellation	Posterior staphyloma	Optic disc defect, grayish aspect	Orange-red elevation
SD-OCT	Retina	SRD, elongated photoreceptor outer segments, hyper-R dots	SRD, cysts, lipid deposits	Features of CSCR + non-resolving outer retinal exudative signs, Feature of chronic CSCR + pre-RPE hyper-R material	SRD	SRD	SRD, cysts, retinoschisis	SRD, cysts
	RPE	Focal PED(s), subretinal deposits	Extended/multifocal PED(s), double layer sign	PED with hyper-R heterogenic content, “Double layer” sign	Irregular PED, absence of drusen	RPE elevations, small PED	Unremarkable	RPE thinning
	Choroid	Dilated outer vessels, compressed CC	Dilated outer vessels, compressed CC + Sattler	Focal or diffuse vessel dilatation, polyps at the back of RPE	Dilated outer vessels, compressed inner layers	Thin with relative retrofoveal thickening	Unremarkable	Hypo-R lesion
FAF	Pachy-choroid	Frequent Hypo-FAF (<4 months), hyper-FAF (>4 months), pin points	Possible Gravitational tracks of hypo-FAF	Possible FAF masking by lipids and blood	Possible –	Yes Hyper/hypo-FAF	No Hypo-FAF (RPE atrophy)	Yes Reduced FAF over the tumor, granular hyper-FAF
FA	Early	1–2 leakage points (pin point, ink-blot, smokestack), PED: late hyper-F	Diffuse granular hyper-F areas, PED: late hyper-F	Discrete hyper-F	CSCR features + lacy hyper-F	Discrete hyper-F	Hypo-F (pit)	Lacy hyper-F
	Mid-late	Filling of the SRD	Diffuse window defects (RPE atrophy)	Ill-defined hyper-F (occult leakage)	CSCR features + diffusion (classic CNV)	Ill-defined hyper-F (occult leakage)	Pinpoint leakage	Increasing hyper-F, late leakage
ICG	Early	Arterial and capillary filling delay	Arterial and capillary filling delay, PED: hyper-F	Nodular hyper-F, branching network	CSCR features + variable hyper-F	Nodular hyper-F, branching network	Hypo-F (pit)	Rapid onset hyper-F
	Mid-late	Hyperpermeability, foci of choriocapillaris non-perfusion, punctate hyper-F spots	Hyperpermeability, enlarged vessels, PED: hypo-F	Nodular hyper-F, branching network, punctate hyper-F spots, variable hyperpermeability	CSCR features + variable hyper-F	Hyperpermeability, frequently nodular hyper-F and branching network	Hypo-F (pit)	Hypo-F (“Wash out”), hyper-F rim

M = male; F = female, SD-OCT = spectral-domain optical coherence tomography, ICG = Indocyanine green, FA = fluorescein angiography, FAF = fundus autofluorescence, hyper-R = hyper-reflective, hypo-R = hyporeflexive, hyper-F = hyperfluorescence, hypo-F = hypofluorescence, SRD = serous retinal detachment, CNV = choroidal neovascularization, AMD = age-related macular degeneration, CC = choriocapillaris, RPE = retinal pigment epithelium, PED = Pigment epithelial detachment.

Recent EDI-OCT observations have concluded to an increased caliber of the medium and large choroidal vessels in the tumor, without choriocapillaris compression (Shields et al., 2014). Photodynamic therapy is a safe and effective treatment for circumscribed choroidal hemangioma (Gupta et al., 2004).

#### 2.5.6. Dome-shaped macula

Dome-shaped macula (Fig. 10D) is a forward bulge of the macula protruding within a posterior pole staphyloma in myopic eyes (Gaucher et al., 2008). Among reported complications, a fluctuating serous foveal detachment is observed in approximately 50% of eyes (Caillaux et al., 2013). It is significantly associated with pinpoint leakage on FA, retrofoveal hypofluorescence with punctate hyperfluorescent spots on ICG angiography, small PEDs on SD-OCT and a greater subfoveal choroidal thickness compared to eyes without SRD (Viola et al., 2015). These features are very similar to morphological changes occurring in the choroid of CSCR patients and may obscure the distinction between both entities, especially in eyes with small refractive error. This parallel also suggests that the choroid plays an important role in the pathogenicity of SRDs complicating dome-shaped macula. SRDs may be spontaneously resolving (Tamura et al., 2014), but little has been reported regarding adequate therapy for long-standing cases. A report of two cases indicated that neither intravitreal bevacizumab nor laser photocoagulation alone were efficient, whereas SRD resolution was maintained for two years following half-fluence PDT (Chinsky and Johnson, 2013). On the assumption that mineralocorticoid receptors may be implicated in the choroidal remodeling associated with dome-shaped macula, we have reported two cases of chronic SRD treated with oral spironolactone during 3 and 6 months, with maintained efficacy until 3 and 12 months, respectively (Dirani et al., 2014). More investigations are needed to determine the optimal management of these cases.

In choroidal hemangioma and dome-shaped macula, sclero-choroidal changes may induce mechanical stress to the RPE, inducing either alteration of the tight-junctions or changes in their pumping activity, and leading to subretinal fluid accumulation.

## 2.6. Treatments

Acute CSCR is a self-limited disease, with re-attachment of the neurosensory retina occurring within 3–4 months in the majority of cases (Yannuzzi, 2010). Consequently, observation is the appropriate first-line approach. Without much controversy in acute CSCR, such attitude could be discussed in recurrences or in patients presenting with diffuse epitheliopathy at first presentation. Indeed, long-lasting SRD in recurrent CSCR could increase photoreceptor damage. Functional studies should be conducted to determine the consequences of recurrent and chronic macular detachments.

Accurate recurrence rates are difficult to estimate due to the variability of follow-up durations in the literature. In a series of reports where follow-up varied from 2 to 13 years, recurrences were seen in 15–50% of cases. Recurrent or persistent SRD was identified as a risk factor of visual acuity worse than 20/40 (Loo et al., 2002).

There is no consensus about the most suitable treatment and the optimal timing for intervention in CSCR patients. Classically, treatment can be justified in the following indications: persistent macular SRD for at least 4 months, history of multiple recurrences, history of CSCR in the fellow eye with poor visual outcome, reduced visual acuity, and rapid recovery required (Nicholson et al., 2013). When CSCR patients present with good visual acuity, the potential toxicity of treatments, and particularly their delayed toxicity, should be taken into account in selecting the therapeutic modality.

Physical treatments have been developed to target the RPE

leakage, and the vascular choroidal congestion and hyperpermeability (Chan et al., 2008). Many other medical treatments have been proposed with few evidence-based results.

#### 2.6.1. Exclusion of risk factors

Interruption of identified, often occult glucocorticoid treatment appears beneficial to facilitate the resolution of CSCR episodes (Polak et al., 1995; Sharma et al., 2004; Wakakura et al., 1997; Williamson and Nuki, 1970). Proper management of obstructive sleep apnea could also be discussed. Whether the control of other identified risk factors (described in 2.2) would alter the course of CSCR, especially in chronic cases, has not been reported yet. However, taking into account the psychopathologic personality profile of CSCR patients, and their susceptibility to sight-threat-induced stress, a psychological support associated or not with pharmacotherapy should be discussed.

#### 2.6.2. Physical treatments

**2.6.2.1. Laser photocoagulation.** Green (514 nm) or yellow (580 nm) laser photocoagulation has been attempted to “seal” the RPE leakage points. Besides direct thermal sealing effect on the focal RPE defects, laser is thought to prompt fluid exit (Robertson and Ilstrup, 1983) and favor expansion of surrounding RPE cells (Lim et al., 2011). But laser photocoagulation is not expected to act on choroidal congestion and hyperpermeability (Maruko et al., 2010).

Several studies have compared laser photocoagulation to observation or sham laser treatment (summarized in Table 7). Overall, the studies showed that in acute CSCR with obvious focal leakage on FA, laser photocoagulation hastened the resolution of neurosensory retinal detachment but did not improve the final visual outcome. In the longest available follow-up studies (6–12 years), it did not reduce the rate of recurrences, which is consistent with the absence of effect on causative choroidal changes. Although generally safe, there are few reported adverse effects including paracentral scotoma and iatrogenic CNV, particularly if performed in the juxta foveal area (Ficker et al., 1988; Gilbert et al., 1984; Verma et al., 2004). More recently, subthreshold diode micropulse laser (810 nm) was proposed for the treatment of CSCR (Behnia et al., 2013; Chen et al., 2008; Koss et al., 2012; Lanzetta et al., 2008; Roisman et al., 2013). The higher wavelengths would allow a better choroidal penetration while sparing the inner retina from the laser injury (Brancato et al., 1989). In a prospective study, 30 CSCR cases with a single leak on FA, at least 300  $\mu\text{m}$  away from the fovea, were randomized to receive either argon green laser or subthreshold diode micropulse laser photocoagulation. Subthreshold diode micropulse laser was superior to argon green laser in terms of faster visual recovery and better contrast sensitivity (Verma et al., 2004). Larger studies should confirm these preliminary findings.

To date, laser photocoagulation remains an option in acute CSCR patients with SRD persisting for more than 4 months and a clear leak on FA, located more than 500  $\mu\text{m}$  away from the fovea.

**2.6.2.2. Verteporfin photodynamic therapy (PDT).** Upon light stimulation at 693 nm and in the presence of oxygen, Verteporfin (Visudyne<sup>®</sup>; Novartis, Switzerland) releases free radicals in the choroidal circulation, leading to endothelial vascular damage and vessel occlusion. PDT with verteporfin has been proposed in the treatment of CSCR based on the assumption that it provoked short-term choriocapillaris hypoperfusion and long-term choroidal vascular remodeling, thus reducing choroidal congestion, vascular hyperpermeability, and extravascular leakage (Chan et al., 2003a; Schlötzer-Schrehardt et al., 2002). Among 39 patients treated by PDT, ICG angiography showed resolution of choroidal vascular hyperpermeability and reduction in choroidal extravascular



**Table 7**  
Controlled studies reporting the effect of laser photocoagulation on episode duration, best-corrected visual acuity and rate of recurrence.

Author	Laser type	No. of eyes (treated/control)	Randomization	Shorter episode duration in laser group (P value)	Mean episode duration in laser group (weeks)	Mean episode duration in control group (weeks)	Type of control	Better final VA in laser group (P value)	Decreased recurrence rate in laser group (P value)	Follow-up duration (months)
(Leaver and Williams, 1979)	Argon	67 (NA)	Yes	Yes (P < 0.01)	6	16	Observation	No	NA	6
(Robertson and Ilstrup, 1983)	Argon	12 (7/5)	No	Yes (P = 0.012)	6	15	Laser impact remote from leakage site	No	Yes (P = 0.045)	18
(Gilbert et al., 1984)	Argon	73 (26/47)	No	NA	NA	NA	Observation	No	No	58
(Brancato et al., 1987)	Argon	87 (37/50)	No	NA	8	12	Observation	NA	No	96
(Ficker et al., 1988)	Argon	44 (25/19)	Yes	NA	NA	NA	Observation	No	No	108
(Borumcek et al., 1997)	Argon and yellow	45 (29/16)	No	Yes (P > 0.0001)	NA <sup>a</sup>	NA <sup>a</sup>	Observation	NA	Yes (P = 0.0003)	58

<sup>a</sup> Data not provided (survival analysis).

leakage at 3 months in 94% of cases, compared to 15% in a group of 19 control subjects receiving saline instead of verteporfin (Chan et al., 2008). Following PDT, a reduction in choroidal thickness of 9–19% at 1 month and 12–21% at 3 months has also been reported (Table 4).

For CNV, verteporfin is approved at a dose of 6 mg/m<sup>2</sup> with a laser fluence of 50 J/cm<sup>2</sup>. Long-term complications of PDT include choriocapillaris non-perfusion (44%), secondary CNV (5%) (Reibaldi et al., 2010), RPE atrophy (4%) and subsequent visual loss (1.5%) (Lim et al., 2014). Such complication rates are not acceptable for CSCR patients who still maintain good visual acuity levels. Moreover, severe complications (such as abrupt and profound visual loss) were reported in CSCR patients after PDT treatment according to AMD guidelines parameters, leading to reconsider PDT parameters for CSCR. Lower-fluence PDT (25 J/cm<sup>2</sup>) showed that 91% of eyes had resolution of SRD at 12 months and did not cause choriocapillaris non-perfusion (Reibaldi et al., 2010). Half-dose PDT (3 mg/m<sup>2</sup>) showed similar efficacy at 12 months (Chan et al., 2008), without reported adverse events (Senturk et al., 2011), although it has not been compared to full-dose PDT. Interestingly, 1/3-dose PDT (2 mg/m<sup>2</sup>) was less effective than half-dose PDT in terms of sub-retinal fluid resolution (Uetani et al., 2012).

A recent meta-analysis (Ma et al., 2014) of nine studies (Bae et al., 2011; Chan et al., 2008; Lee et al., 2011; Lim et al., 2011; Maruko et al., 2011b; Reibaldi et al., 2010; Semeraro et al., 2012; Shin et al., 2011; Wu et al., 2011) including 63 acute CSCR and 256 chronic CSCR, defined by persistent SRD > 3 month, has reported that:

- Half-dose PDT was superior to placebo in terms of BCVA improvement, central macular thickness reduction and SRD resolution at 12 month.
- Half-dose PDT was superior to laser photocoagulation in terms of SRD resolution at 1 month, but no significant difference was observed in BCVA and central macular thickness.
- Half-fluence PDT and standard-fluence PDT were superior to intravitreal anti-VEGF injections in terms of SRD resolution and central macular thickness diminution at 3 month, but no difference was observed in BCVA.
- Half-fluence PDT was as effective as standard-fluence PDT and could significantly decrease the regional choroidal non-perfusion related to the hypoxic damages caused by PDT.

Whether half-dose PDT or half-fluence PDT is superior for the

treatment of CSCR remains unclear. In a retrospective review of 56 patients (Nicoló et al., 2014) with chronic CSCR treated by half-dose or half-fluence PDT, half-dose PDT induced a more rapid reabsorption of subretinal fluid with respect to half-fluence PDT (83.9% versus 100% of eyes at 12 months), with a more lasting effect (15 versus 5 recurrences). No eyes developed RPE atrophy in any group. However, similar rates of subretinal fluid reabsorption, gain of BCVA, and central macular thickness decrease were observed with both modalities of treatment in another retrospective study including 64 eyes (Alkin et al., 2014).

Remarkably, there are no long-term studies (>12 months) recording visual function, rate of recurrences, benefit of re-treatments, and rate of adverse events after single or multiple PDT treatments. Since long-term data following PDT for other retinal disorders showed that delayed chorioretinal atrophy and permanent vision loss can be observed, long-term follow-up is required to assess the safety of PDT in the CSCR patients, who belong to younger age groups.

### 2.6.3. Medical treatments

**2.6.3.1. Anti-VEGF agents.** Although CSCR is not associated with increased VEGF ocular levels (Lim et al., 2010a; Shin and Lim, 2011), anti-VEGF therapy was proposed to reduce the choroidal hyper-permeability (Chung et al., 2013). A limited number of interventional case series reported beneficial effects of bevacizumab in terms of visual acuity improvement and subretinal fluid reduction without significant complications (Arevalo and Espinoza, 2011; Artunay et al., 2010; Lim and Kim, 2011; Schaal et al., 2009). However, the only randomized study comparing ranibizumab to observation showed no difference in terms of visual acuity, central retinal thickness or duration of SRD between both groups (Lim et al., 2010b). More recently, aflibercept was used in a pilot study of 12 patients with persistent fluid over 6 months, showing a moderate effect on fluid and macular thickness reduction (Pitcher et al., 2015).

A recent meta-analysis of 4 studies (Artunay et al., 2010; Aydin, 2013; Koss et al., 2012; Lim et al., 2010b) including acute and chronic CSCR showed that neither visual acuity nor central macular thickness were significantly improved 6 months after intravitreal bevacizumab, compared to observation, PDT or laser photocoagulation (Chung et al., 2013).

Finally, a few case series indicate a beneficial effect of bevacizumab (Chan et al., 2007), ranibizumab (Konstantinidis et al., 2010) and aflibercept (Broadhead and Chang, 2014) on CNV

complicating CSCR.

To date, the cost/benefit of anti-VEGF is not demonstrated for CSCR, except for treating clearly identified CNV.

**2.6.3.2. Oral treatments.** Proper evaluation of a treatment effect requires a double-blinded, randomized, comparative design using an adapted placebo. These general concepts are critical for clinical trials with CSCR patients, given the fluctuating and self-resolutive nature of CSCR and the particular psychological profile of these subjects (described in 2.2.6), which may amplify the “placebo effect”.

Several oral medications have been proposed for the treatment of CSCR based on the putative inhibition of different pathogenic pathways. Drugs belonging to the following therapeutic classes have been evaluated: carbonic anhydrase inhibitors

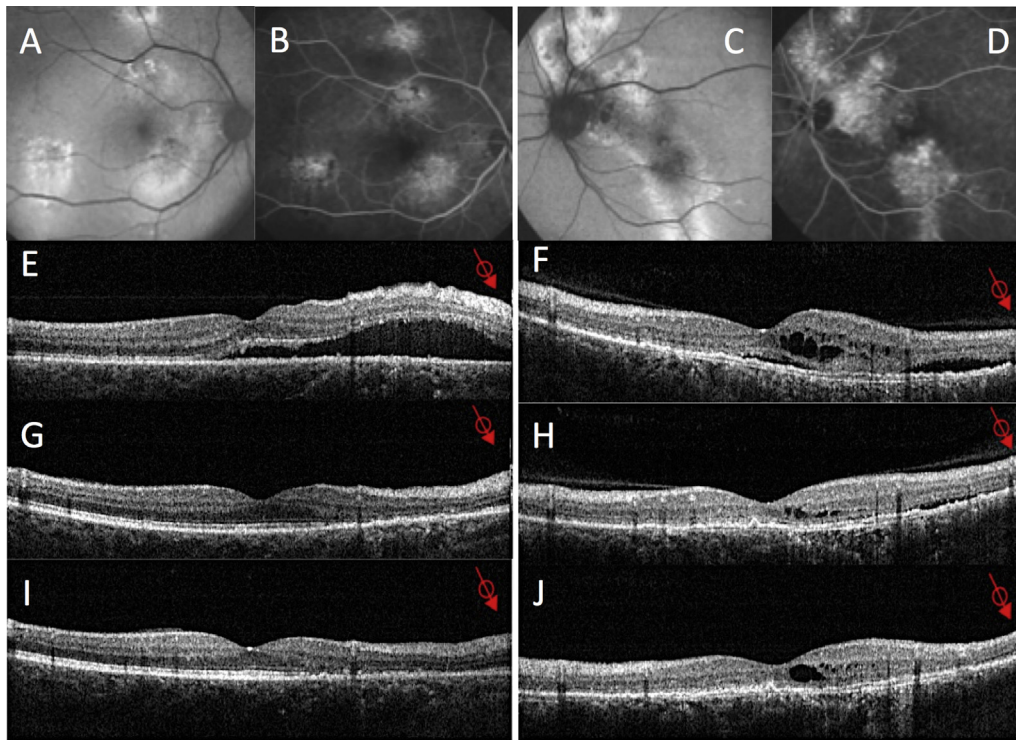
(acetazolamide), beta-blockers (nadolol, propranolol), antibiotics (amoxicillin, metronidazole, clarithromycin) and proton pump inhibitors (omeprazole) for the treatment of *Helicobacter pylori*, imidazoles (ketoconazole), glucocorticoid-receptor antagonists (mifepristone), anti-platelets (aspirin), antimetabolites (methotrexate), 5 $\alpha$ -reductase inhibitors (finasteride), diarylheptanoids (curcumin), with negative or poor evidence of benefit, as summarized in a recent comprehensive review on CSCR treatments (Nicholson et al., 2013).

The existing comparative studies evaluating the effect of an oral medication on the course of CSCR, most of them prospective, are summarized in Table 8. To date, methotrexate (Kurup et al., 2012), finasteride (Forooghian et al., 2011) and curcumin (Mazzolani and Togni, 2013) have not been evaluated in comparative studies. Despite relatively encouraging evidence from pilot studies, further comparative evaluations are then needed.

**Table 8**  
Studies evaluating oral treatments for central serous chorioretinopathy with a control group.

Oral drug (dose)	Class, suggested mechanism	Study design, control	No. of eyes (treated/control)	Follow-up duration (months)	Favorable effect on SRD	SRD evaluation	Better final BCVA in treated group	Decreased recurrence rate in treated group	Comment	Authors
Acetazolamide (500 mg tid, bid, qd by 2 weeks periods)	Carbonic anhydrase inhibitor: - Acidification of the subretinal space - Improvement of RPE polarization and pump function - Anti-inflammatory effect	Prospective non-randomized, vs observation	22 (15/7)	24	Yes	Episode duration (3.3 vs 7.7; p < 0.0001)	No	No	High rate of side effects (Paresthesias, dyspepsia)	(Pikkel et al., 2002)
Nadolol (40 mg qd)	Beta-blocker: inhibition of sympathetic activity	Randomized, double-masked, vs placebo	8 (4/4)	4	No	SRD resolution rate	NA	No		(Browning, 1993)
- Amoxicillin (500 mg tid 2 weeks) - Metronidazole (500 mg tid 2 weeks) - Omeprazole (NA, 6 weeks)	Antibiotics + proton pump inhibitor: treatment of <i>Helicobacter pylori</i> infection	Randomized, vs observation	50 (25/25)	4	Yes	Episode duration (9.3 vs 11.6; p = 0.04)	No	NA	Patients with positive urease breath test at baseline	(Rahbani-Nobar et al., 2011)
- Amoxicillin (1 g bid 2 weeks) - Clarithromycin (500 mg bid 2 weeks) - Omeprazole (20 mg bid, 2 weeks)	Antibiotics + proton pump inhibitor: treatment of <i>Helicobacter pylori</i> infection	Randomized, vs observation	53 (27/26)	3	No	SRD resolution rate	No	NA	Patients with positive urease breath test at baseline	(Dang et al., 2013)
Ketoconazole (200 mg qd, 4 weeks)	Antifungal, P450 Cytochrome and 11 $\beta$ -hydroxylase inhibitor: endogeneous cortisol synthesis inhibition	Retrospective, versus observation	30 (15/15)	1	No	SRD height	No	NA	Adverse events: nausea (1), erectile dysfunction (1)	(Golshahi et al., 2010)
Mifepristone (200 mg qd, 12 weeks)	Glucocorticoid-receptor antagonist and anti-progesterone	Randomized, double-masked, vs placebo	8 (4/4)	3	NA	–	NA	NA	Results non interpretable because 4 patients exited study before termination	(Nielsen and Jampol, 2011)
Aspirin (100 mg qd, 1 months; then every 2 days, 6 months)	Inhibitor of platelet aggregation: diminution of plasminogen activator inhibitor 1 levels	Prospective non-randomized, vs observation	208 (113/95)	18	NA	–	Yes	No	Tendency in limitation of recurrences but no p-value provided	(Caccavale et al., 2010)

SRD = subretinal detachment, BCVA = best-corrected visual acuity.



**Fig. 18.** Bilateral chronic central serous chorioretinopathy treated by mineralocorticoid-receptor antagonist. Fifty-three year-old male patient with bilateral chronic CSCR, as evidenced by RPE changes on fundus autofluorescence (A and C) and fluorescein angiography (B and D). SD-OCT showed a bilateral subretinal detachment (E, F), more pronounced in the right eye (E) and intraretinal cystoid edema in the left eye consistent with the chronic form of CSCR (F). The patient was treated by oral eplerenone (50 mg/day for 1 month, then 25 mg/day) and was maintained under the lowest possible dose (25 mg/day). A progressive retinal reapplication was observed in both eyes, with diminution of intraretinal edema in the left eye, maintained 6 months (G and H) and 18 months after initiation of treatment (I and J).

### 3. CSCR: the mineralocorticoid pathway hypothesis

#### 3.1. The aldosterone/mineralocorticoid receptor pathway and rationale for potential involvement in CSCR pathogenesis

CSCR is a one of the rare ophthalmic diseases that is aggravated or even triggered by exogenous glucocorticoids (see 2.2.4). Endogenous cortisol metabolism disturbances have also been associated with CSCR (see 2.2.5) suggesting that glucocorticoids favor the accumulation of fluid under the retina in this specific condition, instead of acting on its absorption as observed in macular edema of other origins (Sarao et al., 2014).

This paradox is not unique. In internal medicine, glucocorticoids are used to reduce edema of numerous origins such as inflammation, infection, allergy, trauma and neurotoxicity. However, their use is also associated with adverse side effects including water and sodium retention. Indeed, the primary adrenal cortical steroid hormones, aldosterone and cortisol, act through binding to the structurally similar mineralocorticoid (MR) and glucocorticoid (GR) receptors.

The MR and the  $11\beta$ -hydroxysteroid dehydrogenase type 2 ( $11\beta$ HSD2) pre-receptor enzyme are expressed in the kidney, known as the classical mineralocorticoid-sensitive organ. Aldosterone regulates sodium and fluid reabsorption in the distal part of the renal tubule, modulating body fluid volume and blood pressure. In particular, through MR activation, the sodium channel expression and distribution is regulated. The endogenous cortisol has similar affinity for GR and MR but synthetic or semi-synthetic therapeutic glucocorticoids have been chemically modified to increase their GR affinity and reduce their MR affinity. Therapeutic glucocorticoids agents can also activate the MR in the kidney, which

results in water retention in the intravascular compartment and increased blood pressure. Combining these facts, the primary hypothesis was that glucocorticoids could also potentially regulate ion and water channels in the eye through MR activation, resulting in the paradoxical pro-edematous effects of glucocorticoids in CSCR.

Beside the kidney, other organs, tissues and cells express MR and have been recognized as non-classical mineralocorticoid-sensitive targets: heart, blood vessels, brain, adipose tissue, skin and macrophages (Farman et al., 2010; Nguyen Dinh Cat and Jaisser, 2012). GR and MR are thus co-expressed in many cell types, where they interact at molecular and functional levels, synergistically or competitively. As a consequence, the GR/MR balance is crucial to control hydro-electrolytic regulation. In most tissues, under physiologic conditions glucocorticoids occupy the MR at basal levels and the over-activation of the MR pathway is pathogenic (Gomez-Sanchez and Gomez-Sanchez, 2014).

Studies using transgenic mice demonstrated that activation of the MR pathway per se induced hypertension and increased contractile response to vasoconstrictors when the MR was over-expressed in vessels, and arrhythmia when the MR was over-expressed in the heart (Brown, 2013; Young and Rickard, 2015). Furthermore, low doses of aldosterone have been shown to exert direct effects on the vascular system by inducing oxidative stress, inflammation, hypertrophic remodeling, fibrosis and endothelial dysfunction, demonstrating that activation of the MR pathway by the ligand or the receptor activate different pathogenic mechanisms (Briet and Schiffrin, 2013; Feldman and Gros, 2013; McCurley and Jaffe, 2012). Following injury of vessels, MR activation has been shown to promote smooth muscle cells fibrosis via the activation of the Placental Growth Factor (PGF)/VEGF Receptor 1 (VEGFR1)

pathway. Furthermore, treatment with MR antagonists prevents pathogenic vascular remodeling, linking the Placental Growth Factor (PGF) and MR in this process (McGraw et al., 2013). MR antagonists also reduced experimental cerebral aneurysms through the reduction of NOX4, Rac1, monocyte chemoattractant protein 1 (MCP-1), and matrix metalloproteinase 9 expression (Tada et al., 2009). Vascular dilation can also be controlled by the MR pathway through nitric oxide (Heylen et al., 2009).

Increasing evidence suggests that blocking MR activation can have therapeutic value for endothelial dysfunction, atherosclerosis, hypertension, heart failure and chronic kidney disease. In a model of retinopathy due to prematurity, the MR/aldosterone pathway was shown to directly stimulate retinal neo-angiogenesis and to modulate retinal inflammation, with leukostasis and MCP-1 expression. In this model the antagonism of MR had anti-angiogenic effects (Wilkinson-Berka et al., 2009), suggesting that choroidal vasculopathy could result, at least in part, from MR activation.

Gender differences in the outcome of post-myocardial infarction remodeling, prevalence of hypertension and sudden death of cardiac origin raised the hypothesis that vascular and heart tissues may respond differently to the aldosterone/MR pathway activation depending on the hormonal status. Indeed, in endothelial cells MR regulates the expression of the pro-inflammatory intercellular adhesion molecule-1 (ICAM-1), and this was shown to be modulated by estrogens through interaction of estrogen receptors and MR. This has been proposed as a possible mechanism protecting premenopausal women from cardiovascular disease (Barrett Mueller et al., 2014; Mihailidou and Ashton, 2014).

In the brain, MR participates in the processing of stressful information, indicating that both genomic and non-genomic MR pathways play a role in stress resilience (Ter Heegde et al., 2015). The brain MR/GR balance may also contribute to the hypothalamic-pituitary-adrenal axis deregulation observed in depression (Jurueña et al., 2015).

MR and 11 $\beta$ HSD2 are expressed in the neurosensory retina, the RPE and the choroid, as observed in rats, monkeys and humans (Fig. 11), placing the retina into the category of non-classical mineralocorticoid-sensitive organs (Golestaneh et al., 2002; Wilkinson-Berka et al., 2009; Zhao et al., 2010).

The exact mechanisms by which glucocorticoids exert their anti-edematous effects on the retina have been partially elucidated. But their role when edema has not originated from inflammatory processes has not been explored sufficiently. Apart from the recognized effects of glucocorticoids on junction proteins and on the expression of several pro-inflammatory cytokines via NF- $\kappa$ B-dependent regulation (Chinenov et al., 2013; Salvador et al., 2014), glucocorticoids also act on ion and water channels expression and distribution in retinal glial Müller cells (Zhao et al., 2011). Moreover, commonly used glucocorticoids (i.e. triamcinolone acetonide and dexamethasone sodium diphosphate) injected at different doses in normal or inflamed rat eyes regulate differently the expression and cellular distribution of Kir4.1 (Inwardly rectifying K<sup>+</sup> channel 4.1) and AQP4 (Aquaporin 4), two channels expressed in retinal glial Müller cells and known to contribute to retinal edema. Similar regulations were observed on human Müller cells in vitro (Zhao et al., 2011). The differential effects of glucocorticoids according to the drug type and dose, is likely related to the different GR/MR affinity profile of the different agents.

### 3.2. The different MR antagonists

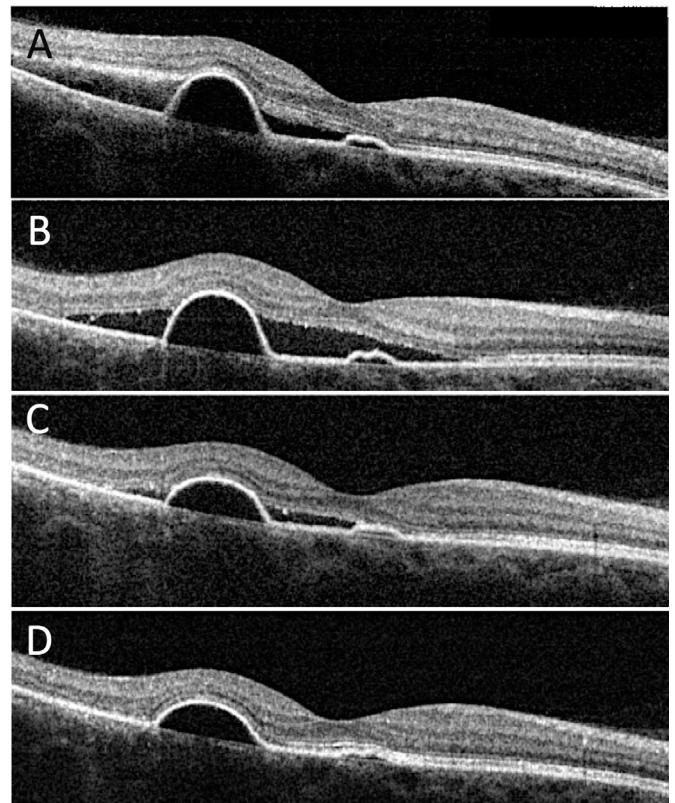
The MR has two natural ligands, aldosterone and cortisol (or corticosterone, its equivalent in rodents) that bind to the MR with the same affinity. Blood cortisol levels are much higher than

aldosterone. In tissues where the 11 $\beta$ HSD2 is expressed, MR is protected from being occupied by glucocorticoids, via the action of 11 $\beta$ HSD2, which metabolizes cortisol into cortisone, that has a much lower affinity for the MR. In most of non-epithelial MR targets, 11 $\beta$ HSD2 is not expressed and thus glucocorticoids occupy the MR (Fuller et al., 2012; Odermatt and Atanasov, 2009).

The first steroidal competitive MR antagonist drug was spironolactone, approved for the treatment of hypertension 55 years ago. It is a potent but non-specific MR antagonist, as it also interacts with progesterone receptors, leading to dose-dependent hormonal side-effects such as gynecomastia, erectile dysfunction, a possible decrease in libido, and menstrual irregularities (Funder, 2013). Spironolactone is a prodrug, converted by the liver into an array of active metabolites (including canrenone) whose half-life is inferior to 7 h (Gardiner et al., 1989).

Eplerenone, designed to reduce the hormonal effects of spironolactone, was approved by the Food and Drug Administration, in 2002. Although it antagonizes the MR more selectively than spironolactone, it has a 40-fold lower affinity for the MR and is therefore a less potent MR antagonist than spironolactone. Eplerenone has no active metabolites and its plasma half-life is 3 h (Cook et al., 2003).

Regarding their action on electrolytes balance, hyperkalemia is a potential adverse consequence of both spironolactone and eplerenone therapy, but is clinically relevant only in patients with



**Fig. 19.** Chronic central serous chorioretinopathy treated by mineralocorticoid-receptor antagonist. Chronic CSCR in the right eye of a fifty-six year old male patient with a dome-shaped pigment epithelial detachment (PED), an adjacent smaller flat PED, and a subretinal detachment (A). Four months after initial examination, the subretinal detachment had slightly increased (B). The patient was treated by oral eplerenone (50 mg/day for 1 month, then 25 mg/day) and was maintained under the lowest possible dose (25 mg/day). Two months later, the dome-shaped PED had flattened, and the amount of subretinal fluid had decreased (C). Six months after treatment initiation, both the dome-shaped and the smaller PEDs remained flatter than at baseline and there was complete resolution of subretinal fluid (D).

impaired renal function. Plasma potassium concentrations should be monitored at baseline and periodically according to the drug manufacturer's instructions.

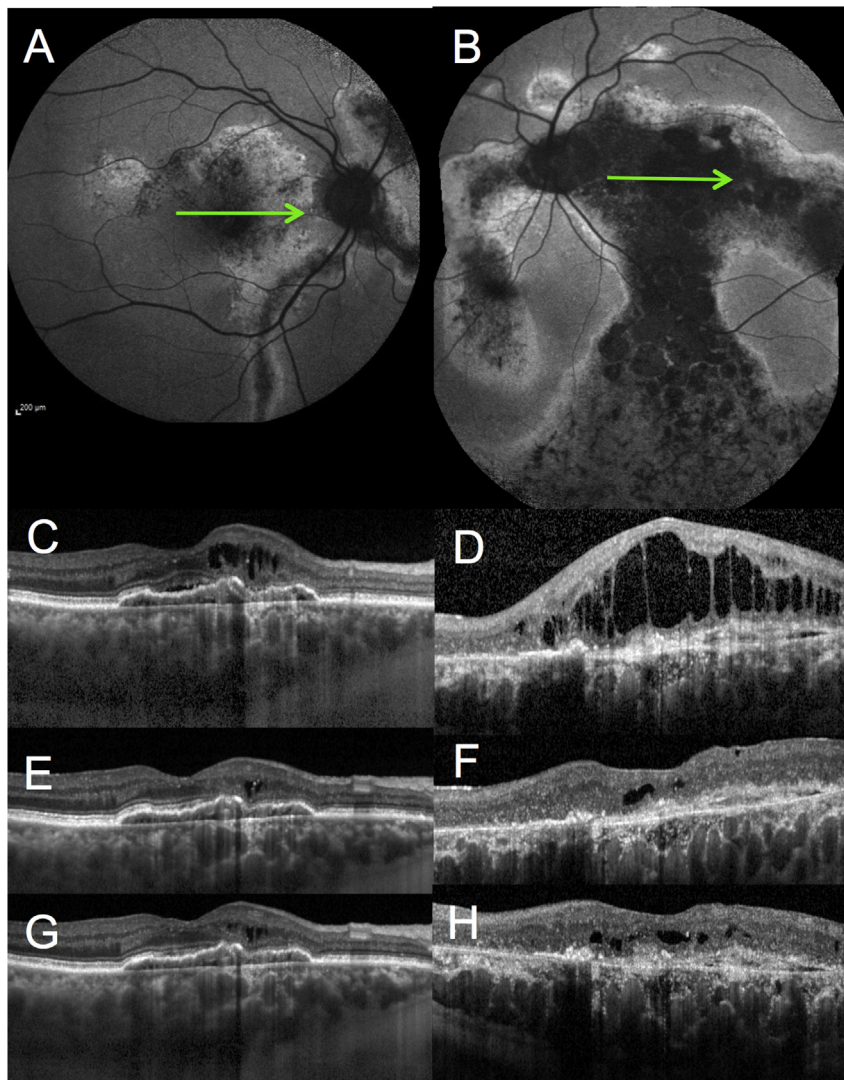
Since the publication of groundbreaking clinical studies showing that spironolactone and eplerenone reduced the morbidity and mortality in patients with heart failure (Funder, 2005; Pitt et al., 2003, 1999), extensive research has been conducted to discover other classes of MR antagonists devoid of renal effects. Recently, the new non-steroidal MR antagonist BAY 94-8862 showed at least an equivalent efficacy to spironolactone in decreasing biomarkers of hemodynamic stress, and was associated with lower incidences of hyperkalemia and renal function worsening (Bauersachs, 2013).

The ocular bioavailability of spironolactone and eplerenone after systemic administration has not been studied but spironolactone induces the expression of the P-glycoprotein, a drug efflux protein that regulates the blood–brain barrier, and is one of its ligands (Ghanem et al., 2006).

### 3.3. Hypothesis: links between CSCR characteristics and MR/aldosterone pathway pathogenesis

The majority of CSCR cases occur in men and post-menopausal women. CSCR is associated with an increased risk of coronary events (Chen et al., 2014) and hypertension (Haimovici et al., 2004). These patients are also at higher risk of personality disorders associated with stress and anxiety susceptibility (Carlesimo et al., 2014; Piskunowicz et al., 2014) (Fig. 12).

Evidences also converge towards the recognition that CSCR pathogenesis involves the choroidal vasculature and its vasomotor control (Guyer et al., 1994; Tittl et al., 2005). To date, the results obtained by our research group indicate that MR pathway activation is involved in the development of CSCR, be it spontaneous, or triggered by endo- or exogenous steroids. We speculate that MR over- or inappropriate activation due to genetic, epigenetic or environmental factors, could induce in susceptible individuals a higher risk for hypertension, coronary events, psychological



**Fig. 20.** Advanced bilateral chronic central serous chorioretinopathy treated by mineralocorticoid-receptor antagonist. Seventy-seven year-old man with bilateral oblong descending hypo-autofluorescent tracks (A and B) indicating a severe chronic CSCR with diffuse decompensation of the retinal pigment epithelium, formerly referred to as "Diffuse retinal pigment epitheliopathy". Enhanced depth-imaging OCT revealed intraretinal cystoid edema and shallow pigment epithelial detachment with hyper-reflective content on the right eye (C), and severe cystoid macular degeneration with RPE hyperplasia and atrophy in the left eye (D). Three months after initiation of oral eplerenone therapy (50 mg/day during 1 month, then 25 mg/day), a major decrease in intraretinal cystoid edema was observed, with a limited effect on the pigment epithelial detachment (E and F). The treatment was continued, and 12 months after initiation the favorable morphological effect was still observed (G and H).

vulnerability to stress and CSCR, especially upon MR stimulation by glucocorticoids.

### 3.4. Scientific evidences

#### 3.4.1. Preclinical studies

Acute activation of the MR pathway in rat eyes has been previously simulated using intraocular injections of aldosterone or high-dose corticosterone (the endogenous glucocorticoid hormone in rodents). Intravitreal injections of aldosterone enhanced the expression of the Na<sup>+</sup> channel ENaC- $\alpha$  (Epithelial Na<sup>+</sup> channel- $\alpha$ ), the K<sup>+</sup> channel Kir4.1, as well as the water channel AQP4. It promoted additional localization of Kir4.1 and AQP4 toward the outer limiting membrane, contributing to the accumulation of fluid in the outer retina (Fig. 12). Intravitreal aldosterone also induced swelling of retinal glial Müller cells (Fig. 13A and B). Aldosterone-induced MR-dependent Kir4.1 and AQP4 regulation was also observed on human Müller glial cell lines (Zhao et al., 2010). At choroidal level, intravitreal administration of aldosterone provoked vasodilation and leakage of choroidal vessels with elongation of retinal pigment epithelial cells microvilli (Fig. 13A–E), increased choroidal thickness and accumulation of subretinal fluid, mimicking the CSCR phenotype. The spectrum of genomic and non-genomic regulatory mechanisms underlying these reactions has not been fully described. To date, aldosterone has been shown to regulate the endothelium-derived hyperpolarizing factor (EDHF) through the up-regulation of the small-conductance Ca<sup>2+</sup>-activated K<sup>+</sup> channel 2.3 (K(Ca)2.3), expressed in choroidal endothelial cells but not in the retinal vessel endothelium (Zhao et al., 2012) (Fig. 14).

A conditional double transgenic mouse model in which inducible MR over-expression is restricted to the endothelium (DT-veCadhMR) was generated. It presented a mild hypertension with no basal endothelial dysfunction, but an enhanced concentration-dependent arterial contraction in response to vasoconstrictors such as phenylephrine (Nguyen Dinh Cat et al., 2010). Moreover, in these mice, choroidal thickness was spontaneously increased and choroidal vessels were dilated, associated with focal disruption of RPE tight junctions and RPE detachments (Fig. 15) (unpublished results from N. Farman and F. Jaisser). Interestingly, CSCR is also associated with the use of sympathomimetic agents, as detailed in 2.2.8 (Michael et al., 2003; Pierce and Lane, 2009).

In conclusion, preclinical studies have evidenced that MR over-activation via either overexpression of the receptor in the vessels, or acute administration of its ligands (aldosterone and corticosterone) produced choroidal and RPE changes, and SRD.

#### 3.4.2. Preliminary clinical results

Based on these preclinical results, MR antagonists were proposed as a treatment for CSCR patients with persistent subretinal fluid.

Two interventional, uncontrolled, prospective case series were conducted testing either eplerenone (25 mg daily for 1 week, then 50 mg for 1–3 months) in 13 patients, or spironolactone (50 mg daily for up to 3 months) in 18 patients. Prior to enrollment all subjects had been observed to have subretinal fluid for at least 3 months. In both studies a significant reduction in foveal subretinal fluid compared to baseline levels was observed three months after initiation of treatment, from 155  $\mu$ m to 36  $\mu$ m ( $p < 0.01$ ) and from 219  $\mu$ m to 100  $\mu$ m ( $p < 0.01$ ), respectively (Bousquet et al., 2013; Herold et al., 2014). In both studies this anatomical recovery was associated with an increase in LogMAR visual acuity, from 0.52 to 0.27 ( $p < 0.01$ ) and from 0.32 to 0.22 ( $p = 0.04$ ), respectively. At 3 months, a total resolution of subretinal fluid was observed in 67% of patients treated with eplerenone (Bousquet et al., 2013).

Retrospectively, we reviewed the medical records of 46 eyes

from 36 patients (31 male, 5 women, mean age 53.1 years) with non-resolving CSCR after 4 months follow-up (reduced to 2 months in case of a recurrent episode), treated by oral eplerenone or spironolactone (25–50 mg/day). After 3 months of treatment, foveal subretinal fluid decreased from 97  $\mu$ m to 42  $\mu$ m ( $p < 0.001$ ), central macular thickness decreased from 334  $\mu$ m to 279  $\mu$ m ( $p < 0.001$ ) and choroidal thickness decreased from 482  $\mu$ m to 456  $\mu$ m ( $p < 0.001$ ) compared to baseline levels (unpublished data) (Figs. 16 and 17). These encouraging results have been reproduced in a double-blinded randomized clinical trial examining the treatment effect of spironolactone versus placebo (Bousquet et al., n.d.).

In light of these results, the role of MR antagonists in the treatment of CSCR will need to be better defined, in terms of disease stage, persistence of subretinal fluid or the combination with alternative therapeutic approaches such as PDT. To date, various durations of treatment by MR antagonists have been evaluated in acute cases with persistent subretinal fluid, and in chronic cases. In real-life conditions selected chronic patients are being treated under long-term, low-dose MR antagonist therapy as illustrated in Fig. 18–20.

## 4. Conclusions and future directions

Improved and innovative technologies allowing better imaging of the choroid and choroidal vasculature have and will continue to advance our understanding of CSCR pathophysiology. Consequently, the spectrum of disease phenotypes related to CSCR continues to expand with important implications in the genetic approach of CSCR and in the design of therapeutic interventional studies. Whilst several treatment options are available, randomized placebo controlled studies are required to guide optimized treatment schemes depending on phenotypes. Results from fundamental research studies prompted the hypothesis that the mineralocorticoid pathway could be involved in CSCR. In this review, we have aimed to give an overview of this hypothesis, bridging the ocular expression of this disease with other consequences of inappropriate MR pathway activation manifesting in CSCR patients. These observations indicate that MR antagonism is a potential minimally invasive therapy for CSCR as shown by the strong treatment effect in the first clinical trials of oral MR antagonists. But their exact place in the therapeutic arsenal remains to be determined. The exact dose and duration of treatment depending on the clinical forms of the disease should also be evaluated. Finally, the optimal route of administration must be developed. Further studies aiming at identifying downstream pathways and regulatory molecular targets in the choroid and the RPE are currently ongoing.

### Authors contribution

A. Daruich (25%) and A. Matet (25%): literature review, manuscript redaction, analysis of the retrospective clinical and imaging data.

A. Dirani (10%): literature review, redaction, imaging analysis.

E. Bousquet (5%): redaction.

M Zhao (5%): pre clinical results and images.

N. Farman (2.5%) and F. Jaisser (2.5%): have provided the transgenic animals and helped for manuscript edition.

F. Behar-Cohen (25%): paper coordination, redaction and edition, selection and description of images, literature review.

### Acknowledgments

The retrospective analysis of CSCR patients presented in this work was performed in accordance with the tenets of the Declaration of Helsinki and was approved by the Ethics Committee of the

Swiss Federal Department of Health (Decisions N° CER-VD 19/15 and N° CER-VD 20/15).

This work was supported by the Fondation VISIO, the Agence Nationale de la Recherche (“Mineraloret” Grant), the Swiss National Fund and the European Cooperation in Science and Technology (“COST-Admire” Grant).

We thank Aude Ambresin and Irmela Mantel for clinical collaboration.

## References

- Agarwal, A., 2012. Gass's Atlas of Macular Diseases, fifth ed. Elsevier.
- Ahlers, C., Geitzenauer, W., Stock, G., Golbaz, I., Schmidt-Erfurth, U., Prünke, C., 2009. Alterations of intraretinal layers in acute central serous chorioretinopathy. *Acta Ophthalmol.* 87, 511–516.
- Ahnouf-Zabsonre, A., Quaranta, M., Mauguet-Faÿsse, M., 2004. Prevalence of *Helicobacter pylori* in central serous chorioretinopathy and diffuse retinal epitheliopathy: a complementary study. *J. Fr. Ophthalmol.* 27, 1129–1133.
- Aliferis, K., Petropoulos, I.K., Farpour, B., Matter, M.A., Safran, A.B., 2012. Should central serous chorioretinopathy be added to the list of ocular side effects of phosphodiesterase 5 inhibitors? *Ophthalmologica* 227, 85–89.
- Alkin, Z., Ozkaya, A., Agca, A., Yazici, A.T., Demirok, A., 2014. Early visual and morphologic changes after half-fluence photodynamic therapy in chronic central serous chorioretinopathy. *J. Ocul. Pharmacol. Ther.* 30, 359–365.
- Amalric, P., Gourinat, P., Rebière, P., 1971. Is central serous choroiditis sometimes hereditary? *Bull. Soc. Ophthalmol. Fr.* 71, 163–168.
- Arevalo, J.F., Espinoza, J.V., 2011. Single-session combined photodynamic therapy with verteporfin and intravitreal anti-vascular endothelial growth factor therapy for chronic central serous chorioretinopathy: a pilot study at 12-month follow-up. *Graefes Arch. Clin. Exp. Ophthalmol.* 249, 1159–1166.
- Artunay, O., Yuzbasioglu, E., Rasier, R., Sengul, A., Bahcecioglu, H., 2010. Intravitreal bevacizumab in treatment of idiopathic persistent central serous chorioretinopathy: a prospective, controlled clinical study. *Curr. Eye Res.* 35, 91–98.
- Ayata, A., Tatlipinar, S., Kar, T., Unal, M., Ersanli, D., Bilge, A.H., 2009. Near-infrared and short-wavelength autofluorescence imaging in central serous chorioretinopathy. *Br. J. Ophthalmol.* 93, 79–82.
- Aydin, E., 2013. The efficacy of intravitreal bevacizumab for acute central serous chorioretinopathy. *J. Ocul. Pharmacol. Ther.* 29, 10–13.
- Baek, J., Park, Y.-H., 2015. Optical density ratio in the subretinal fluid: differentiating chronic central serous chorioretinopathy and polypoidal choroidal vasculopathy. *Am. J. Ophthalmol.* 159, 386–392.
- Bae, S.H., Heo, J.W., Kim, C., Kim, T.W., Lee, J.Y., Song, S.J., Park, T.K., Moon, S.W., Chung, H., 2011. A randomized pilot study of low-fluence photodynamic therapy versus intravitreal ranibizumab for chronic central serous chorioretinopathy. *Am. J. Ophthalmol.* 152, 784.e2–792.e2.
- Bandello, F., Incurvaia, C., Rosa, N., Parmeggiani, F., Costagliola, C., Sebastiani, A., 2002. Bilateral central serous chorioretinopathy in a patient treated with systemic corticosteroids for non-Hodgkin lymphoma. *Eur. J. Ophthalmol.* 12, 123–126.
- Baran, N.V., Gürlü, V.P., Esgin, H., 2005. Long-term macular function in eyes with central serous chorioretinopathy. *Clin. Exp. Ophthalmol.* 33, 369–372.
- Barrett Mueller, K., Lu, Q., Mohammad, N.N., Luu, V., McCurley, A., Williams, G.H., Adler, G.K., Karas, R.H., Jaffe, I.Z., 2014. Estrogen receptor inhibits mineralocorticoid receptor transcriptional regulatory function. *Endocrinology* 155, 4461–4472.
- Bauersachs, J., 2013. The ARTS of third-generation mineralocorticoid receptor antagonists: achieving cardiovascular benefit with minimized renal side effects? *Eur. Heart J.* 34, 2426–2428.
- Baumal, C.R., Martidis, A., Truong, S.N., 2004. Central serous chorioretinopathy associated with periocular corticosteroid injection treatment for HLA-B27-associated iritis. *Arch. Ophthalmol.* 122, 926–928.
- Behnia, M., Khabazkhoob, M., Aliakbari, S., Abadi, A.E., Hashemi, H., Pourvahidi, P., 2013. Improvement in visual acuity and contrast sensitivity in patients with central serous chorioretinopathy after macular subthreshold laser therapy. *Retina (Phila. Pa.)* 33, 324–328.
- Bevis, T., Ratnakaram, R., Smith, M.F., Bhatti, M.T., 2005. Visual loss due to central serous chorioretinopathy during corticosteroid treatment for giant cell arteritis. *Clin. Exp. Ophthalmol.* 33, 437–439.
- Bousquet, E., Beydoun, T., Rothschild, P.-R., Bergin, C., Zhao, M., Batista, R., Brandely, M.-L., Couraud, B., Farman, N., Gaudric, A., Chast, F., Behar-Cohen, F., 2015. Spironolactone for non-resolving central serous chorioretinopathy: a randomized controlled cross-over study. *Retina (Phila. Pa.)* (in press).
- Bousquet, E., Beydoun, T., Zhao, M., Hassan, L., Offret, O., Behar-Cohen, F., 2013. Mineralocorticoid receptor antagonism in the treatment of chronic central serous chorioretinopathy: a pilot study. *Retina (Phila. Pa.)* 33, 2096–2102.
- Bouzas, E.A., Karadimas, P., Pourmaras, C.J., 2002. Central serous chorioretinopathy and glucocorticoids. *Surv. Ophthalmol.* 47, 431–448.
- Bouzas, E.A., Moret, P., Pourmaras, C.J., 1999. Central serous chorioretinopathy complicating solar retinopathy treated with glucocorticoids. *Graefes Arch. Clin. Exp. Ophthalmol.* 237, 166–168.
- Bouzas, E.A., Scott, M.H., Mastorakos, G., Chrousos, G.P., Kaiser-Kupfer, M.I., 1993. Central serous chorioretinopathy in endogenous hypercortisolism. *Arch. Ophthalmol.* 111, 1229–1233.
- Brancato, R., Pratesi, R., Leoni, G., Trabucchi, G., Vanni, U., 1989. Histopathology of diode and argon laser lesions in rabbit retina. A comparative study. *Invest. Ophthalmol. Vis. Sci.* 30, 1504–1510.
- Brancato, R., Scialdone, A., Pece, A., Coscas, G., Binaghi, M., 1987. Eight-year follow-up of central serous chorioretinopathy with and without laser treatment. *Graefes Arch. Clin. Exp. Ophthalmol.* 225, 166–168.
- Brandl, C., Helbig, H., Gamulescu, M.A., 2014. Choroidal thickness measurements during central serous chorioretinopathy treatment. *Int. Ophthalmol.* 34, 7–13.
- Briet, M., Schiffrin, E.L., 2013. Vascular actions of aldosterone. *J. Vasc. Res.* 50, 89–99.
- Broadhead, G.K., Chang, A., 2015 Jun. Intravitreal aflibercept for choroidal neovascularisation complicating chronic central serous chorioretinopathy. *Graefes Arch. Clin. Exp. Ophthalmol.* 253 (6), 979–981.
- Brodie, F.L., Charlson, E.S., Aleman, T.S., Salvo, R.T., Gewaily, D.Y., Lau, M.K., Farren, N.D., Engelhard, S.B., Pistilli, M., Brucker, A.J., 2015. Obstructive sleep apnea and central serous chorioretinopathy. *Retina (Phila. Pa.)* 35, 238–243.
- Browning, D.J., 1993. Nadolol in the treatment of central serous retinopathy. *Am. J. Ophthalmol.* 116, 770–771.
- Brown, N.J., 2013. Contribution of aldosterone to cardiovascular and renal inflammation and fibrosis. *Nat. Rev. Nephrol.* 9, 459–469.
- Bujarborua, D., 2001. Long-term follow-up of idiopathic central serous chorioretinopathy without laser. *Acta Ophthalmol. Scand.* 79, 417–421.
- Bujarborua, D., Chatterjee, S., Choudhury, A., Bori, G., Sarma, A.K., 2005. Fluorescein angiographic features of asymptomatic eyes in central serous chorioretinopathy. *Retina (Phila. Pa.)* 25, 422–429.
- Bujarborua, D., Nagpal, P.N., Deka, M., 2010. Smokestack leak in central serous chorioretinopathy. *Graefes Arch. Clin. Exp. Ophthalmol.* 248, 339–351.
- Burumcek, E., Mudun, A., Karacorlu, S., Arslan, M.O., 1997. Laser photocoagulation for persistent central serous retinopathy: results of long-term follow-up. *Ophthalmology* 104, 616–622.
- Caccavale, A., Romanazzi, F., Imparato, M., Negri, A., Morano, A., Ferentini, F., 2010. Low-dose aspirin as treatment for central serous chorioretinopathy. *Clin. Ophthalmol.* 4, 899–903.
- Caillaux, V., Gaucher, D., Gualino, V., Massin, P., Tadayoni, R., Gaudric, A., 2013. Morphologic characterization of dome-shaped macula in myopic eyes with serous macular detachment. *Am. J. Ophthalmol.* 156, 958.e1–967.e1.
- Carlesimo, S.C., Piazzi, G., Leone, C., Di Santo, L., Coccanari de Fornari, M.A., 2014. Masuda's central serous chorioretinopathy (C.S.C.R.) and its somatic investment in Narcissism: our observations on new psychiatric nosography. *Clin. Ter.* 165, 27–30.
- Carrai, P., Pichi, F., Bonsignore, F., Ciardella, A.P., Nucci, P., 2015 Apr. Wide-field spectral domain-optical coherence tomography in central serous chorioretinopathy. *Int. Ophthalmol.* 35 (2), 167–171.
- Carvalho-Recchia, C.A., Yannuzzi, L.A., Negrão, S., Spaide, R.F., Freund, K.B., Rodriguez-Coleman, H., Lenharo, M., Iida, T., 2002. Corticosteroids and central serous chorioretinopathy. *Ophthalmology* 109, 1834–1837.
- Casella, A.M.B., Berbel, R.F., Bressanim, G.L., Malaguido, M.R., Cardillo, J.A., 2012. *Helicobacter pylori* as a potential target for the treatment of central serous chorioretinopathy. *Clin. (Sao Paulo)* 67, 1047–1052.
- Castro-Correia, J., Coutinho, M.F., Rosas, V., Maia, J., 1992. Long-term follow-up of central serous retinopathy in 150 patients. *Doc. Ophthalmol.* 81, 379–386.
- Chaine, G., Haouat, M., Menard-Molcard, C., Favard, C., Vignal-Clermont, C., Campinchi-Tardy, F., Massin, P., Gaudric, A., Badelon, I., Nicolon, L., Sabatier, P., Guillevin, L., 2001. Central serous chorioretinopathy and systemic steroid therapy. *J. Fr. Ophthalmol.* 24, 139–146.
- Chan, W.-M., Lai, T.Y.Y., Lai, R.Y.K., Liu, D.T.L., Lam, D.S.C., 2008. Half-dose verteporfin photodynamic therapy for acute central serous chorioretinopathy: one-year results of a randomized controlled trial. *Ophthalmology* 115, 1756–1765.
- Chan, W.-M., Lai, T.Y.Y., Liu, D.T.L., Lam, D.S.C., 2007. Intravitreal bevacizumab (avastin) for choroidal neovascularization secondary to central serous chorioretinopathy, secondary to punctate inner choroidopathy, or of idiopathic origin. *Am. J. Ophthalmol.* 143, 977–983.
- Chan, W.M., Lam, D.S.C., Lai, T.Y.Y., Tam, B.S.M., Liu, D.T.L., Chan, C.K.M., 2003a. Choroidal vascular remodelling in central serous chorioretinopathy after indocyanine green guided photodynamic therapy with verteporfin: a novel treatment at the primary disease level. *Br. J. Ophthalmol.* 87, 1453–1458.
- Chan, W.M., Lam, D.S.C., Lai, T.Y.Y., Yuen, K.S.C., Liu, D.T.L., Chan, C.K.M., Chen, W.Q., 2003b. Treatment of choroidal neovascularization in central serous chorioretinopathy by photodynamic therapy with verteporfin. *Am. J. Ophthalmol.* 136, 836–845.
- Chan, W.M., Lim, T.-H., Pece, A., Silva, R., Yoshimura, N., 2010. Verteporfin PDT for non-standard indications—a review of current literature. *Graefes Arch. Clin. Exp. Ophthalmol.* 248, 613–626.
- Cheng, L.L., Kwok, A.K.H., Wat, N.M.S., Neoh, E.L., Jon, H.C.K., Lam, D.S.C., 2002. Graft-vs-host-disease-associated conjunctival chemosis and central serous chorioretinopathy after bone marrow transplant. *Am. J. Ophthalmol.* 134, 293–295.
- Chen, S.-N., Chen, Y.-C., Lian, I., 2014. Increased risk of coronary heart disease in male patients with central serous chorioretinopathy: results of a population-based cohort study. *Br. J. Ophthalmol.* 98, 110–114.
- Chen, S.-N., Hwang, J.-F., Tseng, L.-F., Lin, C.-J., 2008. Subthreshold diode micropulse photocoagulation for the treatment of chronic central serous chorioretinopathy with juxtafoveal leakage. *Ophthalmology* 115, 2229–2234.

- Chinenov, Y., Gupte, R., Rogatsky, I., 2013. Nuclear receptors in inflammation control: repression by GR and beyond. *Mol. Cell. Endocrinol.* 380, 55–64.
- Chinsky, N.D., Johnson, M.W., 2013. Treatment of subretinal fluid associated with dome-shaped macula. *Ophthalmic Surg. Lasers Imaging Retina* 44, 593–595.
- Chumbley, L.C., Frank, R.N., 1974. Central serous retinopathy and pregnancy. *Am. J. Ophthalmol.* 77, 158–160.
- Chung, H., Kim, K.-H., Kim, J.-G., Lee, S.Y., Yoon, Y.H., 2007. Retinal complications in patients with solid organ or bone marrow transplantations. *Transplantation* 83, 694–699.
- Chung, Y.-R., Seo, E.J., Lew, H.M., Lee, K.H., 2013. Lack of positive effect of intravitreal bevacizumab in central serous chorioretinopathy: meta-analysis and review. *Eye (Lond.)* 27, 1339–1346.
- Cohen, D., Gaudric, A., Coscas, G., Quentel, G., Binaghi, M., 1983. Diffuse retinal epitheliopathy and central serous chorioretinopathy. *J. Fr. Ophthalmol.* 6, 339–349.
- Conrad, R., Geiser, F., Kleiman, A., Zur, B., Karpawitz-Godt, A., 2014. Temperament and character personality profile and illness-related stress in central serous chorioretinopathy. *ScientificWorldJournal* 2014, 631687.
- Conrad, R., Weber, N.F., Lehnert, M., Holz, F.G., Liedtke, R., Eter, N., 2007. Alexithymia and emotional distress in patients with central serous chorioretinopathy. *Psychosomatics* 48, 489–495.
- Cook, C.S., Berry, L.M., Bible, R.H., Hribar, J.D., Hajdu, E., Liu, N.W., 2003. Pharmacokinetics and metabolism of [<sup>14</sup>C]epiprenone after oral administration to humans. *Drug Metab. Dispos.* 31, 1448–1455.
- Cotticelli, L., Borrelli, M., D'Alessio, A.C., Menziona, M., Villani, A., Piccolo, G., Montella, F., Iovene, M.R., Romano, M., 2006. Central serous chorioretinopathy and *Helicobacter pylori*. *Eur. J. Ophthalmol.* 16, 274–278.
- Cousins, L., Rigg, L., Hollingsworth, D., Meis, P., Halberg, F., Brink, G., Yen, S.S., 1983. Qualitative and quantitative assessment of the circadian rhythm of cortisol in pregnancy. *Am. J. Obstet. Gynecol.* 145, 411–416.
- Dang, Y., Mu, Y., Zhao, M., Li, L., Guo, Y., Zhu, Y., 2013. The effect of eradicating *Helicobacter pylori* on idiopathic central serous chorioretinopathy patients. *Ther. Clin. Risk Manag.* 9, 355–360.
- Dang, Y., Sun, X., Xu, Y., Mu, Y., Zhao, M., Zhao, J., Zhu, Y., Zhang, C., 2014. Subfoveal choroidal thickness after photodynamic therapy in patients with acute idiopathic central serous chorioretinopathy. *Ther. Clin. Risk Manag.* 10, 37–43.
- de Jong, E.K., Breukink, M.B., Schellevis, R.L., Bakker, B., Mohr, J.K., Fauser, S., Keunen, J.E., Hoyng, C.B., den Hollander, A.I., Boon, C.J., 2015 Mar. Chronic central serous chorioretinopathy is associated with genetic variants implicated in age-related macular degeneration. *Ophthalmology* 122 (3), 562–570.
- Delori, F.C., Dorey, C.K., Staurenghi, G., Arend, O., Goger, D.G., Weiter, J.J., 1995. In vivo fluorescence of the ocular fundus exhibits retinal pigment epithelium lipofuscin characteristics. *Invest. Ophthalmol. Vis. Sci.* 36, 718–729.
- Desai, U.R., Alhalel, A.A., Campen, T.J., Schiffman, R.M., Edwards, P.A., Jacobsen, G.R., 2003. Central serous chorioretinopathy in African Americans. *J. Natl. Med. Assoc.* 95, 553–559.
- Desmetre, T., Devoisselle, J.M., Mordon, S., 2000. Fluorescence properties and metabolic features of indocyanine green (ICG) as related to angiography. *Surv. Ophthalmol.* 45, 15–27.
- Dirani, A., Matet, A., Beydoun, T., Mantel, I., Behar-Cohen, F., 2014. Resolution of foveal detachment in dome-shaped macula after treatment by spironolactone: report of two cases and mini-review of the literature. *Clin. Ophthalmol.* 8, 999–1002.
- Eandi, C.M., Ober, M., Iranmanesh, R., Peiretti, E., Yannuzzi, L.A., 2005. Acute central serous chorioretinopathy and fundus autofluorescence. *Retina (Phila. Pa.)* 25, 989–993.
- Edalati, K., Roesch, M.T., Buchanan, M.L., Teeter, M., Maberley, D.A., 2009. Central serous chorioretinopathy and idiopathic nonhistaminergic angioedema. *Can. J. Ophthalmol.* 44, 606–607.
- Ellabban, A.A., Tsujikawa, A., Ooto, S., Yamashiro, K., Oishi, A., Nakata, I., Miyake, M., Akagi-Kurashige, Y., Ueda-Arakawa, N., Arichika, S., Yoshitake, S., Takahashi, A., Yoshimura, N., 2013. Focal choroidal excavation in eyes with central serous chorioretinopathy. *Am. J. Ophthalmol.* 156, 673–683.
- Eom, Y., Oh, J., Kim, S.-W., Huh, K., 2012. Systemic factors associated with central serous chorioretinopathy in Koreans. *Korean J. Ophthalmol.* 26, 260–264.
- Errera, M.-H., Kohly, R.P., da Cruz, L., 2013. Pregnancy-associated retinal diseases and their management. *Surv. Ophthalmol.* 58, 127–142.
- Ezra, N., Taban, M., Behroozan, D., 2011. Central serous chorioretinopathy associated with topical corticosteroids in a patient with psoriasis. *J. Drugs Dermatol* 10, 918–921.
- Falkenstein, E., Norman, A.W., Wehling, M., 2000. Mannheim classification of nongenomically initiated (rapid) steroid action(s). *J. Clin. Endocrinol. Metab.* 85, 2072–2075.
- Farman, N., Maubec, E., Poeggeler, B., Klatté, J.E., Jaisser, F., Paus, R., 2010. The mineralocorticoid receptor as a novel player in skin biology: beyond the renal horizon? *Exp. Dermatol* 19, 100–107.
- Farzan, K., Rezaei, L., Ghanbari, H., Dehghani, A., 2014. Central serous chorioretinopathy following kidney transplantation. *Saudi J. Kidney Dis. Transpl.* 25, 615–620.
- Fawzi, A.A., Cunningham, E.T., 2001. Central serous chorioretinopathy after bone marrow transplantation. *Am. J. Ophthalmol.* 131, 804–805.
- Fawzi, A.A., Holland, G.N., Kreiger, A.E., Heckenlively, J.R., Arroyo, J.G., Cunningham, E.T., 2006. Central serous chorioretinopathy after solid organ transplantation. *Ophthalmology* 113, 805.e5–813.e5.
- Feldman, R.D., Gros, R., 2013. Vascular effects of aldosterone: sorting out the receptors and the ligands. *Clin. Exp. Pharmacol. Physiol.* 40, 916–921.
- Fernandez, C.F., Mendoza, A.J., Arevalo, J.F., 2004. Central serous chorioretinopathy associated with topical dermal corticosteroids. *Retina (Phila. Pa.)* 24, 471–474.
- Ferrara, D., Mohler, K.J., Waheed, N., Adhi, M., Liu, J.J., Grulkowski, I., Kraus, M.F., Bauml, C., Hornegger, J., Fujimoto, J.G., Duker, J.S., 2014. En face enhanced-depth swept-source optical coherence tomography features of chronic central serous chorioretinopathy. *Ophthalmology* 121, 719–726.
- Ficker, L., Vafidis, G., While, A., Leaver, P., 1988. Long-term follow-up of a prospective trial of argon laser photocoagulation in the treatment of central serous retinopathy. *Br. J. Ophthalmol.* 72, 829–834.
- Fok, A.C.T., Chan, P.P.M., Lam, D.S.C., Lai, T.Y.Y., 2011. Risk factors for recurrence of serous macular detachment in untreated patients with central serous chorioretinopathy. *Ophthalmic Res.* 46, 160–163.
- Forooghian, F., Meleth, A.D., Cukras, C., Chew, E.Y., Wong, W.T., Meyerle, C.B., 2011. Finasteride for chronic central serous chorioretinopathy. *Retina (Phila. Pa.)* 31, 766–771.
- Framme, C., Walter, A., Gabler, B., Roeder, J., Sachs, H.G., Gabel, V.-P., 2005. Fundus autofluorescence in acute and chronic-recurrent central serous chorioretinopathy. *Acta Ophthalmol. Scand.* 83, 161–167.
- Fraunfelder, F.W., Fraunfelder, F.T., 2008. Central serous chorioretinopathy associated with sildenafil. *Retina* 28, 606–609.
- Freund, K.B., Mrejen, S., Jung, J., Yannuzzi, L.A., Boon, C.J.F., 2013. Increased fundus autofluorescence related to outer retinal disruption. *JAMA Ophthalmol.* 131, 1645–1649.
- Friberg, T.R., Eller, A.W., 1990. Serous retinal detachment resembling central serous chorioretinopathy following organ transplantation. *Graefes Arch. Clin. Exp. Ophthalmol.* 28, 305–309.
- Fujimoto, H., Gomi, F., Wakabayashi, T., Sawa, M., Tsujikawa, M., Tano, Y., 2008. Morphologic changes in acute central serous chorioretinopathy evaluated by fourier-domain optical coherence tomography. *Ophthalmology* 115, 1494–1500. e1–2.
- Fujiwara, T., Imamura, Y., Margolis, R., Slakter, J.S., Spaide, R.F., 2009. Enhanced depth imaging optical coherence tomography of the choroid in highly myopic eyes. *Am. J. Ophthalmol.* 148, 445–450.
- Fuller, P.J., Yao, Y., Yang, J., Young, M.J., 2012. Mechanisms of ligand specificity of the mineralocorticoid receptor. *J. Endocrinol.* 213, 15–24.
- Funder, J.W., 2013. Mineralocorticoid receptor antagonists: emerging roles in cardiovascular medicine. *Integr. Blood Press Control* 6, 129–138.
- Funder, J.W., 2005. RALES, EPHEBUS and redox. *J. Steroid Biochem. Mol. Biol.* 93, 121–125.
- Fung, A.T., Yannuzzi, L.A., Freund, K.B., 2012. Type 1 (sub-retinal pigment epithelial) neovascularization in central serous chorioretinopathy masquerading as neovascular age-related macular degeneration. *Retina (Phila. Pa.)* 32, 1829–1837.
- Furuta, M., Iida, T., Kishi, S., 2009. Foveal thickness can predict visual outcome in patients with persistent central serous chorioretinopathy. *Ophthalmologica* 223, 28–31.
- Gäckle, H.C., Lang, G.E., Freissler, K.A., Lang, G.K., 1998. Central serous chorioretinopathy. Clinical, fluorescein angiography and demographic aspects. *Ophthalmologie* 95, 529–533.
- Gardiner, P., Schrode, K., Quinlan, D., Martin, B.K., Boreham, D.R., Rogers, M.S., Stubbs, K., Smith, M., Karim, A., 1989. Spironolactone metabolism: steady-state serum levels of the sulfur-containing metabolites. *J. Clin. Pharmacol.* 29, 342–347.
- Garg, S.P., Dada, T., Talwar, D., Biswas, N.R., 1997. Endogenous cortisol profile in patients with central serous chorioretinopathy. *Br. J. Ophthalmol.* 81, 962–964.
- Gass, J.D., Little, H., 1995. Bilateral bullous exudative retinal detachment complicating idiopathic central serous chorioretinopathy during systemic corticosteroid therapy. *Ophthalmology* 102, 737–747.
- Gaucher, D., Erginay, A., Léclicre-Collet, A., Haouchine, B., Puech, M., Cohen, S.-Y., Massin, P., Gaudric, A., 2008. Dome-shaped macula in eyes with myopic posterior staphyloma. *Am. J. Ophthalmol.* 145, 909–914.
- Geltzer, A., Turalba, A., Vedula, S.S., 2013. Surgical Implantation of Steroids with Antiangiogenic Characteristics for Treating Neovascular Age-related Macular Degeneration. *Cochrane Database Syst Rev* 1, CD005022.
- Georgalas, I., Ladas, I., Georgopoulos, G., Petrou, P., 2011. Optic disc pit: a review. *Graefes Arch. Clin. Exp. Ophthalmol.* 249, 1113–1122.
- Ghanem, C.I., Gómez, P.C., Arana, M.C., Perassolo, M., Delli Carpini, G., Luquita, M.G., Veggli, L.M., Catania, V.A., Bengochea, L.A., Mottino, A.D., 2006. Induction of rat intestinal P-glycoprotein by spironolactone and its effect on absorption of orally administered digoxin. *J. Pharmacol. Exp. Ther.* 318, 1146–1152.
- Gilbert, C.M., Owens, S.L., Smith, P.D., Fine, S.L., 1984. Long-term follow-up of central serous chorioretinopathy. *Br. J. Ophthalmol.* 68, 815–820.
- Giusti, C., 2004. Association of *Helicobacter pylori* with central serous chorioretinopathy: hypotheses regarding pathogenesis. *Med. Hypotheses* 63, 524–527.
- Giusti, C., 2001. Central serous chorioretinopathy: a new extragastric manifestation of *Helicobacter pylori*? analysis of a clinical case. *Clin. Ter.* 152, 393–397.
- Goktas, A., 2014. Correlation of subretinal fluid volume with choroidal thickness and macular volume in acute central serous chorioretinopathy. *Eye (Lond.)* 28, 1431–1436.
- Golestaneh, N., Picaud, S., Mirshahi, M., 2002. The mineralocorticoid receptor in rodent retina: ontogeny and molecular identity. *Mol. Vis.* 8, 221–225.
- Golshahi, A., Klingmüller, D., Holz, F.G., Eter, N., 2010. Ketoconazole in the treatment of central serous chorioretinopathy: a pilot study. *Acta Ophthalmol.* 88, 576–581.
- Gomez-Sanchez, E., Gomez-Sanchez, C.E., 2014. The multifaceted mineralocorticoid



- receptor. *Compr. Physiol.* 4, 965–994.
- Gupta, M., Singh, A.D., Rundle, P.A., Rennie, I.G., 2004. Efficacy of photodynamic therapy in circumscribed choroidal haemangioma. *Eye (Lond.)* 18, 139–142.
- Guyer, D.R., Yannuzzi, L.A., Slakter, J.S., Sorenson, J.A., Ho, A., Orlock, D., 1994. Digital indocyanine green videoangiography of central serous chorioretinopathy. *Arch. Ophthalmol.* 112, 1057–1062.
- Haik, G.M., Perez, L.F., Murtagh, J.J., 1968. Central serous retinopathy. Consecutive development in daughter and mother. *Am. J. Ophthalmol.* 65, 612–615.
- Haimovici, R., Gragoudas, E.S., Duker, J.S., Sjaarda, R.N., Elliott, D., 1997. Central serous chorioretinopathy associated with inhaled or intranasal corticosteroids. *Ophthalmology* 104, 1653–1660.
- Haimovici, R., Koh, S., Gagnon, D.R., Lehrfeld, T., Wellik, S., Central Serous Chorioretinopathy Case-Control Study Group, 2004. Risk factors for central serous chorioretinopathy: a case-control study. *Ophthalmology* 111, 244–249.
- Haimovici, R., Rumelt, S., Melby, J., 2003. Endocrine abnormalities in patients with central serous chorioretinopathy. *Ophthalmology* 110, 698–703.
- Hamzah, F., Shinjima, A., Mori, R., Yuzawa, M., 2014. Choroidal thickness measurement by enhanced depth imaging and swept-source optical coherence tomography in central serous chorioretinopathy. *BMC Ophthalmol.* 14, 145.
- Han, J.M., Hwang, J.-M., Kim, J.S., Park, K.H., Woo, S.J., 2014. Changes in choroidal thickness after systemic administration of high-dose corticosteroids: a pilot study. *Invest. Ophthalmol. Vis. Sci.* 55, 440–445.
- Heimann, H., Jmor, F., Damato, B., 2013. Imaging of retinal and choroidal vascular tumours. *Eye (Lond.)* 27, 208–216.
- Herold, T.R., Prause, K., Wolf, A., Mayer, W.J., Ulbig, M.W., 2014. Spironolactone in the treatment of central serous chorioretinopathy - a case series. *Graefes Arch. Clin. Exp. Ophthalmol.* 252, 1985–1991.
- Heylen, E., Huang, A., Sun, D., Kaley, G., 2009. Nitric oxide-mediated dilation of arterioles to intraluminal administration of aldosterone. *J. Cardiovasc. Pharmacol.* 54, 535–542.
- Hirami, Y., Tsujikawa, A., Sasahara, M., Gotoh, N., Tamura, H., Otani, A., Mandai, M., Yoshimura, N., 2007. Alterations of retinal pigment epithelium in central serous chorioretinopathy. *Clin. Exp. Ophthalmol.* 35, 225–230.
- How, A.C.S.W., Koh, A.H.C., 2006. Angiographic characteristics of acute central serous chorioretinopathy in an Asian population. *Ann. Acad. Med. Singap.* 35, 77–79.
- Hua, R., Liu, L., Li, C., Chen, L., 2014. Evaluation of the effects of photodynamic therapy on chronic central serous chorioretinopathy based on the mean choroidal thickness and the lumen area of abnormal choroidal vessels. *Photodiagnosis Photodyn. Ther.* 11, 519–525.
- Hunter, R.G., 2012. Epigenetic effects of stress and corticosteroids in the brain. *Front. Cell. Neurosci.* 6, 18.
- Hurvitz, A.P., Hodapp, K.L., Jadgechew, J., Solomon, D.J., Stollendorf, H.S., Provencher, M.T., 2009. Central serous chorioretinopathy resulting in altered vision and color perception after glenohumeral corticosteroid injection. *Orthopedics* 32.
- Iacono, P., Battaglia, P.M., Papayannis, A., La Spina, C., Varano, M., Bandello, F., 2015. Jan 8. Acute central serous chorioretinopathy: a correlation study between fundus autofluorescence and spectral-domain OCT. *Graefes Arch. Clin. Exp. Ophthalmol.* (Epub ahead of print).
- Iida, T., Kishi, S., Hagimura, N., Shimizu, K., 1999. Persistent and bilateral choroidal vascular abnormalities in central serous chorioretinopathy. *Retina (Phila. Pa.)* 19, 508–512.
- Iida, T., Spaide, R.F., Negrao, S.G., Carvalho, C.A., Yannuzzi, L.A., 2001. Central serous chorioretinopathy after epidural corticosteroid injection. *Am. J. Ophthalmol.* 132, 423–425.
- Iida, T., Yannuzzi, L.A., Spaide, R.F., Borodoker, N., Carvalho, C.A., Negrao, S., 2003. Cystoid macular degeneration in chronic central serous chorioretinopathy. *Retina (Phila. Pa.)* 23, 1–7 quiz 137–138.
- Ikuno, Y., Kawaguchi, K., Nouchi, T., Yasuno, Y., 2010. Choroidal thickness in healthy Japanese subjects. *Invest. Ophthalmol. Vis. Sci.* 51, 2173–2176.
- Imamura, Y., Fujiwara, T., Margolis, R., Spaide, R.F., 2009. Enhanced depth imaging optical coherence tomography of the choroid in central serous chorioretinopathy. *Retina (Phila. Pa.)* 29, 1469–1473.
- Imamura, Y., Fujiwara, T., Spaide, R.F., 2011. Fundus autofluorescence and visual acuity in central serous chorioretinopathy. *Ophthalmology* 118, 700–705.
- Imasawa, M., Ohshiro, T., Gotoh, T., Imai, M., Iijima, H., 2005. Central serous chorioretinopathy following vitrectomy with intravitreal triamcinolone acetonide for diabetic macular oedema. *Acta Ophthalmol. Scand.* 83, 132–133.
- Inhoffen, W., Ziemssen, F., Bartz-Schmidt, K.U., 2012. Chronic central serous chorioretinopathy (cCSC): differential diagnosis to choroidal neovascularisation (CNV) secondary to age-related macular degeneration (AMD). *Klin. Monbl Augenheilkd* 229, 889–896.
- Jain, N., Johnson, M.W., 2014. Pathogenesis and treatment of maculopathy associated with cavitary optic disc anomalies. *Am. J. Ophthalmol.* 158, 423–435.
- Jampol, L.M., Weinreb, R., Yannuzzi, L., 2002. Involvement of corticosteroids and catecholamines in the pathogenesis of central serous chorioretinopathy: a rationale for new treatment strategies. *Ophthalmology* 109, 1765–1766.
- Jirarattanasopa, P., Ooto, S., Nakata, I., Tsujikawa, A., Yamashiro, K., Oishi, A., Yoshimura, N., 2012a. Choroidal thickness, vascular hyperpermeability, and complement factor H in age-related macular degeneration and polypoidal choroidal vasculopathy. *Invest. Ophthalmol. Vis. Sci.* 53, 3663–3672.
- Jirarattanasopa, P., Ooto, S., Tsujikawa, A., Yamashiro, K., Hangan, M., Hirata, M., Matsumoto, A., Yoshimura, N., 2012b. Assessment of macular choroidal thickness by optical coherence tomography and angiographic changes in central serous chorioretinopathy. *Ophthalmology* 119, 1666–1678.
- Juruena, M.F., Werne Baes, C.V., Menezes, I.C., Graeff, F.G., 2015. Early life stress in depressive patients: role of glucocorticoid and mineralocorticoid receptors and of hypothalamic-pituitary-adrenal axis activity. *Curr. Pharm. Des.* 21 (11), 1369–1378.
- Kamoun, R., Zhioua, R., Beltaief, O., Boussen, I., Ouertani, A.M., 2005. Central serous chorioretinopathy in a kidney transplant patient. *J. Fr. Ophtalmol.* 28, 51–54.
- Kang, N.H., Kim, Y.T., 2013. Change in subfoveal choroidal thickness in central serous chorioretinopathy following spontaneous resolution and low-fluence photodynamic therapy. *Eye (Lond.)* 27, 387–391.
- Kao, L.Y., 1998. Bilateral serous retinal detachment resembling central serous chorioretinopathy following epidural steroid injection. *Retina (Phila. Pa.)* 18, 479–481.
- Kapetanios, A.D., Donati, G., Bouzas, E., Mastorakos, G., Pournaras, C.J., 1998. Serous central chorioretinopathy and endogenous hypercortisolemia. *Klin. Monbl Augenheilkd* 212, 343–344.
- Karadimas, P., Bouzas, E.A., 2004. Glucocorticoid use represents a risk factor for central serous chorioretinopathy: a prospective, case-control study. *Graefes Arch. Clin. Exp. Ophthalmol.* 242, 800–802.
- Karashima, K., Fujioka, S., Harino, S., 2002. Two cases of central serous chorioretinopathy treated with photocoagulation after bone marrow transplantation. *Retina (Phila. Pa.)* 22, 651–653.
- Kassam, A.-A., White, W., Ling, R.H., Kitson, J.B., 2011. Loss of visual acuity due to central serous retinopathy after steroid injection into the shoulder bursa. *J. Shoulder Elb. Surg.* 20, e5–6.
- Katsimpris, J.M., Pournaras, C.J., Sehgelmeble, C.W., Petropoulos, I.K., 2007. Severe bilateral central serous chorioretinopathy in a black patient: 16 years follow-up. *Graefes Arch. Clin. Exp. Ophthalmol.* 245, 460–463.
- Keilhauer, C.N., Delori, F.C., 2006. Near-infrared autofluorescence imaging of the fundus: visualization of ocular melanin. *Invest. Ophthalmol. Vis. Sci.* 47, 3556–3564.
- Khairallah, M., Kahloun, R., Tugal-Tutkun, I., 2012. Central serous chorioretinopathy, corticosteroids, and uveitis. *Ocul. Immunol. Inflamm.* 20, 76–85.
- Kian-Ersi, F., Taheri, S., Akhlaghi, M.R., 2008. Ocular disorders in renal transplant patients. *Saudi J. Kidney Dis. Transpl.* 19, 751–755.
- Kim, H.C., Cho, W.B., Chung, H., 2012. Morphologic changes in acute central serous chorioretinopathy using spectral domain optical coherence tomography. *Korean J. Ophthalmol.* 26, 347–354.
- Kim, J.H., Kang, S.W., Kim, J.R., Kim, S.J., 2013. Variability of subfoveal choroidal thickness measurements in patients with age-related macular degeneration and central serous chorioretinopathy. *Eye (Lond.)* 27, 809–815.
- Kim, S.-K., Kim, S.-W., Oh, J., Huh, K., 2013. Near-infrared and short-wavelength autofluorescence in resolved central serous chorioretinopathy: association with outer retinal layer abnormalities. *Am. J. Ophthalmol.* 156, 157.e2–164.e2.
- Kim, S.-W., Oh, J., Kwon, S.-S., Yoo, J., Huh, K., 2011. Comparison of choroidal thickness among patients with healthy eyes, early age-related maculopathy, neovascular age-related macular degeneration, central serous chorioretinopathy, and polypoidal choroidal vasculopathy. *Retina (Phila. Pa.)* 31, 1904–1911.
- Kim, Y.C., Kim, S.D., Kim, K.S., 2012. A case of idiopathic central serous chorioretinopathy in a 12-year-old male treated with bevacizumab. *Korean J. Ophthalmol.* 26, 391–393.
- Kim, Y.T., Kang, S.W., Bai, K.H., 2011. Choroidal thickness in both eyes of patients with unilaterally active central serous chorioretinopathy. *Eye (Lond.)* 25, 1635–1640.
- Kitaya, N., Nagaoka, T., Hikichi, T., Sugawara, R., Fukui, K., Ishiko, S., Yoshida, A., 2003. Features of abnormal choroidal circulation in central serous chorioretinopathy. *Br. J. Ophthalmol.* 87, 709–712.
- Kitzmann, A.S., Pulido, J.S., Diehl, N.N., Hodge, D.O., Burke, J.P., 2008. The incidence of central serous chorioretinopathy in Olmsted county, Minnesota, 1980–2002. *Ophthalmology* 115, 169–173.
- Kleinberger, A.J., Patel, C., Lieberman, R.M., Malkin, B.D., 2011. Bilateral central serous chorioretinopathy caused by intranasal corticosteroids: a case report and review of the literature. *Laryngoscope* 121, 2034–2037.
- Kloos, P., Laube, I., Thoelen, A., 2008. Obstructive sleep apnea in patients with central serous chorioretinopathy. *Graefes Arch. Clin. Exp. Ophthalmol.* 246, 1225–1228.
- Kocabora, M.S., Durmaz, S., Kandemir, N., 2008. Exacerbation of central serous chorioretinopathy following intravitreal triamcinolone injection. *Graefes Arch. Clin. Exp. Ophthalmol.* 246, 1783–1786.
- Koh, A.H.C., Expert PCV Panel, Chen, L.-J., Chen, S.-J., Chen, Y., Giridhar, A., Iida, T., Kim, H., Yuk Yu Lai, T., Lee, W.K., Li, X., Han Lim, T., Ruamviboonsuk, P., Sharma, T., Tang, S., Yuzawa, M., 2013. Polypoidal choroidal vasculopathy: evidence-based guidelines for clinical diagnosis and treatment. *Retina (Phila. Pa.)* 33, 686–716.
- Koizumi, H., Yamagishi, T., Yamazaki, T., Kawasaki, R., Kinoshita, S., 2011. Subfoveal choroidal thickness in typical age-related macular degeneration and polypoidal choroidal vasculopathy. *Graefes Arch. Clin. Exp. Ophthalmol.* 249, 1123–1128.
- Konstantinidis, L., Mantel, I., Zografos, L., Ambresin, A., 2010. Intravitreal ranibizumab in the treatment of choroidal neovascularization associated with idiopathic central serous chorioretinopathy. *Eur. J. Ophthalmol.* 20, 955–958.
- Kon, Y., Iida, T., Maruko, I., Saito, M., 2008. The optical coherence tomography-ophthalmoscope for examination of central serous chorioretinopathy with precipitates. *Retina (Phila. Pa.)* 28, 864–869.
- Koss, M.J., Beger, I., Koch, F.H., 2012. Subthreshold diode laser micropulse photocoagulation versus intravitreal injections of bevacizumab in the treatment of

- central serous chorioretinopathy. *Eye (Lond.)* 26, 307–314.
- Koyama, M., Mizota, A., Igarashi, Y., Adachi-Usami, E., 2004. Seventeen cases of central serous chorioretinopathy associated with systemic corticosteroid therapy. *Ophthalmologica* 218, 107–110.
- Kunavisarut, P., Pathanapitoun, K., van Schooneveld, M., Rothova, A., 2009. Chronic central serous chorioretinopathy associated with serous retinal detachment in a series of Asian patients. *Ocul. Immunol. Inflamm.* 17, 269–277.
- Kuroda, S., Ikuno, Y., Yasuno, Y., Nakai, K., Usui, S., Sawa, M., Tsujikawa, M., Gomi, F., Nishida, K., 2013. Choroidal thickness in central serous chorioretinopathy. *Retina (Phila. Pa.)* 33, 302–308.
- Kurup, S.K., Oliver, A., Emanuelli, A., Hau, V., Callanan, D., 2012. Low-dose methotrexate for the treatment of chronic central serous chorioretinopathy: a retrospective analysis. *Retina (Phila. Pa.)* 32, 2096–2101.
- Lafaut, B.A., Salati, C., Priem, H., De Laey, J.J., 1998. Indocyanine green angiography is of value for the diagnosis of chronic central serous chorioretinopathy in elderly patients. *Graefes Arch. Clin. Exp. Ophthalmol.* 236, 513–521.
- Landa, G., Barnett, J.A., Garcia, P.M.T., Tai, K.W., Rosen, R.B., 2013. Quantitative and qualitative spectral domain optical coherence tomography analysis of subretinal deposits in patients with acute central serous retinopathy. *Ophthalmologica* 230, 62–68.
- Lanzetta, P., Furlan, F., Morgante, L., Veritti, D., Bandello, F., 2008. Nonvisible sub-threshold micropulse diode laser (810 nm) treatment of central serous chorioretinopathy. A pilot study. *Eur. J. Ophthalmol.* 18, 934–940.
- Leaver, P., Williams, C., 1979. Argon laser photocoagulation in the treatment of central serous retinopathy. *Br. J. Ophthalmol.* 63, 674–677.
- Lee, J.Y., Chae, J.B., Yang, S.J., Kim, J.-G., Yoon, Y.H., 2011. Intravitreal bevacizumab versus the conventional protocol of photodynamic therapy for treatment of chronic central serous chorioretinopathy. *Acta Ophthalmol.* 89, e293–294.
- Lehmann, M., Bousquet, E., Beydoun, T., Behar-Cohen, F., 2015. PACHYCHOROID: an inherited condition? *Retina (Phila. Pa.)* 35, 10–16.
- Lehmann, M., Wolff, B., Vasseur, V., Martinet, V., Manasseh, N., Sahel, J.A., Mauguet-Fayssé, M., 2013. Retinal and choroidal changes observed with “En face” enhanced-depth imaging OCT in central serous chorioretinopathy. *Br. J. Ophthalmol.* 97, 1181–1186.
- Levy, J., Marcus, M., Belfair, N., Klemperer, I., Lifshitz, T., 2005. Central serous chorioretinopathy in patients receiving systemic corticosteroid therapy. *Can. J. Ophthalmol.* 40, 217–221.
- Liew, G., Quin, G., Gillies, M., Fraser-Bell, S., 2013. Central serous chorioretinopathy: a review of epidemiology and pathophysiology: Central serous chorioretinopathy. *Clin. Exp. Ophthalmol.* 41, 201–214.
- Lim, J.L., Glassman, A.R., Aiello, L.P., Chakravarthy, U., Flaxel, C.J., Spaide, R.F., Macula Society CSC Collaborative Study Group, Research and Education Committee and Website Committee, 2014. Collaborative retrospective macula society study of photodynamic therapy for chronic central serous chorioretinopathy. *Ophthalmology* 121, 1073–1078.
- Lim, J.W., Kang, S.W., Kim, Y.-T., Chung, S.E., Lee, S.W., 2011. Comparative study of patients with central serous chorioretinopathy undergoing focal laser photocoagulation or photodynamic therapy. *Br. J. Ophthalmol.* 95, 514–517.
- Lim, J.W., Kim, M.U., 2011. The efficacy of intravitreal bevacizumab for idiopathic central serous chorioretinopathy. *Graefes Arch. Clin. Exp. Ophthalmol.* 249, 969–974.
- Lim, J.W., Kim, M.U., Shin, M.-C., 2010a. Aqueous humor and plasma levels of vascular endothelial growth factor and interleukin-8 in patients with central serous chorioretinopathy. *Retina (Phila. Pa.)* 30, 1465–1471.
- Lim, J.W., Ryu, S.J., Shin, M.C., 2010b. The effect of intravitreal bevacizumab in patients with acute central serous chorioretinopathy. *Korean J. Ophthalmol.* 24, 155–158.
- Lim, Z., Wong, D., 2008. Retinal pigment epithelial rip associated with idiopathic central serous chorioretinopathy. *Eye (Lond.)* 22, 471–473.
- Lin, E., Arriegg, P.G., Kim, R.Y., 2000. Familial central serous choroidopathy. *Graefes Arch. Clin. Exp. Ophthalmol.* 238, 930–931.
- Li, X.Q., Larsen, M., Munch, I.C., 2011. Subfoveal choroidal thickness in relation to sex and axial length in 93 Danish university students. *Invest. Ophthalmol. Vis. Sci.* 52, 8438–8441.
- Loo, J.-L., Lee, S.-Y., Ang, C.-L., 2006. Can long-term corticosteroids lead to blindness? A case series of central serous chorioretinopathy induced by corticosteroids. *Ann. Acad. Med. Singap.* 35, 496–499.
- Loo, R.H., Scott, I.U., Flynn, H.W., Gass, J.D.M., Murray, T.G., Lewis, M.L., Rosenfeld, P.J., Smiddy, W.E., 2002. Factors associated with reduced visual acuity during long-term follow-up of patients with idiopathic central serous chorioretinopathy. *Retina (Phila. Pa.)* 22, 19–24.
- Ma, J., Meng, N., Xu, X., Zhou, F., Qu, Y., 2014. System review and meta-analysis on photodynamic therapy in central serous chorioretinopathy. *Acta Ophthalmol.* 92, e594–601.
- Mansuetta, C.C., Mason 3rd, J.O., Swanner, J., Feist, R.M., White Jr., M.F., Thomley, M.L., McGwin Jr., G., Emond, T.L., 2004. An association between central serous chorioretinopathy and gastroesophageal reflux disease. *Am. J. Ophthalmol.* 137, 1096–1100.
- Margolis, R., Spaide, R.F., 2009. A pilot study of enhanced depth imaging optical coherence tomography of the choroid in normal eyes. *Am. J. Ophthalmol.* 147, 811–815.
- Maruko, I., Iida, T., Ojima, A., Sekiryu, T., 2011a. Subretinal dot-like precipitates and yellow material in central serous chorioretinopathy. *Retina (Phila. Pa.)* 31, 759–765.
- Maruko, I., Iida, T., Sugano, Y., Furuta, M., Sekiryu, T., 2011b. One-year choroidal thickness results after photodynamic therapy for central serous chorioretinopathy. *Retina (Phila. Pa.)* 31, 1921–1927.
- Maruko, I., Iida, T., Sugano, Y., Ojima, A., Ogasawara, M., Spaide, R.F., 2010. Subfoveal choroidal thickness after treatment of central serous chorioretinopathy. *Ophthalmology* 117, 1792–1799.
- Maruko, I., Iida, T., Sugano, Y., Ojima, A., Sekiryu, T., 2011c. Subfoveal choroidal thickness in fellow eyes of patients with central serous chorioretinopathy. *Retina (Phila. Pa.)* 31, 1603–1608.
- Mateo-Montoya, A., Mauguet-Fayssé, M., 2014. *Helicobacter pylori* as a risk factor for central serous chorioretinopathy: literature review. *World J. Gastrointest. Pathophysiol.* 5, 355–358.
- Matsumoto, H., Kishi, S., Otani, T., Sato, T., 2008. Elongation of photoreceptor outer segment in central serous chorioretinopathy. *Am. J. Ophthalmol.* 145, 162–168.
- Matsumoto, H., Kishi, S., Sato, T., Mukai, R., 2011. Fundus autofluorescence of elongated photoreceptor outer segments in central serous chorioretinopathy. *Am. J. Ophthalmol.* 151, 617.e1–623.e1.
- Matsumoto, H., Sato, T., Kishi, S., 2009. Outer nuclear layer thickness at the fovea determines visual outcomes in resolved central serous chorioretinopathy. *Am. J. Ophthalmol.* 148, 105.e1–110.e1.
- Mauguet-Fayssé, M., Kodjikian, L., Quaranta, M., Ben Ezra, D., Trepsat, C., Mion, F., Mégraud, F., 2002. *Helicobacter pylori* in central serous chorioretinopathy and diffuse retinal epitheliopathy. Results of the first prospective pilot study. *J. Fr. Ophthalmol.* 25, 1021–1025.
- Mazzolani, F., Togni, S., 2013. Oral administration of a curcumin-phospholipid delivery system for the treatment of central serous chorioretinopathy: a 12-month follow-up study. *Clin. Ophthalmol.* 7, 939–945.
- McCannel, T.A., Chmielowski, B., Finn, R.S., Goldman, J., Ribas, A., Wainberg, Z.A., McCannel, C.A., 2014. Bilateral subfoveal neurosensory retinal detachment associated with MEK inhibitor use for metastatic cancer. *JAMA Ophthalmol.* 132, 1005–1009.
- McCurley, A., Jaffe, I.Z., 2012. Mineralocorticoid receptors in vascular function and disease. *Mol. Cell. Endocrinol.* 350, 256–265.
- McGraw, A.P., Bagley, J., Chen, W.-S., Galayda, C., Nickerson, H., Armani, A., Caprio, M., Carmeliet, P., Jaffe, I.Z., 2013. Aldosterone increases early atherosclerosis and promotes plaque inflammation through a placental growth factor-dependent mechanism. *J. Am. Heart Assoc.* 2, e000018.
- Michael, J.C., Pak, J., Pulido, J., de Venecia, G., 2003. Central serous chorioretinopathy associated with administration of sympathomimetic agents. *Am. J. Ophthalmol.* 136, 182–185.
- Mihailidou, A.S., Ashton, A.W., 2014. Cardiac effects of aldosterone: does gender matter? *Steroids* 91, 32–37.
- Miki, A., Kondo, N., Yanagisawa, S., Bessho, H., Honda, S., Negi, A., 2014 May. Common variants in the complement factor H gene confer genetic susceptibility to central serous chorioretinopathy. *Ophthalmology* 121 (5), 1067–1072.
- Mitarai, K., Gomi, F., Tano, Y., 2006. Three-dimensional optical coherence tomographic findings in central serous chorioretinopathy. *Graefes Arch. Clin. Exp. Ophthalmol.* 244, 1415–1420.
- Mondal, L.K., Sarkar, K., Datta, H., Chatterjee, P.R., 2005. Acute bilateral central serous chorioretinopathy following intra-articular injection of corticosteroid. *Indian J. Ophthalmol.* 53, 132–134.
- Moon, S.J., Mieler, W.F., 2003. Retinal complications of bone marrow and solid organ transplantation. *Curr. Opin. Ophthalmol.* 14, 433–442.
- Mrejen, S., Sarraf, D., Mukkamala, S.K., Freund, K.B., 2013. Multimodal imaging of pigment epithelial detachment: a guide to evaluation. *Retina (Phila. Pa.)* 33, 1735–1762.
- Mrejen, S., Spaide, R.F., 2013. Optical coherence tomography: imaging of the choroid and beyond. *Surv. Ophthalmol.* 58, 387–429.
- Mudvari, S.S., Goff, M.J., Fu, A.D., McDonald, H.R., Johnson, R.N., Ai, E., Jumper, J.M., 2007. The natural history of pigment epithelial detachment associated with central serous chorioretinopathy. *Retina (Phila. Pa.)* 27, 1168–1173.
- Nguyen Dinh Cat, A., Griol-Charhbili, V., Loufrani, L., Labat, C., Benjamin, L., Farman, N., Lacolley, P., Henrion, D., Jaisser, F., 2010. The endothelial mineralocorticoid receptor regulates vasoconstrictor tone and blood pressure. *FASEB J.* 24, 2454–2463.
- Nguyen Dinh Cat, A., Jaisser, F., 2012. Extrarenal effects of aldosterone. *Curr. Opin. Nephrol. Hypertens.* 21, 147–156.
- Nicholson, B., Noble, J., Forooghian, F., Meyerle, C., 2013. Central serous chorioretinopathy: update on pathophysiology and treatment. *Surv. Ophthalmol.* 58, 103–126.
- Nicoló, M., Eandi, C.M., Aloveri, C., Grignolo, F.M., Traverso, C.E., Musetti, D., Cardillo Piccolino, F., 2014. Half-fluence versus half-dose photodynamic therapy in chronic central serous chorioretinopathy. *Am. J. Ophthalmol.* 157, 1033–1037.
- Nielsen, J.S., Jampol, L.M., 2011. Oral mifepristone for chronic central serous chorioretinopathy. *Retina (Phila. Pa.)* 31, 1928–1936.
- Noma, H., Funatsu, H., Mimura, T., Shimada, K., 2012. Comparison of the efficacy of intravitreal triamcinolone acetonide for cystoid macular edema with versus without serous retinal detachment in branch retinal vein occlusion: influence on macular sensitivity and morphology. *BMC Ophthalmol.* 12, 39.
- Odermatt, A., Atanasov, A.G., 2009. Mineralocorticoid receptors: emerging complexity and functional diversity. *Steroids* 74, 163–171.
- Oh, J.-H., Oh, J., Toglloom, A., Kim, S.-W., Huh, K., 2014. Biometric characteristics of eyes with central serous chorioretinopathy. *Invest. Ophthalmol. Vis. Sci.* 55, 1502–1508.
- Ojima, Y., Hangai, M., Sasahara, M., Gotoh, N., Inoue, R., Yasuno, Y., Makita, S., Yatagai, T., Tsujikawa, A., Yoshimura, N., 2007. Three-dimensional imaging of

- the foveal photoreceptor layer in central serous chorioretinopathy using high-speed optical coherence tomography. *Ophthalmology* 114, 2197–2207.
- Oliaei, F., Rasoulinejad, A., Seifi, B., 2007. An ophthalmological complication: central serous chorioretinopathy in a renal transplant recipient. *Transpl. Proc.* 39, 1134–1135.
- Oosterhuis, J.A., 1996. Familial central serous retinopathy. *Graefes Arch. Clin. Exp. Ophthalmol.* 234, 337–341.
- Ooto, S., Hangai, M., Sakamoto, A., Tsujikawa, A., Yamashiro, K., Ojima, Y., Yamada, Y., Mukai, H., Oshima, S., Inoue, T., Yoshimura, N., 2010a. High-resolution imaging of resolved central serous chorioretinopathy using adaptive optics scanning laser ophthalmoscopy. *Ophthalmology* 117, 1800–1809, 1809.e1–2.
- Ooto, S., Tsujikawa, A., Mori, S., Tamura, H., Yamashiro, K., Otani, A., Yoshimura, N., 2011. Retinal microstructural abnormalities in central serous chorioretinopathy and polypoidal choroidal vasculopathy. *Retina (Phila. Pa.)* 31, 527–534.
- Ooto, S., Tsujikawa, A., Mori, S., Tamura, H., Yamashiro, K., Yoshimura, N., 2010b. Thickness of photoreceptor layers in polypoidal choroidal vasculopathy and central serous chorioretinopathy. *Graefes Arch. Clin. Exp. Ophthalmol.* 248, 1077–1086.
- Ossewaarde-van Norel, J., Berg, E.M., Sijssens, K.M., Rothova, A., 2011. Subfoveal serous retinal detachment in patients with uveitic macular edema. *Arch. Ophthalmol.* 129, 158–162.
- Pang, C.E., Freund, K.B., 2015. Pachychoroid neovascularization. *Retina (Phila. Pa.)* 35, 1–9.
- Park, D.W., Schatz, H., Gaffney, M.M., McDonald, H.R., Johnson, R.N., Schaeffer, D., 1998. Central serous chorioretinopathy in two families. *Eur. J. Ophthalmol.* 8, 42–47.
- Park, S.J., Kim, B.H., Park, K.H., Woo, S.J., 2014 Dec. Punctate hyperfluorescence spot as a common chorioidopathy of central serous chorioretinopathy and polypoidal choroidal vasculopathy. *Am. J. Ophthalmol.* 158 (6), 1155–1163.
- Perkins, S.L., Kim, J.E., Pollack, J.S., Merrill, P.T., 2002. Clinical characteristics of central serous chorioretinopathy in women. *Ophthalmology* 109, 262–266.
- Piccolino, F.C., Borgia, L., 1994. Central serous chorioretinopathy and indocyanine green angiography. *Retina (Phila. Pa.)* 14, 231–242.
- Piccolino, F.C., De La Longrais, R.R., Manea, M., Cicinelli, S., 2008a. Posterior cystoid retinal degeneration in central serous chorioretinopathy. *Retina (Phila. Pa.)* 28, 1008–1012.
- Piccolino, F.C., De La Longrais, R.R., Manea, M., Cicinelli, S., Ravera, G., 2008b. Risk factors for posterior cystoid retinal degeneration in central serous chorioretinopathy. *Retina (Phila. Pa.)* 28, 1146–1150.
- Piccolino, F.C., de la Longrais, R.R., Ravera, G., Eandi, C.M., Ventre, L., Abdollahi, A., Manea, M., 2005. The foveal photoreceptor layer and visual acuity loss in central serous chorioretinopathy. *Am. J. Ophthalmol.* 139, 87–99.
- Pierce, K.K., Lane, R.G., 2009. Central serous chorioretinopathy associated with the use of ephedra. *Retin Cases Brief. Rep.* 3, 376–378.
- Pikkel, J., Beiran, I., Ophir, A., Miller, B., 2002. Acetazolamide for central serous retinopathy. *Ophthalmology* 109, 1723–1725.
- Piskunowicz, M., Jaracz, M., Lesiewska, H., Malukiewicz, G., Brozek-Pestka, M., Borkowska, A., 2014. Temperament profile in patients with central serous chorioretinopathy: a case-control study. *Eur. J. Ophthalmol.* 24, 392–395.
- Pitcher 3rd, J.D., Witkin, A.J., DeCroos, F.C., Ho, A.C., 2015 Jun. A prospective pilot study of intravitreal aflibercept for the treatment of chronic central serous chorioretinopathy: the CONTAIN study. *Br. J. Ophthalmol.* 99 (6), 848–852.
- Pitt, B., Remme, W., Zannad, F., Neaton, J., Martinez, F., Roniker, B., Bittman, R., Hurley, S., Kleiman, J., Gatlin, M., Eplerenone Post-Acute Myocardial Infarction Heart Failure Efficacy and Survival Study Investigators, 2003. Eplerenone, a selective aldosterone blocker, in patients with left ventricular dysfunction after myocardial infarction. *N. Engl. J. Med.* 348, 1309–1321.
- Pitt, B., Zannad, F., Remme, W.J., Cody, R., Castaigne, A., Perez, A., Palensky, J., Wittes, J., 1999. The effect of spironolactone on morbidity and mortality in patients with severe heart failure. *Randomized Aldactone Evaluation Study Investigators.* *N. Engl. J. Med.* 341, 709–717.
- Pizzimenti, J.J., Daniel, K.P., 2005. Central serous chorioretinopathy after epidural steroid injection. *Pharmacotherapy* 25, 1141–1146.
- Plateroti, A.M., Witmer, M.T., Kiss, S., D'Amico, D.J., 2014. Characteristics of intraretinal deposits in acute central serous chorioretinopathy. *Clin. Ophthalmol.* 8, 673–676.
- Polak, B.C., Baarsma, G.S., Snyers, B., 1995. Diffuse retinal pigment epitheliopathy complicating systemic corticosteroid treatment. *Br. J. Ophthalmol.* 79, 922–925.
- Prünte, C., 1995. Indocyanine green angiographic findings in central serous chorioretinopathy. *Int. Ophthalmol.* 19, 77–82.
- Pryds, A., Larsen, M., 2012. Choroidal thickness following extrafoveal photodynamic treatment with verteporfin in patients with central serous chorioretinopathy. *Acta Ophthalmol.* 90, 738–743.
- Quillen, D.A., Gass, D.M., Brod, R.D., Gardner, T.W., Blankenship, G.W., Gottlieb, J.L., 1996. Central serous chorioretinopathy in women. *Ophthalmology* 103, 72–79.
- Quin, G., Liew, G., Ho, I.-V., Gillies, M., Fraser-Bell, S., 2013. Diagnosis and interventions for central serous chorioretinopathy: review and update. *Clin. Exp. Ophthalmol.* 41, 187–200.
- Rahbani-Nobar, M.B., Javadzadeh, A., Ghojzadeh, L., Rafeey, M., Ghorbanihaghjo, A., 2011. The effect of *Helicobacter pylori* treatment on remission of idiopathic central serous chorioretinopathy. *Mol. Vis.* 17, 99–103.
- Razavi, S., Souied, E.H., Cavallero, E., Weber, M., Querques, G., 2014. Assessment of choroidal topographic changes by swept source optical coherence tomography after photodynamic therapy for central serous chorioretinopathy. *Am. J. Ophthalmol.* 157, 852–860.
- Reibaldi, M., Cardascia, N., Longo, A., Furino, C., Avitabile, T., Faro, S., Sanfilippo, M., Russo, A., Uva, M.G., Munno, F., Cannemi, V., Zagari, M., Boscia, F., 2010. Standard-fluence versus low-fluence photodynamic therapy in chronic central serous chorioretinopathy: a nonrandomized clinical trial. *Am. J. Ophthalmol.* 149, 307.e2–315.e2.
- Reynolds, R.M., 2013. Glucocorticoid excess and the developmental origins of disease: two decades of testing the hypothesis—2012 Curt Richter Award Winner. *Psychoneuroendocrinology* 38, 1–11.
- Rishi, P., Rishi, E., Mathur, G., Raval, V., 2013. Ocular perfusion pressure and choroidal thickness in eyes with polypoidal choroidal vasculopathy, wet-age-related macular degeneration, and normals. *Eye (Lond.)* 27, 1038–1043.
- Robertson, D.M., Ilstrup, D., 1983. Direct, indirect, and sham laser photocoagulation in the management of central serous chorioretinopathy. *Am. J. Ophthalmol.* 95, 457–466.
- Roisman, L., Magalhães, F.P., Lavinsky, D., Moraes, N., Hirai, F.E., Cardillo, J.A., Farah, M.E., 2013. Micropulse diode laser treatment for chronic central serous chorioretinopathy: a randomized pilot trial. *Ophthalmic Surg. Lasers Imaging Retina* 44, 465–470.
- Romero, P., Martinez, I., Salvat, M., 2005. Diffuse retinal pigment epitheliopathy and corticoid ointment topical treatment in a patient with psoriasis. *J. Fr. Ophthalmol.* 28, 1101–1104.
- Roshani, M., Davoodi, N.A., Seyyedmajidi, M.R., Zojaji, H., Sherafat, S.J., Hashemi, M., Zali, M.R., 2014. Association of *Helicobacter pylori* with central serous chorioretinopathy in Iranian patients. *Gastroenterol. Hepatol. Bed Bench* 7, 63–67.
- Ross, A., Ross, A.H., Mohamed, Q., 2011. Review and update of central serous chorioretinopathy. *Curr. Opin. Ophthalmol.* 22, 166–173.
- Sabet-Peyman, J., Salehi-Had, H., Fawzi, A.A., 2012. Multimodal imaging in a case of central serous chorioretinopathy following renal transplantation. *Ophthalmic Surg. Lasers Imaging* 43 Online e58–61.
- Saito, M., Saito, W., Hashimoto, Y., Yoshizawa, C., Fujiya, A., Noda, K., Ishida, S., 2013. Macular choroidal blood flow velocity decreases with regression of acute central serous chorioretinopathy. *Br. J. Ophthalmol.* 97, 775–780.
- Salvador, E., Shityakov, S., Förster, C., 2014. Glucocorticoids and endothelial cell barrier function. *Cell. Tissue Res.* 355, 597–605.
- Sarao, V., Veritti, D., Boscia, F., Lanzetta, P., 2014. Intravitreal steroids for the treatment of retinal diseases. *ScientificWorldJournal* 2014, 989501.
- Sasahara, M., Tsujikawa, A., Musashi, K., Gotoh, N., Otani, A., Mandai, M., Yoshimura, N., 2006. Polypoidal choroidal vasculopathy with choroidal vascular hyperpermeability. *Am. J. Ophthalmol.* 142, 601–607.
- Schaal, K.B., Hoeh, A.E., Scheuerle, A., Schuett, F., Dithmar, S., 2009. Intravitreal bevacizumab for treatment of chronic central serous chorioretinopathy. *Eur. J. Ophthalmol.* 19, 613–617.
- Schatz, H., Madeira, D., Johnson, R.N., McDonald, H.R., 1992. Central serous chorioretinopathy occurring in patients 60 years of age and older. *Ophthalmology* 99, 63–67.
- Scheider, A., Nasemann, J.E., Lund, O.E., 1993. Fluorescein and indocyanine green angiographies of central serous chorioidopathy by scanning laser ophthalmoscopy. *Am. J. Ophthalmol.* 115, 50–56.
- Schlötzer-Schrehardt, U., Viestenz, A., Naumann, G.O.H., Laqua, H., Michels, S., Schmidt-Erfurth, U., 2002. Dose-related structural effects of photodynamic therapy on choroidal and retinal structures of human eyes. *Graefes Arch. Clin. Exp. Ophthalmol.* 240, 748–757.
- Schubert, C., Pryds, A., Zeng, S., Xie, Y., Freund, K.B., Spaide, R.F., Merriam, J.C., Barbazzetto, I., Slakter, J.S., Chang, S., Munch, I.C., Drack, A.V., Hernandez, J., Yzer, S., Merriam, J.E., Linneberg, A., Larsen, M., Yannuzzi, L.A., Mullins, R.F., Allikmets, R., 2014 Jul. Cadherin 5 is regulated by corticosteroids and associated with central serous chorioretinopathy. *Hum. Mutat.* 35 (7), 859–867. <http://dx.doi.org/10.1002/humu.22551>.
- Sekiryu, T., Iida, T., Maruko, I., Saito, K., Kondo, T., 2010. Infrared fundus autofluorescence and central serous chorioretinopathy. *Invest. Ophthalmol. Vis. Sci.* 51, 4956–4962.
- Semeraro, F., Romano, M.R., Danzi, P., Morescalchi, F., Costagliola, C., 2012. Intravitreal bevacizumab versus low-fluence photodynamic therapy for treatment of chronic central serous chorioretinopathy. *Jpn. J. Ophthalmol.* 56, 608–612.
- Senturk, F., Karacorlu, M., Ozdemir, H., Karacorlu, S.A., Uysal, O., 2011. Micro-perimetric changes after photodynamic therapy for central serous chorioretinopathy. *Am. J. Ophthalmol.* 151, 303.e1–309.e1.
- Sharma, T., Shah, N., Rao, M., Gopal, L., Shanmugam, M.P., Gopalakrishnan, M., Bhende, P., Bhende, M., Shetty, N.S., Baluswamy, S., 2004. Visual outcome after discontinuation of corticosteroids in atypical severe central serous chorioretinopathy. *Ophthalmology* 111, 1708–1714.
- Shields, C.L., Honavar, S.G., Shields, J.A., Cater, J., Demirci, H., 2001. Circumscribed choroidal hemangioma: clinical manifestations and factors predictive of visual outcome in 200 consecutive cases. *Ophthalmology* 108, 2237–2248.
- Shields, C.L., Pellegrini, M., Ferenczy, S.R., Shields, J.A., 2014. Enhanced depth imaging optical coherence tomography of intraocular tumors: from placid to sea-sick to rock and rolling topography—the 2013 Francesco Orzalesi Lecture. *Retina (Phila. Pa.)* 34, 1495–1512.
- Shin, J.Y., Woo, S.J., Yu, H.G., Park, K.H., 2011. Comparison of efficacy and safety between half-fluence and full-fluence photodynamic therapy for chronic central serous chorioretinopathy. *Retina (Phila. Pa.)* 31, 119–126.
- Shin, M.C., Lim, J.W., 2011. Concentration of cytokines in the aqueous humor of patients with central serous chorioretinopathy. *Retina (Phila. Pa.)* 31, 1937–1943.
- Shinojima, A., Hirose, T., Mori, R., Kawamura, A., Yuzawa, M., 2010. Morphologic

- findings in acute central serous chorioretinopathy using spectral domain optical coherence tomography with simultaneous angiography. *Retina* (Phila. Pa.) 30, 193–202.
- Shin, Y.U., Lee, B.R., 2012. Retro-mode imaging for retinal pigment epithelium alterations in central serous chorioretinopathy. *Am. J. Ophthalmol.* 154, 155.e4–163.e4.
- Sibayan, S.A., Kobuch, K., Spiegel, D., Eckert, E., Leser, R., Monzer, J., Gabel, V.P., 2000. Epinephrine, but not dexamethasone, induces apoptosis in retinal pigment epithelium cells in vitro: possible implications on the pathogenesis of central serous chorioretinopathy. *Graefes Arch. Clin. Exp. Ophthalmol.* 238, 515–519.
- Simon, P., Glacet-Bernard, A., Binaghi, M., Coscas, G., Soubrane, G., 2001. Choroidal neovascularization as a complication following laser treatment of central serous chorioretinopathy. *J. Fr. Ophtalmol.* 24, 64–68.
- Singh, A.D., Demirci, H., Shields, C.L., Shields, J.A., 2003. Central serous chorioretinopathy as a complication of postcardiac transplant corticosteroid therapy. *Eye* (Lond.) 17, 522–524.
- Spaide, R.F., Campeas, L., Haas, A., Yannuzzi, L.A., Fisher, Y.L., Guyer, D.R., Slakter, J.S., Sorenson, J.A., Orlock, D.A., 1996a. Central serous chorioretinopathy in younger and older adults. *Ophthalmology* 103, 2070–2079 discussion 2079–2080.
- Spaide, R.F., Hall, L., Haas, A., Campeas, L., Yannuzzi, L.A., Fisher, Y.L., Guyer, D.R., Slakter, J.S., Sorenson, J.A., Orlock, D.A., 1996b. Indocyanine green videoangiography of older patients with central serous chorioretinopathy. *Retina* (Phila. Pa.) 16, 203–213.
- Spaide, R.F., Klancnik, J.M., 2005. Fundus autofluorescence and central serous chorioretinopathy. *Ophthalmology* 112, 825–833.
- Spraul, C.W., Lang, G.E., Lang, G.K., 1998. Retinal pigment epithelial changes associated with systemic corticosteroid treatment: report of cases and review of the literature. *Ophthalmologica* 212, 142–148.
- Spraul, C.W., Lang, G.E., Lang, G.K., 1997. Central serous chorioretinopathy in systemic therapy with corticosteroids. *Ophthalmologie* 94, 392–396.
- Suzuki, M., Gomi, F., Hara, C., Sawa, M., Nishida, K., 2014. Characteristics of central serous chorioretinopathy complicated by focal choroidal excavation. *Retina* (Phila. Pa.) 34, 1216–1222.
- Tada, Y., Kitazato, K.T., Tamura, T., Yagi, K., Shimada, K., Kinouchi, T., Satomi, J., Nagahiro, S., 2009. Role of mineralocorticoid receptor on experimental cerebral aneurysms in rats. *Hypertension* 54, 552–557.
- Tamura, N., Sakai, T., Tsunooka, H., 2014. Spontaneous resolution of foveal detachment in dome-shaped macula observed by spectral domain optical coherence tomography. *Clin. Ophthalmol.* 8, 83–86.
- Teke, M.Y., Elgin, U., Nalcacioglu-Yuksekkaya, P., Sen, E., Ozdal, P., Ozturk, F., 2014. Comparison of autofluorescence and optical coherence tomography findings in acute and chronic central serous chorioretinopathy. *Int. J. Ophthalmol.* 7, 350–354.
- Ter Heegde, F., De Rijk, R.H., Vinkers, C.H., 2015. The brain mineralocorticoid receptor and stress resilience. *Psychoneuroendocrinology* 52C, 92–110.
- Tewari, H.K., Gadia, R., Kumar, D., Venkatesh, P., Garg, S.P., 2006. Sympathetic-parasympathetic activity and reactivity in central serous chorioretinopathy: a case-control study. *Invest. Ophthalmol. Vis. Sci.* 47, 3474–3478.
- Thinda, S., Lam, K., Park, S.S., 2015 Apr. Unintentional secondary exogenous corticosteroid exposure and central serous chorioretinopathy. *Eye* (Lond) 29 (4), 577–579. <http://dx.doi.org/10.1038/eye.2014.328> (Epub 2015 Jan 16).
- Tittl, M.K., Spaide, R.F., Wong, D., Pilotto, E., Yannuzzi, L.A., Fisher, Y.L., Freund, B., Guyer, D.R., Slakter, J.S., Sorenson, J.A., 1999. Systemic findings associated with central serous chorioretinopathy. *Am. J. Ophthalmol.* 128, 63–68.
- Tittl, M., Maar, N., Polska, E., Weigert, G., Stur, M., Schmetterer, L., 2005. Choroidal hemodynamic changes during isometric exercise in patients with inactive central serous chorioretinopathy. *Invest. Ophthalmol. Vis. Sci.* 46, 4717–4721.
- Tittl, M., Polska, E., Kircher, K., Kruger, A., Maar, N., Stur, M., Schmetterer, L., 2003. Topical fundus pulsation measurement in patients with active central serous chorioretinopathy. *Arch. Ophthalmol.* 121, 975–978.
- Toyama, T., Ohtomo, K., Noda, Y., Ueta, T., 2014. Polypoidal choroidal vasculopathy and history of central serous chorioretinopathy. *Eye* (Lond.) 28, 992–997.
- Tsai, D.-C., Chen, S.-J., Huang, C.-C., Chou, P., Chung, C.-M., Chan, W.-L., Huang, P.-H., Lin, S.-J., Chen, J.-W., Chen, T.-J., Leu, H.-B., 2014. Risk of central serous chorioretinopathy in adults prescribed oral corticosteroids: a population-based study in Taiwan. *Retina* (Phila. Pa.) 34, 1867–1874.
- Tsai, D.-C., Chen, S.-J., Huang, C.-C., Chou, P., Chung, C.-M., Huang, P.-H., Lin, S.-J., Chen, J.-W., Chen, T.-J., Leu, H.-B., Chan, W.-L., 2013a. Epidemiology of idiopathic central serous chorioretinopathy in Taiwan, 2001–2006: a population-based study. *PLoS One* 8, e66858.
- Tsai, D.-C., Huang, C.-C., Chen, S.-J., Chou, P., Chung, C.-M., Chan, W.-L., Huang, P.-H., Chen, T.-J., Lin, S.-J., Chen, J.-W., Leu, H.-B., 2012. Central serous chorioretinopathy and risk of ischaemic stroke: a population-based cohort study. *Br. J. Ophthalmol.* 96, 1484–1488.
- Tsai, D.-C., Huang, C.-C., Chen, S.-J., Chou, P., Chung, C.-M., Chan, W.-L., Huang, P.-H., Lin, S.-J., Chen, J.-W., Leu, H.-B., 2013b. Increased risk of erectile dysfunction among males with central serous chorioretinopathy – a retrospective cohort study. *Acta Ophthalmol.* 91, 666–671.
- Tsujikawa, A., Ojima, Y., Yamashiro, K., Ooto, S., Tamura, H., Nakagawa, S., Yoshimura, N., 2010. Punctate hyperfluorescent spots associated with central serous chorioretinopathy as seen on indocyanine green angiography. *Retina* (Phila. Pa.) 30, 801–809.
- Uetani, R., Ito, Y., Oiwa, K., Ishikawa, K., Terasaki, H., 2012. Half-dose vs one-third-dose photodynamic therapy for chronic central serous chorioretinopathy. *Eye* (Lond.) 26, 640–649.
- Urner-Bloch, U., Urner, M., Stieger, P., Galliker, N., Winterton, N., Zübel, A., Moutouh-de Parseval, L., Dummer, R., Goldinger, S.M., 2014. Transient MEK inhibitor-associated retinopathy in metastatic melanoma. *Ann. Oncol.* 25, 1437–1441.
- Uyama, M., Matsunaga, H., Matsubara, T., Fukushima, I., Takahashi, K., Nishimura, T., 1999. Indocyanine green angiography and pathophysiology of multifocal posterior pigment epitheliopathy. *Retina* (Phila. Pa.) 19, 12–21.
- Van Velthoven, M.E.J., Verbraak, F.D., Garcia, P.M., Schlingemann, R.O., Rosen, R.B., de Smet, M.D., 2005. Evaluation of central serous retinopathy with en face optical coherence tomography. *Br. J. Ophthalmol.* 89, 1483–1488.
- Verma, L., Sinha, R., Venkatesh, P., Tewari, H.K., 2004. Comparative evaluation of diode laser versus argon laser photocoagulation in patients with central serous retinopathy: a pilot, randomized controlled trial [ISRCTN84128484]. *BMC Ophthalmol.* 4, 15.
- Viola, F., Dell'Arti, L., Benatti, E., Invernizzi, A., Mapelli, C., Ferrari, F., Ratiglia, R., Staurengi, G., Barteselli, G., 2015. Choroidal findings in dome-shaped macula in highly myopic eyes: a longitudinal study. *Am. J. Ophthalmol.* 159, 44–52.
- Von Rückmann, A., Fitzke, F.W., Fan, J., Halfyard, A., Bird, A.C., 2002. Abnormalities of fundus autofluorescence in central serous retinopathy. *Am. J. Ophthalmol.* 133, 780–786.
- Wakakura, M., Ishikawa, S., 1984. Central serous chorioretinopathy complicating systemic corticosteroid treatment. *Br. J. Ophthalmol.* 68, 329–331.
- Wakakura, M., Song, E., Ishikawa, S., 1997. Corticosteroid-induced central serous chorioretinopathy. *Jpn. J. Ophthalmol.* 41, 180–185.
- Walker, B.R., Best, R., Shackleton, C.H., Padfield, P.L., Edwards, C.R., 1996. Increased vasoconstrictor sensitivity to glucocorticoids in essential hypertension. *Hypertension* 27, 190–196.
- Wang, M., Munch, I.C., Hasler, P.W., Prünte, C., Larsen, M., 2008. Central serous chorioretinopathy. *Acta Ophthalmol.* 86, 126–145.
- Wang, M., Sander, B., la Cour, M., Larsen, M., 2005. Clinical characteristics of sub-retinal deposits in central serous chorioretinopathy. *Acta Ophthalmol. Scand.* 83, 691–696.
- Warrow, D.J., Hoang, Q.V., Freund, K.B., 2013. Pachychoroid pigment epitheliopathy. *Retina* (Phila. Pa.) 33, 1659–1672.
- Weenink, A.C., Borsje, R.A., Oosterhuis, J.A., 2001. Familial chronic central serous chorioretinopathy. *Ophthalmologica* 215, 183–187.
- Wei, W.B., Xu, L., Jonas, J.B., Shao, L., Du, K.F., Wang, S., Chen, C.X., Xu, J., Wang, Y.X., Zhou, J.Q., You, Q.S., 2013. Subfoveal choroidal thickness: the Beijing Eye Study. *Ophthalmology* 120, 175–180.
- Wilkinson-Berka, J.L., Tan, G., Jaworski, K., Miller, A.G., 2009. Identification of a retinal aldosterone system and the protective effects of mineralocorticoid receptor antagonism on retinal vascular pathology. *Circ. Res.* 104, 124–133.
- Williamson, J., Nuki, G., 1970. Macular lesions during systemic therapy with depot tetracosactin. *Br. J. Ophthalmol.* 54, 405–409.
- Wu, Z.H.Y., Lai, R.Y.K., Yip, Y.W.Y., Chan, W.M., Lam, D.S.C., Lai, T.Y.Y., 2011. Improvement in multifocal electroretinography after half-dose verteporfin photodynamic therapy for central serous chorioretinopathy: a randomized placebo-controlled trial. *Retina* (Phila. Pa.) 31, 1378–1386.
- Wyman, G.J., 1963. Central serous retinopathy in twins. *Am. J. Ophthalmol.* 55, 1265.
- Yalcinbayir, O., Geliskan, O., Akova-Budak, B., Ozkaya, G., Gorkem Cevik, S., Yucel, A.A., 2014. Correlation of spectral domain optical coherence tomography findings and visual acuity in central serous chorioretinopathy. *Retina* (Phila. Pa.) 34, 705–712.
- Yang, L., Jonas, J.B., Wei, W., 2013a. Optical coherence tomography-assisted enhanced depth imaging of central serous chorioretinopathy. *Invest. Ophthalmol. Vis. Sci.* 54, 4659–4665.
- Yang, L., Jonas, J.B., Wei, W., 2013b. Choroidal vessel diameter in central serous chorioretinopathy. *Acta Ophthalmol.* 91, e358–362.
- Yannuzzi, L.A., 2011. Indocyanine green angiography: a perspective on use in the clinical setting. *Am. J. Ophthalmol.* 151, 745.e1–751.e1.
- Yannuzzi, L.A., 2010. Central serous chorioretinopathy: a personal perspective. *Am. J. Ophthalmol.* 149, 361–363.
- Yannuzzi, L.A., 1987. Type-A behavior and central serous chorioretinopathy. *Retina* (Phila. Pa.) 7, 111–131.
- Yannuzzi, L.A., 1986. Type A behavior and central serous chorioretinopathy. *Trans. Am. Ophthalmol. Soc.* 84, 799–845.
- Yannuzzi, L.A., Freund, K.B., Goldbaum, M., Scallati-Sforzolini, B., Guyer, D.R., Spaide, R.F., Maberley, D., Wong, D.W.K., Slakter, J.S., Sorenson, J.A., Fisher, Y.L., Orlock, D.A., 2000. Polypoidal choroidal vasculopathy masquerading as central serous chorioretinopathy. *Ophthalmology* 107, 767–777.
- Yannuzzi, L.A., Shakin, J.L., Fisher, Y.L., Altomonte, M.A., 1984. Peripheral retinal detachments and retinal pigment epithelial atrophic tracts secondary to central serous pigment epitheliopathy. *Ophthalmology* 91, 1554–1572.
- Yannuzzi, L.A., Slakter, J.S., Kaufman, S.R., Gupta, K., 1992. Laser treatment of diffuse retinal pigment epitheliopathy. *Eur. J. Ophthalmol.* 2, 103–114.
- Yoshioka, H., Katsume, Y., Akune, H., 1982. Experimental central serous chorioretinopathy in monkey eyes: fluorescein angiographic findings. *Ophthalmologica* 185, 168–178.
- Young, M.J., Rickard, A.J., 2015. Mineralocorticoid receptors in the heart: lessons from cell-selective transgenic animals. *J. Endocrinol.* 224, R1–R13.
- Zakir, S.M., Shukla, M., Simi, Z.-U.-R., Ahmad, J., Sajid, M., 2009. Serum cortisol and testosterone levels in idiopathic central serous chorioretinopathy. *Indian J. Ophthalmol.* 57, 419–422.
- Zhao, M., Bousquet, E., Valamanesh, F., Farman, N., Jeanny, J.-C., Jaisser, F., Behar-Cohen, F.F., 2011. Differential regulations of AQP4 and Kir4.1 by triamcinolone acetonide and dexamethasone in the healthy and inflamed retina. *Invest.*

- Ophthalmol. Vis. Sci. 52, 6340–6347.
- Zhao, M., Célérier, I., Bousquet, E., Jeanny, J.-C., Jonet, L., Savoldelli, M., Offret, O., Curan, A., Farman, N., Jaisser, F., Behar-Cohen, F., 2012. Mineralocorticoid receptor is involved in rat and human ocular chorioretinopathy. *J. Clin. Invest* 122, 2672–2679.
- Zhao, M., Valamanesh, F., Celerier, I., Savoldelli, M., Jonet, L., Jeanny, J.-C., Jaisser, F., Farman, N., Behar-Cohen, F., 2010. The neuroretina is a novel mineralocorticoid target: aldosterone up-regulates ion and water channels in Müller glial cells. *FASEB J.* 24, 3405–3415.