

A word of caution: Spontaneous rupture of the noncoronary sinus of the Freestyle xenograft: Two cases and review of the literature



Ziyad Gunga, MD,^a Salah Dine Qanadli, MD, PhD,^b Guillaume Fahrni, MD,^b Mario Verdugo-Marchese, MD,^a Simon Koestner, MD,^a Valentina Rancati, MD,^c Zied Ltaief, MD,^c and Matthias Kirsch, MD, PhD,^a Lausanne, Switzerland

From the Departments of ^aCardiac Surgery, ^bRadiology, and ^cAnesthesiology, Centre Hospitalier Universitaire Vaudois, Lausanne University, Lausanne, Switzerland.

Disclosures: The authors reported no conflicts of interest.

The *Journal* policy requires editors and reviewers to disclose conflicts of interest and to decline handling or reviewing manuscripts for which they may have a conflict of interest. The editors and reviewers of this article have no conflicts of interest.

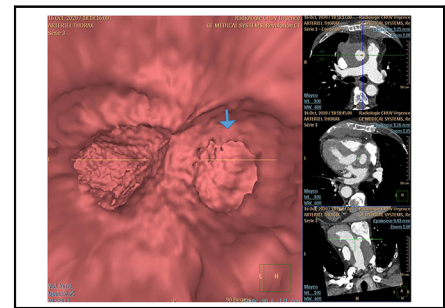
Received for publication March 7, 2022; revisions received May 19, 2022; accepted for publication June 14, 2022; available ahead of print July 19, 2022.

Address for reprints: Ziyad Gunga, MD, Department of Cardiac Surgery, Centre Hospitalier Universitaire Vaudois, Lausanne University, Lausanne, Switzerland (E-mail: ziyad.gunga@chuv.ch).

JTCVS Open 2022;11:59-61
2666-2736

Copyright © 2022 The Author(s). Published by Elsevier Inc. on behalf of The American Association for Thoracic Surgery. This is an open access article under the CC BY license (<http://creativecommons.org/licenses/by/4.0/>).

<https://doi.org/10.1016/j.jxon.2022.06.012>



Endovascular virtual reality angiography highlighting the fenestration (arrow) of the noncoronary sinus seen from the inside (case 2).

CENTRAL MESSAGE

Freestyle bioprosthesis is an ideal substitute for aortic root replacement. Rupture of the Freestyle has been rarely described. We present 2 cases of spontaneous rupture of the noncoronary sinus.

▶ Video clip is available online.

The porcine stentless Freestyle xenograft (Medtronic Inc) has proved to be an ideal substitute for aortic root replacement (ARR) as it provides excellent hemodynamics and durability.^{1,2} Nonetheless, like other bioprostheses, structural valve deterioration is observed in the long term, mostly due to aortic cusp tears. However, spontaneous rupture of the Freestyle xenograft aortic wall has also been reported.^{3,4} We present 2 patients who developed pseudoaneurysm after ARR using a Freestyle xenograft, related to spontaneous rupture of the noncoronary sinus (NCS) of Valsalva.

CASE 1

In November 2018, an 80-year-old male patient with a history of aortic root dilation had a complete ARR using a 25-mm Freestyle xenograft. In August 2020, the patient was hospitalized for acute lung edema related to massive aortic valve insufficiency due to deformation of the xenograft by a pseudoaneurysm. Intraoperative findings noted a tear of the upper portion of the NCS of the Freestyle xenograft. This part was trimmed, and a reconstruction of the sinotubular junction was achieved using a 24-mm Dacron graft, strengthened by an extraluminal pericardial patch.

In October 2020, a computed tomography scan highlighted a recurring pseudoaneurysm, triggering a third

operation. A 1-cm rupture of the NCS was identified, without sign of infection. The Freestyle xenograft was trimmed, leaving the annulus, and a redo ARR was performed using a 23-mm Freestyle xenograft. The patient died 1 week later due to sudden cardiac arrest secondary to acute hypoxemia following bronchoaspiration. Transthoracic echocardiogram confirmed the absence of pericardial tamponade.

CASE 2

A 72-year-old female patient with a history of aortic valve replacement in 2018 was admitted emergently for type A dissection in February 2020. ARR using a 25-mm Freestyle xenograft was performed, associated with hemi-arch replacement.

In November 2020, the patient was reoperated for severe tricuspid insufficiency, and operative findings pinpointed a small pseudoaneurysm on the suture line between the distal

portion of the Freestyle xenograft and the Dacron prosthesis. This 2-mm orifice was sutured and strengthened with heterologous pericardium and BioGlue (CryoLife, Inc).

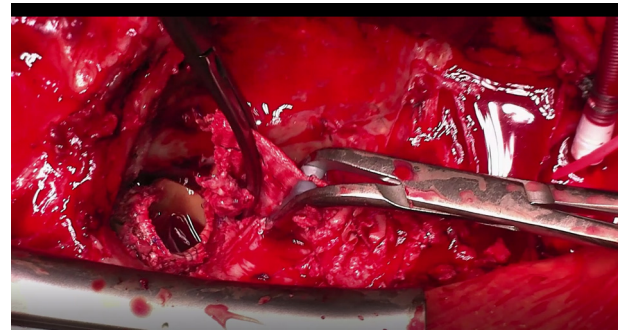
In October 2021, an acute thoracic pain triggered a computed tomography scan that showed a large circulating pseudoaneurysm of the aortic root originating from a tear in the NCS of the Freestyle xenograft (Figure 1). Intraoperative findings confirmed the rupture in the central part of the NCS, without sign of infection (Video 1). A redo ARR using a 25-mm Freestyle was performed. The patient had an uneventful recovery. Both patients gave written informed consent for the use of their data for publication use.

COMMENT

The Freestyle xenograft is the only currently commercially available aortic root xenograft. It provides excellent hemodynamic results in terms of postoperative transvalvular gradients, effective orifice area, and regression of left ventricular hypertrophy. Furthermore, excellent durability has been reported by several studies, with 1-year freedom from reoperation rates of more than 90%.^{1,2}

However, early- and mid-term structural valve deteriorations have been outlined. In addition to cusp tears, the aortic wall of the Freestyle xenograft seems also vulnerable, as highlighted by the present cases. Six similar cases of spontaneous rupture of the Freestyle xenograft wall have been previously reported, and are summarized in Table 1. Interestingly, the rupture occurred most frequently in the noncoronary sinus of the xenograft.

Since neither of the cases has been related to an infectious origin, we retain 3 hypotheses to explain these clinical observations. Ozaki and colleagues³ suggested a weakness in the transitional zone between annular collagen fibers and the aortic elastic wall. Similarly, using biomechanical analyses, Takaya and colleagues⁴ noted that NCS was significantly



VIDEO 1. Perioperative findings in case 2. We have highlighted the hole in the noncoronary sinus (NCS) of the Freestyle bioprosthesis, a circular defect of 1 cm. A solidified BioGlue remnant was removed from the pseudoaneurysm adjacent to the NCS of the Freestyle. Video available at: [https://www.jtcvs.org/article/S2666-2736\(22\)00283-2/fulltext](https://www.jtcvs.org/article/S2666-2736(22)00283-2/fulltext).

thinner and less elastic than the other sinuses, hence inherently more vulnerable and at greater risk of tissue failure.

Alternatively, traumatic manipulation of the Freestyle xenograft, such as pinching of the prosthetic wall, could contribute to its subsequent failure. In our practice, we used to invaginate the Freestyle into the left ventricular outflow tract to facilitate tying of the proximal suture line. In view of the present cases, this practice cannot be recommended anymore.

Finally, a toxic factor could also be incriminated. Indeed, Kazui and colleagues⁷ have reported that BioGlue surgical adhesive might occasionally cause severe injury to aortic tissue, such as excessively thinning of aortic tissue at the site of adhesive application, hence inciting pseudoaneurysm formation.

We underline the importance of additional multidimensional imaging in the follow-up to depict structural aortic abnormalities after Freestyle implantation, insufficiently unveiled by TEE as suggested by Dagnegård and colleagues.⁸

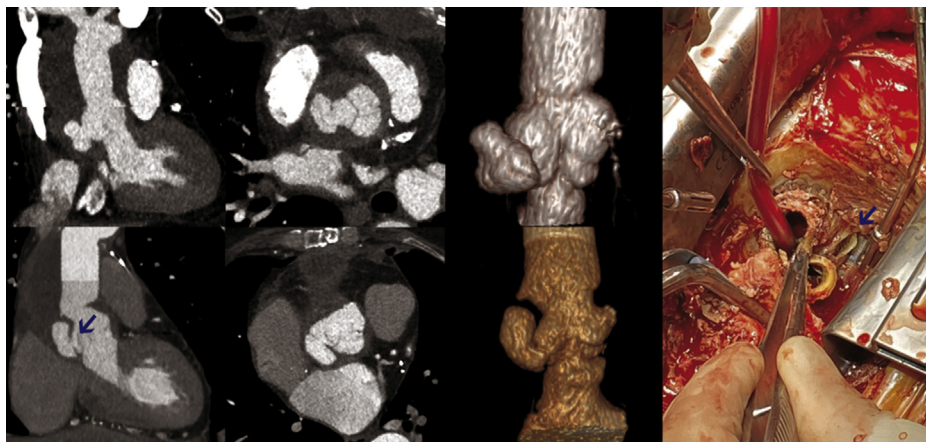


FIGURE 1. Left, Computed tomography and 3-dimensional reconstruction (cases 1 and 2); right, operative image rupture of the noncoronary sinus (case 2, arrow).

TABLE 1. A review of literature in PubMed highlighting 6 cases of noncoronary sinus perforation of the Freestyle Medtronic bioprosthesis

Study	Age, y	Sex	Surgery	Etiology	Time after surgery, mo	CT scan diagnosis	Operative findings	Fenestration site	Reoperation	Infection
Kameda et al ⁵	71	Female	Full root Freestyle + AAR (Dacron)	Aneurysm + AR	15	Aortopulmonary fistula (aortic wall rupture)	2 holes: 3 × 7 mm/3 × 5 mm	Noncoronary sinus	Strengthened with patch and AAR with Dacron graft	No evidence
Ozaki et al ³	63	Male	Full root Freestyle 23 mm	Aneurysm + AR	51	Pseudoaneurysm (aortic wall rupture)	1 hole: 15 × 5 mm	Noncoronary sinus	Full root Freestyle	No evidence
Ozaki et al ³	62	Male	Full root Freestyle 21 mm	Aneurysm + AR	20	Pseudoaneurysm (aortic wall rupture)	1 hole: 15 mm	Noncoronary sinus	Full root Freestyle 21 mm	No evidence
Ozaki et al ³	63	Female	Full root Freestyle 25mm + arch	Aneurysm + AR	17	Pseudoaneurysm (aortic wall rupture)	2 holes: 20 mm	Non-coronary + left sinuses	Full root Freestyle 25 mm	No evidence
Ozaki et al ³	63	Female	Full root Freestyle 25 mm + arch	Bentall redo	20	Pseudoaneurysm (aortic wall rupture)	3 holes: 20 mm	Noncoronary + left sinuses	AVR with CE 23-mm with AAR 28-mm straight graft	No evidence
Kitamura et al ⁶	65	Male	Full root Freestyle 25 mm	Aneurysm + AR	18	Pseudoaneurysm (aortic wall rupture)	1 hole	Noncoronary sinus	Composite graft	No evidence

CT, Computed tomography; AAR, ascending aortic replacement; AR, aortic regurgitation; AVR, aortic valve replacement; CE, Carpentier-Edwards.

CONCLUSIONS

Spontaneous rupture of the NCS constitutes a rare hazard after ARR using the Freestyle xenograft. Atraumatic handling of the bioprosthesis and avoidance of potentially toxic surgical adhesives should be recommended. Meticulous follow-up should be devised to detect this potential complication.

References

- Mohammadi S, Tchana-Sato V, Kalavrouziotis D, Voisine P, Doyle D, Baillet R, et al. Long-term clinical and echocardiographic follow-up of the Freestyle stentless aortic bioprosthesis. *Circulation*. 2012;126(11 suppl 1):S198-204. <https://doi.org/10.1161/CIRCULATIONAHA.111.084806>
- Bach DS, Metras J, Doty JR, Yun KL, Dumesnil JG, Kon ND. Freedom from structural valve deterioration among patients aged < or = 60 years undergoing Freestyle stentless aortic valve replacement. *J Heart Valve Dis*. 2007;16:649-55; discussion 656.

- Ozaki N, Hino Y, Hanafusa Y, Yamashita T, Okada K, Tsukube T, et al. Perforation of the Valsalva sinus after implantation of Medtronic Freestyle aortic bioprosthesis. *Ann Thorac Surg*. 2006;82:2282-5. <https://doi.org/10.1016/j.athoracsur.2006.04.074>
- Takaya H, Masuda S, Naganuma M, Yoshioka I, Takahashi G, Akiyama M, et al. Morphometrical and biomechanical analyses of a stentless bioprosthetic valve: an implication to avoid potential primary tissue failure. *Gen Thorac Cardiovasc Surg*. 2018;66:523-8. <https://doi.org/10.1007/s11748-018-0959-1>
- Kameda Y, Mizuguchi K, Kuwata T, Mori T, Taniguchi S. Aortopulmonary fistula due to perforation of the aortic wall of a freestyle stentless valve. *Ann Thorac Surg*. 2004;78:1827-9. <https://doi.org/10.1016/j.athoracsur.2003.07.025>
- Kitamura A, Handa N, Shomura Y, Wakiyama H, Shinka M, Fujiwara H, et al. Reoperation for early failure of a freestyle bioprosthesis using a full root technique. *J Heart Valve Dis*. 2007;16:275-7.
- Kazui T, Washiyama N, Bashar AH, Terada H, Suzuki K, Yamashita K, et al. Role of biologic glue repair of proximal aortic dissection in the development of early and midterm redissection of the aortic root. *Ann Thorac Surg*. 2001;72:509-14. [https://doi.org/10.1016/s0003-4975\(01\)02777-1](https://doi.org/10.1016/s0003-4975(01)02777-1)
- Dagnegård HSH, Sigvardsen PE, Ihlemann N, Kofoed KF, El-Hamamsy I, Bekke K, et al. Structural abnormalities after aortic root replacement with stemless xenograft. *J Thoracic Cardiovasc Surg*. May 12, 2021 [Epub ahead of print].