

RESEARCH ARTICLE

Age- and sex-specific normative values of bone mineral density in the adult glenoid

Pezhman Eghbali¹ | Fabio Becce²  | Patrick Goetti³  | Frederic Vauclair³ |
Alain Farron³ | Philippe Büchler⁴ | Dominique Pioletti¹ | Alexandre Terrier^{1,3} 

¹Laboratory of Biomechanical Orthopedics, Ecole Polytechnique Fédérale de Lausanne, Lausanne, Switzerland

²Department of Diagnostic and Interventional Radiology, Lausanne University Hospital, University of Lausanne, Lausanne, Switzerland

³Service of Orthopedics and Traumatology, Lausanne University Hospital, University of Lausanne, Lausanne, Switzerland

⁴ARTORG Center for Biomedical Engineering Research, University of Bern, Bern, Switzerland

Correspondence

Alexandre Terrier, Laboratory of Biomechanical Orthopedics, Ecole Polytechnique Fédérale de Lausanne, Station 09, 1015 Lausanne, Switzerland.
Email: alexandre.terrier@epfl.ch

Funding information

Lausanne Orthopedic Research Foundation; Schweizerischer Nationalfonds zur Förderung der Wissenschaftlichen Forschung, Grant/Award Number: 189972

Abstract

The objective of this study was to determine the normative bone mineral density (BMD) of cortical and trabecular bone regions in the adult glenoid and its dependence on the subject's age and sex. We analyzed computed tomography (CT) scans of 441 shoulders (310 males, 18–69 years) without any signs of glenohumeral joint pathology. Glenoid BMD was automatically quantified in six volumes of interest (VOIs): cortical bone (CO), subchondral cortical plate (SC), subchondral trabecular bone (ST), and three adjacent layers of trabecular bone (T1, T2, and T3). BMD was measured in Hounsfield unit (HU). We evaluated the association between glenoid BMD and sex and age with the Student's *t* test and Pearson's correlation coefficient (*r*), respectively. The lambda-mu-sigma method was used to determine age- and sex-specific normative values of glenoid BMD in cortical (CO and SC) and trabecular (ST, T1, T2, and T3) bone. Glenoid BMD was higher in males than females, in most age groups and most VOIs. Before 40 years old, the effect of age on BMD was very weak in both males and females. After 40 years old, BMD declined over time in all VOIs. This BMD decline with age was greater in females (cortical: $r = -0.45$, trabecular: $r = -0.41$) than in males (cortical: $r = -0.30$; trabecular: $r = -0.32$). These normative glenoid BMD values could prove clinically relevant in the diagnosis and management of patients with various shoulder disorders, in particular glenohumeral osteoarthritis and shoulder arthroplasty or shoulder instability, as well as in related research.

KEYWORDS

age, bone mineral density, glenoid, normative values, shoulder

1 | INTRODUCTION

Bone mineral density (BMD) is one of the main components of bone strength, and is classically measured in the lumbar spine and proximal femur. Low BMD has been related to osteoporosis, fracture risk, and osteoarthritis.^{1,2} BMD can be measured in the glenoid and proximal

humerus to identify bone-related disorders in the shoulder, such as osteoporosis.³ Studies have shown that implant fixation in anatomic total shoulder arthroplasty (TSA) was more likely to fail in bones with insufficient BMD.^{4,5} That finding implied that a common TSA complication, aseptic loosening of the glenoid implant, was related to glenoid BMD.⁴

This is an open access article under the terms of the Creative Commons Attribution-NonCommercial-NoDerivs License, which permits use and distribution in any medium, provided the original work is properly cited, the use is non-commercial and no modifications or adaptations are made.

© 2022 The Authors. *Journal of Orthopaedic Research*® published by Wiley Periodicals LLC on behalf of Orthopaedic Research Society.

Bone properties can be measured on cadaveric samples,⁶ or estimated in living patients with clinical imaging techniques, such as dual-energy X-ray absorptiometry (DXA) or quantitative computed tomography (QCT). DXA is still considered the gold standard for the diagnosis of osteoporosis, and is the most commonly utilized technique for BMD assessment.^{7,8} However, it is difficult to obtain structural bone information from DXA, a two-dimensional (2D)/planar technique. In addition, DXA is mainly performed on the lumbar spine and proximal femur; thus, it might over- or underestimate the BMD of the upper limb.^{9,10} In contrast, QCT is three-dimensional (3D)/volumetric and allows geometric measurements, which provide a better representation of bone strength in vivo, based on specific assessments of cortical and trabecular bone.^{11–13} Conventional CT with calibration phantoms can provide BMD measurements by converting CT attenuation numbers (in Hounsfield unit, HU) to volume BMD (in mg/cm³), typically of calcium hydroxyapatite or potassium phosphate.¹⁴

There is a growing clinical interest in studying the impact of BMD of the scapula and especially the glenoid regarding the risk of complications in TSA and glenoid/scapular fracture fixation.¹⁵ Low BMD is related to higher rates of adverse events in joint arthroplasty including intraoperative fractures and secondary implant migration.¹⁶ BMD not only affects^{4,17} glenoid fixation of anatomic TSA implants but also screw fixation strength in the setting of reverse TSA.¹⁸ These two parameters are then related to implant loosening. These parameters are probably also crucial to ensure glenoid screw fixation when dealing with a glenoid fracture or when performing a bone block procedure (e.g., Latarjet or Eden-Hybinette) in older (>40 years) female patients with shoulder instability.^{19,20} Previous studies have measured the glenoid BMD using different methods and in different regions of interest, but only for pathological bone, mainly in glenohumeral osteoarthritis.^{5,21–23} Moreover, while most experimental studies are performed on synthetic bone to ensure comparable bone quality, reference BMD values are awaited to integrate BMD variation in implant evaluation and determine its implication in micro-motion and implant loosening.⁴ Having this information available preoperatively would impact clinical practice by guiding surgeons in selecting the appropriate implant (e.g., anatomic vs. reverse TSA) or performing an additional procedure (e.g., impaction bone grafting or using porous metal augments) to eventually improve patient outcome.^{24,25}

Therefore, the primary objective of our study was to determine normative BMD values in the cortical and trabecular glenoid bone of adult subjects with no signs of glenohumeral joint pathology at imaging. Second, we aimed to assess whether glenoid BMD was associated with the subject's age, sex, height, and weight.

2 | METHODS

2.1 | Subjects

From the picture archiving and communication system of our institution, we retrospectively identified and retrieved whole-body CT scans of trauma patients performed between 2014 and 2018 in

TABLE 1 Number of male and female subjects in each age group

Age group (years)	Males	Females
18–29	124	57
30–39	72	32
40–49	60	23
50–59	32	9
60–69	22	10

the emergency department. Patients were excluded when the CT scan, all reviewed by an attending musculoskeletal radiologist, showed any signs of shoulder pathology (i.e., fracture, dislocation, osteoarthritis, rheumatic disease, cancer, or history of surgery). Incomplete scapular bone coverage (at least one scapula had to be fully included) and a CT protocol deviating from the standardized protocol below were also exclusion criteria. In this way, we obtained 441 CT scans fully including at least one scapula from unique subjects (310 males and 131 females), aged 18–69 years. Subjects were divided into five age groups: 18–29, 30–39, 40–49, 50–59, and 60–69 years (Table 1). The first two groups (18–39 years) were merged and used to calculate normative values. All age groups included more males than females due to the clinical indication for CT (trauma), but the male/female ratio remained almost constant (~2.3) in all age groups, except for the 50–59-year age group, which included fewer females (male/female ratio, 3.6; Table 1, Figure SA1). This retrospective observational study was approved by the institutional ethics committee (CER-VD protocol 2020-01895).

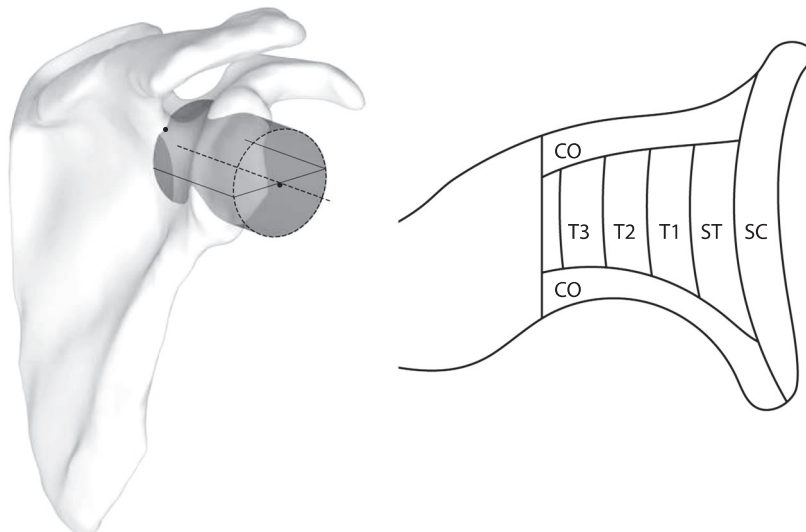
2.2 | CT protocol

Whole-body CT scans were performed on either a 64- (2014–2015) or a 256-detector row (2016–2018) CT system (Light Speed VCT or Revolution CT; GE Healthcare). The relevant standardized data acquisition parameters were, as follows: tube potential, 120 kVp; tube current, ~150–400 mA; automatic exposure control, enabled; gantry revolution time: 0.5–0.6 s. The relevant parameters for image reconstruction were: field of view, 32 × 32–40 × 40 cm²; section thickness, 1.25 mm.

2.3 | Glenoid BMD

Glenoid BMD was measured in six volumes of interest (VOIs; Figure 1), determined using a specific method based on scapular bone landmarks and bone segmentation with statistical shape modeling and local template matching.^{5,17,26} From these landmarks, we defined our regional coordinate system: x-axis as posterior-anterior, y-axis as inferior-superior, and z-axis as the medial-lateral axis of the scapula.²⁷ In the present study, the VOIs were obtained in a fully automated manner.^{28,29} The six glenoid bone VOIs were: cortical bone (CO),

FIGURE 1 Glenoid bone mineral density (BMD) was measured in HU within the voxels included in a cylinder adjusted to include the entire glenoid fossa (left). This cylinder was segmented into six adjacent 3-mm-thick volumes of interests (VOIs) (right): cortical bone (CO), subchondral cortical plate (SC), subchondral trabecular bone (ST), and three successive layers of trabecular bone (T1, T2, and T3)



subchondral cortical plate (SC), subchondral trabecular bone (ST), and three successive adjacent layers of trabecular bone (T1, T2, and T3). All these VOIs were defined within a cylinder centered on the glenoid vault and aligned with the medial-lateral scapular axis. The cylinder height was 40 mm and its diameter was adjusted to include the entire glenoid vault. We selected 40 mm to ensure that the glenoid vault was completely included in the cylinder, based on an estimate of a series of 20 cases from the initial study.¹⁷ The medial base of the cylinder was positioned at the spinoglenoid notch.⁵ Within this cylinder, voxels representing bone mineral tissue were segmented using a lower threshold of 300 HU.³⁰ We determined trabecular bone by shrinking this initial segmented bone volume of a fixed 3-mm-thick outer shell. Conversely, cortical bone was obtained by keeping only the volume of the outer shell. Within cortical bone, we defined SC within a fixed 3-mm-thick spherical shell fitted on the glenoid fossa, and CO as all remaining cortical bone. Adjacent and medial to SC, ST then T1–T3 were defined as successive 3-mm-thick spherical layers within trabecular bone. BMD was measured in each shell/VOI, based on the average CT numbers in HU. In addition, we considered the average CT numbers in the cortical (CO and SC) and trabecular (ST, T1, T2, and T3) bone. The BMD measurement was not considered when a VOI volume was less than 27 (i.e., 3³) mm³, and the average trabecular BMD was not considered when all trabecular VOI volumes were below this threshold.

2.4 | Statistical analysis

The dependence of the glenoid BMD on the subject's sex was assessed within each VOI for all age groups with the unpaired (two-tailed) Student's *t* test. The association between glenoid BMD and the subject's age was evaluated with the Pearson's correlation coefficient (*r*).³¹ We reported *p*-values and 95% confidence intervals (95% CI) where appropriate. We used the lambda-mu-sigma method to calculate age- and sex-specific normative BMD curves (z-scores) of

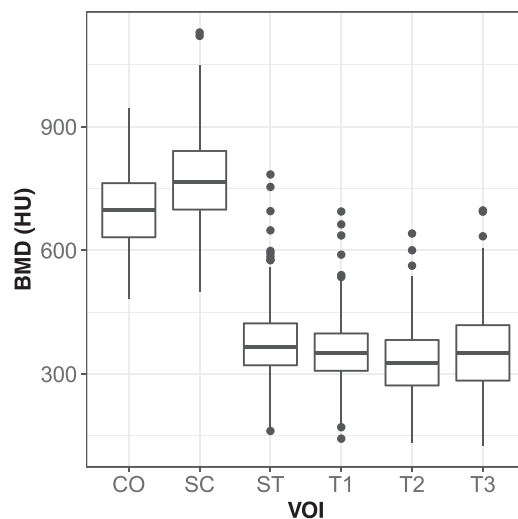


FIGURE 2 Glenoid bone mineral density (BMD) in each of the six volumes of interests (VOIs), for all subjects (males and females) and age groups together. CO, cortical bone; SC, subchondral cortical plate; ST, subchondral trabecular bone

glenoid BMD in cortical (CO and SC) and trabecular (ST, T1, T2, and T3) bone VOIs.³² These normative glenoid BMD values were expressed as the median, with 5th and 95th percentiles. In addition, we assessed associations between the glenoid BMD and body height and weight. The normal distribution of the data was verified with the Shapiro–Wilk test. All statistical analyses were performed with R 4.0 (www.r-project.org).

3 | RESULTS

In all subjects, the glenoid BMD was approximately twice as high in the two cortical bone VOIs compared with the four trabecular bone VOIs ($p < 0.0001$; Figures 2 and 3, Tables 2 and S1). Among subjects

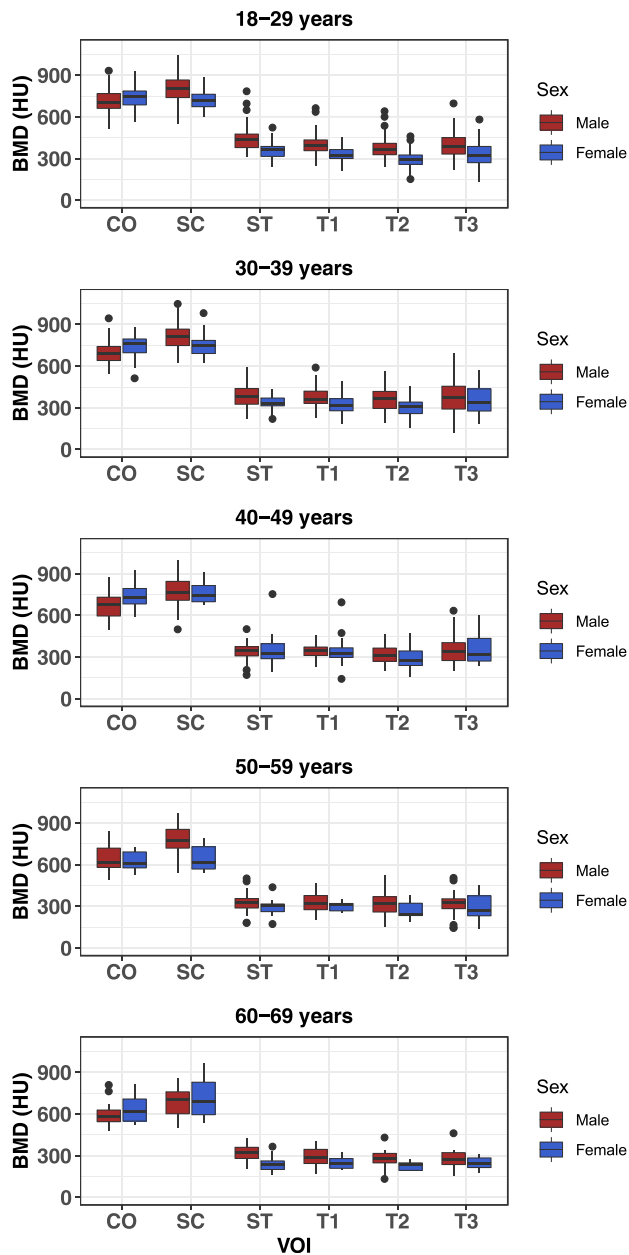


FIGURE 3 Glenoid bone mineral density (BMD) in each of the six volumes of interests (VOIs), for males and females, by increasing age group. CO, cortical bone; SC, subchondral cortical plate; ST, subchondral trabecular bone

under 40 years old, the BMD showed some sex dependence (Figure 3, Tables 2 and S1). In the 18-29-year age group, BMD was sex-dependent in the two cortical VOIs. In the 18-29-year and 30-39-year age groups, BMD was sex-dependent in all four trabecular VOIs. Accordingly, we analyzed males and females separately. The glenoid BMD was slightly higher in males than in females for most VOIs and age groups (Figure 3, Tables 2 and S1). However, the BMD was nearly independent of the subject's height and weight in both males and females (Table 3).

In males, the mean cortical BMD was 758 HU in the 18-29-year age group, and 754 HU in the 30-39-year age group (Figures 3 and 4,

Table 2). The mean trabecular BMD was 400 HU in the 18-29-year age group, and 374 HU in the 30-39-year age group. In females, the mean cortical BMD was 731 HU in the 18-29-year age group, and 745 HU in the 30-39-year age group. The mean trabecular BMD was 329 HU in the 18-29-year age group, and 330 HU in the 30-39-year age group.

Among males, the glenoid BMD was not correlated with age before 40 years old, in both cortical ($r=0.02$) and trabecular ($r=-0.17$) bone. The BMD declined at a slightly faster rate after the age of 40, in both cortical ($r=-0.30$) and trabecular ($r=-0.32$) bone (Figures 3 and 4, Tables 2 and 3). Among females, the BMD was not correlated with age before 40 years old, in either cortical ($r=0.04$) or trabecular ($r=0.05$) bone. However, after 40 years old, BMD was moderately negatively correlated with age, and the correlations were stronger in women than in men, in both cortical ($r=-0.45$) and trabecular ($r=-0.41$) bone (Table 4).

4 | DISCUSSION

We determined the normative BMD values of cortical and trabecular bone regions in the adult glenoid, and evaluated their dependence on the subject's age and sex. In all glenoid bone regions considered here, we found that BMD depended on sex in all age groups. The age dependence was more evident after 40 years old, particularly among females. Glenoid BMD declined with age more rapidly among females than among males, and this effect was more pronounced in the trabecular than in the cortical bone.

Over the last decade, primary glenohumeral osteoarthritis, cuff tear arthropathy, and shoulder instability have all been reported to affect glenoid BMD distribution.^{22,23,33-35} However, a thorough understanding of normal glenoid BMD and its distribution (in relation to age, sex, and anatomical location) are important because only comparison with normative data will allow to determine how BMD distribution increased (as suggested by Wolff's law) or conversely decreased secondary to cavitation or unloading.³⁶ Current recommendations regarding implant orientation preclude a uniform BMD distribution; corrective glenoid bone reaming, however, expose the implant to potentially lower BMD and therefore compromise initial fixation strength.^{37,38} This would benefit both anatomic and reverse TSA as it would not only guide reaming depth and orientation but also further improve peripheral screw placement and/or implant design.^{22,37}

Here, we considered CT numbers, expressed in HU, as a surrogate for BMD, as previously described.^{22,39,40} Indeed, to calculate bone density, the x-ray attenuation information is converted into bone mineral density, based on phantom-based calibration, tissue-based calibration, or dual-energy CT. These techniques have been used to determine BMD in the spine and the hip/femur.⁴¹⁻⁴⁵ Several studies have also investigated the glenoid BMD with CT. However, most of the previously reported values were obtained from a limited number of pathological shoulders. In contrast, in the present study, we used a fully automatic method, based on the

TABLE 2 Glenoid BMD in cortical and trabecular bone, for males and females, by increasing age group

	Age group (years)	Males		Females		Mean difference (HU), 95% CI (HU)	p-value
		Mean ± SD (HU)	Median ± IQR (HU)	Mean ± SD (HU)	Median ± IQR (HU)		
Cortical BMD	18-29	758 ± 81	760 ± 106	731 ± 57	728 ± 84	27, [7-48]	0.009
	30-39	754 ± 70	760 ± 77	745 ± 69	758 ± 82	9, [-21 to 37]	0.585
	40-49	717 ± 84	734 ± 97	754 ± 70	756 ± 120	-37, [-73 to 0]	0.048
	50-59	713 ± 87	711 ± 143	639 ± 74	626 ± 133	74, [11-136]	0.023
	60-69	642 ± 79	654 ± 116	676 ± 117	650 ± 202	-34, [-122 to 54]	0.417
Trabecular BMD	18-29	400 ± 69	391 ± 88	329 ± 57	321 ± 68	71, [52-90]	<0.0001
	30-39	374 ± 80	374 ± 102	330 ± 66	328 ± 94	44, [14-74]	0.005
	40-49	336 ± 56	337 ± 77	341 ± 113	319 ± 109	-5, [-56 to 46]	0.844
	50-59	326 ± 72	318 ± 92	291 ± 49	291 ± 47	35, [-9 to 77]	0.111
	60-69	287 ± 62	293 ± 79	239 ± 43	223 ± 61	48, [9-87]	0.019

Abbreviations: BMD, bone mineral density; CI, confidence interval; HU, Hounsfield unit; SD, standard deviation.

TABLE 3 Pearson's correlation coefficient (r) between glenoid BMD, in cortical and trabecular bone, and the subject's age, height, and weight, for males and females and before and after 40 years old

		Males		Females	
		Age <40 years	Age ≥40 years	Age <40 years	Age ≥40 years
Cortical BMD	Age (years)	0.02	-0.30	0.04	-0.45
	Height (cm)	-0.08	0.08	0.06	0.06
	Weight (kg)	-0.11	0.19	-0.27	-0.12
Trabecular BMD	Age (years)	-0.17	-0.32	0.05	-0.41
	Height (cm)	0.09	0.18	0.00	-0.02
	Weight (kg)	0.10	0.31	0.19	-0.01

Abbreviation: BMD, bone mineral density.

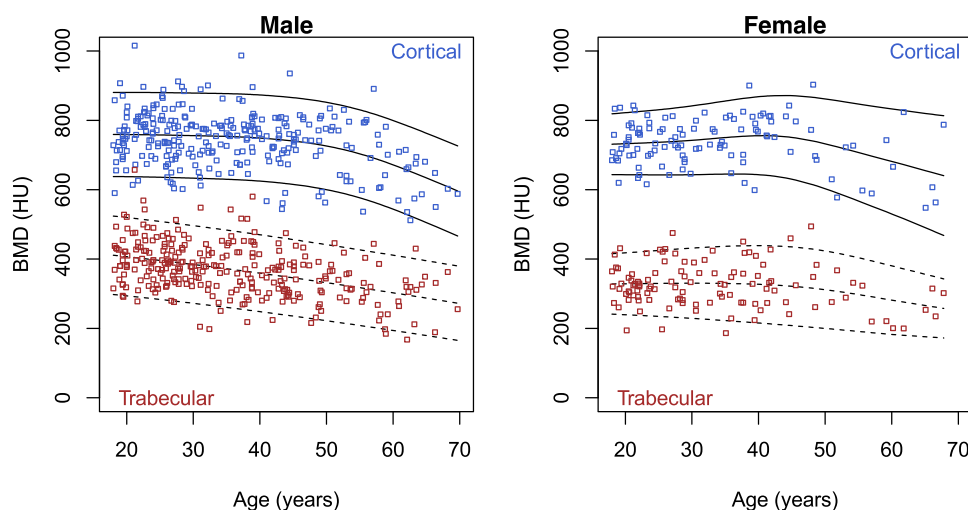
**FIGURE 4** Variation of glenoid bone mineral density (BMD) as a function of age, in cortical and trabecular bone, for males and females. The solid lines correspond to 5th, the median (50%) and the 95th percentiles for cortical BMD, and the dashed lines for trabecular BMD

TABLE 4 Pearson's correlation coefficient (*r*) with [95% CI] between glenoid BMD and the subject's age (after 40 years old), for males and females and in each of the six VOIs

	CO	SC	ST	T1	T2	T3
Males	-0.29 [-0.45 to -0.11]	-0.25 [-0.42 to -0.07]	-0.19 [-0.37 to -0.01]	-0.34 [-0.50 to -0.17]	-0.28 [-0.44 to -0.10]	-0.27 [-0.45 to -0.08]
Females	-0.51 [-0.71 to -0.25]	-0.30 [-0.55 to 0.00]	-0.40 [-0.63 to -0.11]	-0.41 [-0.64 to -0.12]	-0.38 [-0.62 to -0.07]	-0.36 [-0.64 to 0.00]

Abbreviations: BMD, bone mineral density; CI, confidence interval; CO, cortical bone; SC, subchondral cortical plate; ST, subchondral trabecular bone; VOIs, volumes of interests.

initial semi-automated method proposed by Terrier et al. In that study, Terrier et al. quantified glenoid BMD, in the same six VOIs that we studied, in 20 patients that had been scheduled to undergo TSA.¹⁷ The method was later used by Mariaux et al. on 93 patients with glenohumeral osteoarthritis (age range, 45–88 years) that were also scheduled to undergo TSA.⁵ In comparing the same age group, their mean HU values for pathological shoulders were very similar to our normative values, in the CO, T1, T2, and T3 regions, but they found lower values (103 HU) in the SC and higher values (149 HU) in the ST regions. The values they found in pathological shoulders showed greater variability (overall measurement range of ~100–840 HU for trabecular and ~390–890 HU for cortical bone) than our measurements in healthy shoulders (overall measurement range of ~200–600 HU for trabecular and ~500–950 HU for cortical bone).

Unlike the two studies mentioned above, the method we used in the present study was fully automatic; it was based on statistical shape modeling and local template matching.^{28,29} However, differences between the previous semi-automated method and the fully automatic method used here (evaluated on 154 cases) were negligible (root mean square error = 39 HU; average difference = 0.3 HU).

An extended comparison of our results with those previously reported in the literature was difficult for two main reasons. First, a comprehensive analysis of the glenoid bone in nonpathological subjects is lacking; therefore, a direct comparison was not possible. Second, methods and VOIs used varied widely among the available studies. Couteau et al. characterized bone density variation in 20 glenoid regions in patients with three different pathologies, including rotator cuff tears (15 subjects), primary glenohumeral osteoarthritis (13 subjects), and rheumatoid arthritis (4 subjects).⁴⁶ Compared with our findings, their results showed that HU declined as age increased, in cases with rotator cuff pathology (age range: <20 to >70 years), but the mean HUs in all regions were lower than the means found in the present study. In contrast, their subjects with primary glenohumeral osteoarthritis tended to show an increase in HUs with increasing age, in subjects 45 to >70 years. Moreover, in subjects under 60 years old, their reported average HU was lower (almost 300) than the average HU found here (almost 516, averaged over all VOIs in the 50–59-year age group). However, in patients over 60 years old, their mean HU was almost the same as the mean HU found here, in the same age group (nearly 460). Recently, Telfer et al. evaluated the scapular bone density variation by region and its association with sex and age for 93 CT of non-pathologic subjects.¹⁵

They reported higher bone loss per year for females compared with males which were similar to our findings. Moreover, they showed the acromion, scapular spine, coracoid base, inferior glenoid neck, and glenoid vault regions to be significantly age affected and the scapular spine and body to be significantly sex affected.

Kraljević et al. evaluated differences in bone mineralization between the glenoid fossa and the humeral head in 57 cadaveric shoulders with the CT-osteoborptiometry technique.⁴⁷ However, that analysis was limited to the subchondral bone plate, and they reported patterns, rather than absolute values. Thus, a direct comparison with our results was not possible. In another study, the CT-osteoborptiometry technique was used to evaluate subchondral mineralization patterns, which were related to cartilage thickness and the radius of the glenoid curvature.⁴⁸ Those results were also difficult to compare with our values. However, our observations were consistent with findings in a recent study that evaluated the dependence of BMD on sex and age in 54 donors, based on statistical shape models and density models.⁴⁹ They reported that the mean scapular bone density was higher among males than females, and it was inversely correlated with age.

The strength and novelty of this study were that we provided normative BMD values for the adult glenoid, based on a comparatively large data set. We evaluated adult males and females separately and covered a wide age range. We reported the normative BMD values in six different glenoid VOIs and assessed cortical and trabecular bones separately. Furthermore, we tested associations between these normative BMDs and sex, age, height, and weight.

One of the main limitations of our study was the relatively small number of female subjects over 40 years old. Thus, for that age group, the average BMD values might have been less accurate. Another limitation was the fixed thickness (3 mm) used to define the cortical and subchondral bone VOIs. Indeed, the thicknesses of these regions may vary locally, and among subjects. However, this constant thickness was visually acceptable for most subjects, and it allowed objective comparisons. We evaluated this selection of 3-mm thickness for VOIs with the percentage of cortical bone volume included within each VOI (i.e., percentage of voxels with CT numbers \geq 600 HU, as used in previous studies³⁴) (Figure SA6). In the trabecular bone, this percentage was relatively low, as expected. In the cortical bone, this percentage value might seem lower than expected. However, for this study, we had to either fix the thickness of the cortical bone layer/VOI and evaluate its content, or fix the

threshold (in HU) of the cortical bone layer/VOI and evaluate its thickness. For the sake of simplicity and to facilitate interindividual comparison, we opted to fix the thickness of the cortical bone and of all other VOIs. The value of 3 mm was chosen as the best compromise between the thin cortical layer of the glenoid fossa, and the thicker cortical layer toward the lateral aspect (both anterior and posterior) of the glenoid vault. To assess the effect of this choice, we compared the results obtained with this fixed thickness of 3 mm to those obtained with 2.5 mm, as used by Knowles et al.,³⁴ and 2 mm (Figure SA6). For CO, there were no significant differences between these three thicknesses. In ST, 2 mm might seem a better choice; however, this resulted in higher cortical bone included in ST. In all trabecular VOIs (ST and T1–T3), there was a lower percentage of cortical bone included in the measurements with 3 mm.

We determined the normative BMD values of cortical and trabecular bone regions in the adult glenoid and their dependence on the subject's age and sex. These reference values could prove clinically useful in the diagnosis and management of patients with various shoulder disorders, in particular glenohumeral osteoarthritis and shoulder arthroplasty or shoulder instability, as well as in related research.

AUTHOR CONTRIBUTIONS

Conceptualization: Fabio Becce, Alain Farron, and Alexandre Terrier. **Methodology:** Pezhman Eghbali and Alexandre Terrier. **Statistics:** Pezhman Eghbali and Alexandre Terrier. **Collecting Data:** Fabio Becce, Patrick Goetti, and Alain Farron. **Draft Preparation:** Pezhman Eghbali and Alexandre Terrier. **Supervision:** Fabio Becce, Patrick Goetti, Frederic Vaclair, Alain Farron, and Alexandre Terrier. **Reviewing and Editing:** Fabio Becce, Patrick Goetti, Frederic Vaclair, Alain Farron, Philippe Büchler, Dominique Pioletti, and Alexandre Terrier.

ACKNOWLEDGMENTS

This study was supported by the Swiss National Science Foundation (SNF 189972) and the "Lausanne Orthopedic Research Foundation" (LORF). Open access funding provided by Ecole Polytechnique Federale de Lausanne.

CONFLICTS OF INTEREST

The authors declare no conflicts of interest.

ORCID

Fabio Becce  <http://orcid.org/0000-0001-8444-8504>

Patrick Goetti  <http://orcid.org/0000-0001-7243-2118>

Alexandre Terrier  <http://orcid.org/0000-0002-1910-0701>

REFERENCES

- Shah VN, Harrall KK, Shah CS, et al. Bone mineral density at femoral neck and lumbar spine in adults with type 1 diabetes: a meta-analysis and review of the literature. *Osteoporos Int.* 2017;28(9):2601-2610.
- Kanis JA, Melton LJ, Christiansen C, Johnston CC, Khaltaev N. The diagnosis of osteoporosis. *J Bone Miner Res.* 1994;9(8):1137-1141.
- Mather J, MacDermid JC, Faber KJ, Athwal GS. Proximal humerus cortical bone thickness correlates with bone mineral density and can clinically rule out osteoporosis. *J Shoulder Elbow Surg.* 2013;22(6):732-738.
- Chamseddine M, Breden S, Pietschmann MF, Müller PE, Chevalier Y. Periprosthetic bone quality affects the fixation of anatomic glenoids in total shoulder arthroplasty: in vitro study. *J Shoulder Elbow Surg.* 2019;28(1):e18-e28.
- Mariaux S, Obrist R, Farron A, Becce F, Terrier A. Is preoperative glenoid bone mineral density associated with aseptic glenoid implant loosening in anatomic total shoulder arthroplasty? *BMC Musculoskelet Disord.* 2021;22(1):49.
- Mansat P, Barea C, Hobatho M-C, Darmana R, Mansat M. Anatomic variation of the mechanical properties of the glenoid. *J Shoulder Elbow Surg.* 1998;7(2):109-115.
- Morgan SL, Prater GL. Quality in dual-energy X-ray absorptiometry scans. *Bone.* 2017;104:13-28.
- Lewiecki EM, Binkley N, Morgan SL, et al. Best practices for dual-energy x-ray absorptiometry measurement and reporting: International Society for Clinical Densitometry Guidance. *J Clin Densitom.* 2016;19(2):127-140.
- Wilson J, Bonner TJ, Head M, Fordham J, Brealey S, Rangan A. Variation in bone mineral density by anatomical site in patients with proximal humeral fractures. *J Bone Joint Surg.* 2009;91-B(6):772-775.
- Handa A, Uchiyama Y, Shinpuku E, Watanabe M. Comparison of three plain radiography methods for evaluating proximal humerus bone strength in women. *J Orthop Sci.* 2019;24(2):243-249.
- Khoo BC, Brown K, Cann C, et al. Comparison of QCT-derived and DXA-derived areal bone mineral density and T scores. *Osteoporos Int.* 2009;20(9):1539-1545.
- Mayhew PM, Thomas CD, Clement JG, et al. Relation between age, femoral neck cortical stability, and hip fracture risk. *Lancet.* 2005;366(9480):129-135.
- Engelke K, Mastmeyer A, Bousson V, Fuerst T, Laredo JD, Kalender WA. Reanalysis precision of 3D quantitative computed tomography (QCT) of the spine. *Bone.* 2009;44(4):566-572.
- Earp BE, Kallini JR, Collins JE, Benavent KA, Tintle SM, Rozental TD. Correlation of Hounsfield unit measurements on computed tomography of the shoulder with DXA scan and FRAX scores: a potential for opportunistic screening. *Journal of Orthopaedic Trauma.* 2021;35:384-390. https://journals.lww.com/jorthotrauma/Abstract/9000/Correlation_of_Hounsfield_Unit_Measurements_on.98126.aspx
- Telfer S, Kleweno CP, Hughes B, et al. Changes in scapular bone density vary by region and are associated with age and sex. *J Shoulder Elbow Surg.* 2021;30:2839-2844. <https://www.sciencedirect.com/science/article/pii/S105827462100478X>
- Russell LA. Osteoporosis and orthopedic surgery: effect of bone health on total joint arthroplasty outcome. *Curr Rheumatol Rep.* 2013;15(11):371.
- Terrier A, Obrist R, Becce F, Farron A. Cement stress predictions after anatomic total shoulder arthroplasty are correlated with preoperative glenoid bone quality. *J Shoulder Elbow Surg.* 2017;26(9):1644-1652.
- Stroud NJ, DiPaola MJ, Martin BL, et al. Initial glenoid fixation using two different reverse shoulder designs with an equivalent center of rotation in a low-density and high-density bone substitute. *J Shoulder Elbow Surg.* 2013;22(11):1573-1579.
- Moroder P, Stefanitsch V, Auffarth A, Matis N, Resch H, Plachel F. Treatment of recurrent anterior shoulder instability with the Latarjet or Bristow procedure in older patients. *J Shoulder Elbow Surg.* 2018;27(5):824-830.
- Wessel LE, Eliasberg CD, Bowen E, Sutton KM. Shoulder and elbow pathology in the female athlete: sex-specific considerations. *J Shoulder Elbow Surg.* 2021;30(5):977-985.

21. Knowles NK, G Langohr GD, Faioghi M, Nelson A, Ferreira LM. Development of a validated glenoid trabecular density-modulus relationship. *J Mech Behav Biomed Mater.* 2019;90:140-145.
22. Letissier H, Chaoui J, Bercik MJ, et al. Glenoid subchondral bone density in osteoarthritis: a comparative study of asymmetric and symmetric erosion patterns. *Orthop Traumatol: Surg Res.* 2020;106(6):1127-1134.
23. Simon P, Gupta A, Pappou I, et al. Glenoid subchondral bone density distribution in male total shoulder arthroplasty subjects with eccentric and concentric wear. *J Shoulder Elbow Surg.* 2015;24(3):416-424.
24. Pervaiz K, Cabezas A, Downes K, Santoni BG, Frankle MA. Osteoporosis and shoulder osteoarthritis: incidence, risk factors, and surgical implications. *J Shoulder Elbow Surg.* 2013;22(3):e1-e8.
25. Elhassan B, Ozbaydar M, Higgins LD, Warner JJP. Glenoid reconstruction in revision shoulder arthroplasty. *Clin Orthop Relat Res.* 2008;466(3):599-607.
26. Terrier A, Obrist R, Malfroy Camine V, Becce F, Farron A. Biomechanical comparison of glenoid implants with adaptable and fixed backside curvatures in anatomic total shoulder arthroplasty. *J Shoulder Elbow Surg.* 2018;27(9):1656-1663.
27. Terrier A, Ston J, Larrea X, Farron A. Measurements of three-dimensional glenoid erosion when planning the prosthetic replacement of osteoarthritic shoulders. *Bone Joint J.* 2014;96-B(4):513-518.
28. Taghizadeh E, Terrier A, Becce F, Farron A, Büchler P. Automated CT bone segmentation using statistical shape modelling and local template matching. *Comput Methods Biomech Biomed Engin.* 2019;22(16):1303-1310.
29. Abler D, Berger S, Terrier A, Becce F, Farron A, Büchler P. A statistical shape model to predict the pre-morbid glenoid cavity. *J Shoulder Elbow Surg.* 2018;27(10):1800-1808.
30. Fullerton GD, White DR. Anthropomorphic test objects for CT scanners. *Radiology.* 1979;133(1):217-222.
31. Mukaka MM. Statistics corner: a guide to appropriate use of correlation coefficient in medical research. *Malawi Med J.* 2012;24(3):69-71.
32. Cole T. The LMS method for constructing normalized growth standards. *Eur J Clin Nutr.* 1990;44:45-60.
33. Mahaffy MD, Knowles NK, Berkmortel C, et al. Density distribution of the type E2 glenoid in cuff tear arthropathy. *J Shoulder Elbow Surg.* 2020;29(1):167-174.
34. Knowles NK, Athwal GS, Keener JD, Ferreira LM. Regional bone density variations in osteoarthritic glenoids: a comparison of symmetric to asymmetric (type B2) erosion patterns. *J Shoulder Elbow Surg.* 2015;24(3):425-432.
35. Schulz CU, Anetzberger H, Pfahler M, Refior HJ, Müller-Gerbl M. Anterior shoulder instability modifies glenoid subchondral bone density. *Clin Orthop Relat Res.* 2004;423:259-263.
36. Wolf JH. Julius Wolff and his "law of bone remodeling". *Orthopade.* 1995;24:378-386.
37. Chen X, Reddy AS, Kontaxis A, et al. Version correction via eccentric reaming compromises remaining bone quality in B2 glenoids: a computational study. *Clin Orthop Relat Res.* 2017;475(12):3090-3099.
38. Goetti P, Denard PJ, Collin P, Ibrahim M, Mazzolari A, Lädermann A. Biomechanics of anatomic and reverse shoulder arthroplasty. *EFORT Open Rev.* 2021;6(10):918-931.
39. Schreiber JJ, Anderson PA, Rosas HG, Buchholz AL, Au AG. Hounsfield units for assessing bone mineral density and strength: a tool for osteoporosis management. *J Bone Joint Surg Am.* 2011;93(11):1057-1063.
40. Jun B-J, Vasanji A, Ricchetti ET, et al. Quantification of regional variations in glenoid trabecular bone architecture and mineralization using clinical computed tomography images. *J Orthop Res.* 2018;36(1):85-96.
41. Bauer JS, Henning TD, Müller D, Lu Y, Majumdar S, Link TM. Volumetric quantitative CT of the spine and hip derived from contrast-enhanced MDCT: conversion factors. *AJR Am J Roentgenol.* 2007;188(5):1294-1301.
42. Cataño Jimenez S, Saldarriaga S, Chaput CD, Giambini H. Dual-energy estimates of volumetric bone mineral densities in the lumbar spine using quantitative computed tomography better correlate with fracture properties when compared to single-energy BMD outcomes. *Bone.* 2020;130:115100.
43. Kuperus JS, Samsour L, Buckens CF, Oner FC, de Jong PA, Verlaan JJ. Bone mineral density changes over time in diffuse idiopathic skeletal hyperostosis of the thoracic spine. *Bone.* 2018;112:90-96.
44. El Maghraoui A, Ghazi M, Gassim S, et al. Bone mineral density of the spine and femur in a group of healthy Moroccan men. *Bone.* 2009;44(5):965-969.
45. Su Y-B, Wang L, Wu X-B, et al. The spatial differences in bone mineral density and hip structure between low-energy femoral neck and trochanteric fractures in elderly Chinese using quantitative computed tomography. *Bone.* 2019;124:62-68.
46. Couteau B, Mansat P, Mansat M, Darmana R, Egan J. In vivo characterization of glenoid with use of computed tomography. *J Shoulder Elbow Surg.* 2001;10(2):116-122.
47. Kraljević M, Zumstein V, Hügli R, Müller-Gerbl M. A comparison of subchondral bone mineralization between the glenoid cavity and the humeral head on 57 cadaverous shoulder joints. *Surg Radiol Anat.* 2013;35(4):295-300.
48. Zumstein V, Kraljević M, Müller-Gerbl M. Glenohumeral relationships: subchondral mineralization patterns, thickness of cartilage, and radii of curvature. *J Orthop Res.* 2013;31(11):1704-1707.
49. Soltanmohammadi P, Elwell J, Veeraraghavan V, Athwal GS, Willing R. Investigating the effects of demographics on shoulder morphology and density using statistical shape and density modeling. *J Biomech Eng.* 2020;142(12):121005. doi:10.1115/1.4047664

SUPPORTING INFORMATION

Additional supporting information can be found online in the Supporting Information section at the end of this article.

How to cite this article: Eghbali P, Becce F, Goetti P, et al. Age- and sex-specific normative values of bone mineral density in the adult glenoid. *J Orthop Res.* 2023;41:263-270. doi:10.1002/jor.25379