

## CASE REPORT

## Columnar cuff cancer after restorative proctocolectomy for familial adenomatous polyposis

H Vuilleumier, N Halkic, R Ksontini, M Gillet

### Abstract

**Aims**—Restorative proctocolectomy with ileoanal anastomosis is one of the treatments of choice for patients suffering from familial adenomatous polyposis (FAP). However, any residual rectal mucosa left behind after mucosectomy is at risk for the development of neoplasia.

**Case report**—A 31 year old male patient with FAP underwent restorative proctocolectomy with a pelvic ileal pouch-anal anastomosis. Seven years later he presented with right inguinal and perianal pain. A diagnosis of invasive columnar cuff carcinoma was made.

**Discussion**—Islets of columnar epithelium may be left behind after restorative proctocolectomy, exposing the patient to later malignant change. This risk must be emphasised and prevented by regular surveillance of the anastomosis.

(Gut 2000;47:732-734)

Keywords: familial adenomatous polyposis; anastomosis; adenocarcinoma

Familial adenomatous polyposis (FAP) is an autosomal dominant disease characterised by development of multiple adenomatous polyps in the large bowel. Except for the restricted phenotype, one or more of these adenomas may develop into cancer unless prophylactic measures are undertaken.<sup>1 2</sup> Restorative proctocolectomy is one of the treatments of choice. It should be reserved for patients at a higher risk of rectal cancer and those with uncontrollable adenomas.<sup>3 4</sup>

After double stapled restorative proctocolectomy there is a cuff of diseased colorectal mucosa remaining in the upper anal canal above the anal transitional zone (ATZ). According to Thompson-Fawcett *et al*, this is suitably termed the columnar cuff.<sup>5</sup> The columnar cuff is defined as the retained columnar epithelium between the upper border of the ATZ below, and the pouch-anal anastomosis above, usually the colorectal-type mucosa present in the anal canal.<sup>5</sup> Acknowledgement of a retained 1.5–2.0 cm columnar cuff of diseased mucosa is important for follow up after restorative proctocolectomy.<sup>5-9</sup>

Two cases of FAP developing an invasive columnar cuff adenocarcinoma eight and 20 years after restorative proctocolectomy have been described in the literature.<sup>1 2</sup> We report here a new case of late malignant change at the ileal pouch-anal anastomosis (IPAA), seven years after total proctocolectomy for FAP.

### Case report

A 31 year old man presented with FAP in 1990. There was no family history of either FAP or colorectal cancer. Total proctocolectomy and construction of a J pouch were carried out in another institution. In accordance with the operative protocol, the J pouch was built by firing a linear stapler (Auto Suture GIA-90 disposable stapler; United States Surgical Corporation, Norwalk, Connecticut 06856, USA) twice on a loop of terminal ileum. The pouch was anastomosed to the anus using a circular stapler (Auto Suture Premium Plus CEEA 28 mm disposable stapler; United States Surgical Corporation). Mucosectomy was not performed. Several polyps lying above the dentate line were removed by electrocautery. Histology of the resected specimen showed numerous tubular adenomas, some with moderate to severe dysplasia. The “doughnuts” produced by the stapler also contained multiple fragments of tubulovillous adenomatous polyps with moderate to severe dysplasia. However, the risk of late malignant change was thought to be minimal and there was no follow up of the ileoanal anastomosis.

In March 1997, the patient presented with increasing pain in the right lower quadrant and right inguinal region. A few weeks later the pain was localised to the perianal region, with occasional radiation to the posterior right thigh. Ileoscopy, abdominal computed tomography (CT) scan, and barium follow through performed in April 1997 did not detect any abnormality. There was subsequent exacerbation of the anal and inguinal pain. In August 1997, the pain became intolerable and the

**Abbreviations used in this paper:** FAP, familial adenomatous polyposis; IPAA, ileal pouch-anal anastomosis; ATZ, anal transitional zone; CT, computed tomography; MRI, magnetic resonance imaging.

Department of  
Surgery, University  
Hospital,  
Lausanne-CHUV,  
Switzerland  
H Vuilleumier  
N Halkic  
R Ksontini  
M Gillet

Correspondence to:  
Dr H Vuilleumier, Service de  
Chirurgie, Centre Hospitalier  
Universitaire Vaudois, 1011  
Lausanne-CHUV,  
Switzerland. Email:  
henri.vuilleumier@  
chuv.hospvd.ch

Accepted for publication  
8 February 2000

patient received antidepressant treatment after trying several times to commit suicide.

We first saw this patient in September 1997. Because of the anal pain, the rectal digital examination could only be performed under general anaesthesia. The examination revealed induration of the right lateral wall at the level of the ileoanal anastomosis. The mucosa appeared normal. On ultrasound, the rectal wall was heterogeneous. Carcinoembryonic antigen level was 23.2 ng/ml. A diagnosis of a moderately differentiated partly necrotised adenocarcinoma was made on a Tru-cut biopsy.

The lesion was further evaluated by barium enema which showed extrinsic compression of the right lateral wall at the level of the ileoanal anastomosis with proximal dilatation of the J pouch. CT scan and magnetic resonance imaging (MRI) of the abdomen and pelvis displayed a 9×8×6 cm heterogeneous mass extending from the top of the sacrum to the tip of the coccyx, and laterally towards the right obturator canal (fig 1). At exploratory laparotomy, a large pelvic tumour was found arising from the ileoanal anastomosis and involving the bladder, prostate, and seminal vesicles, and protruding towards the right

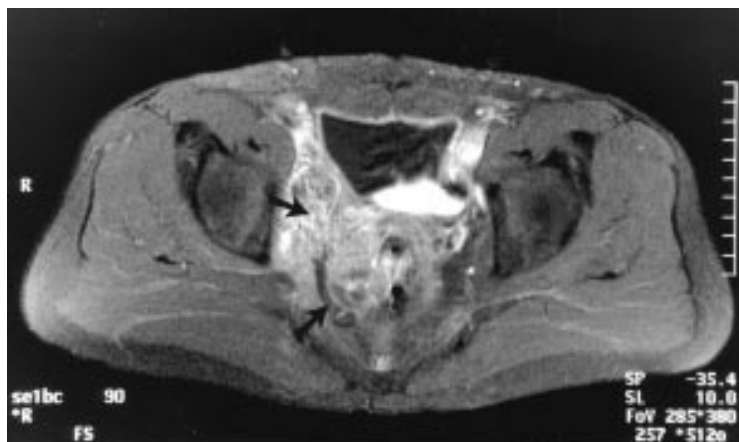


Figure 1 Magnetic resonance image showing extrinsic compression of the ileal pouch (arrows) with distention of the proximal bowel.

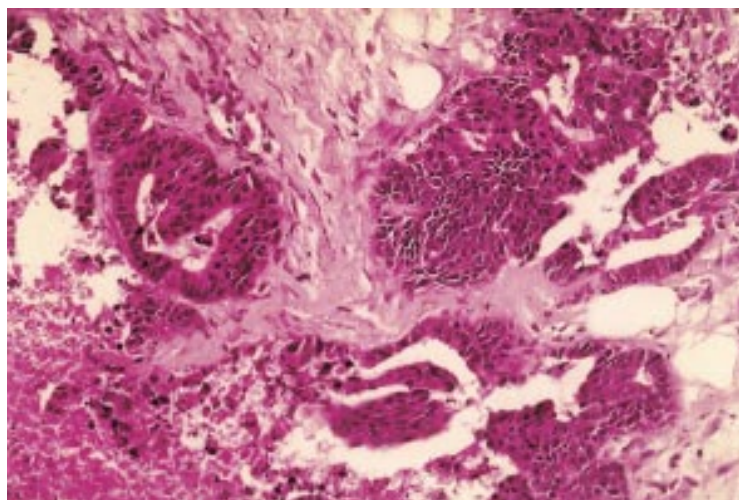


Figure 2 Invasive adenocarcinoma within the pouch wall (Tru-cut biopsy; haematoxylin and eosin, original magnification ×100).

obturator foramen. Resection of the J pouch and a permanent ileostomy were performed. Histology showed an invasive adenocarcinoma of the rectal type, infiltrating the pouch wall (fig 2). The ileal mucosa was normal.

The postoperative course was characterised by unbearable pain localised to the anal canal and in the right groin. The patient even attempted to commit suicide during his hospital stay. Thereafter, he was transferred to the neurosurgical department where a thoracic cordotomy was successfully performed. The patient died 12 months later of disseminated carcinomatosis.

## Discussion

We report here the third patient with FAP to develop invasive columnar cuff carcinoma after restorative proctocolectomy.<sup>1,2</sup> The cancer arose from residual rectal mucosa left behind after a stapled IPAA. The doughnuts produced by the stapler contained multiple fragments of tubulovillous adenomatous polyps with moderate to severe dysplasia. Unfortunately, the risk of late malignant change was at that time thought to be minimal and there was no follow up of the ileoanal anastomosis.

Restorative proctocolectomy with ileoanal pouch anastomosis is one of the recognised treatments for FAP.<sup>1,2</sup> Currently, a double stapled IPAA is the standard procedure in most cases. This technique is easier to perform than a hand sewn IPAA with mucosectomy. There is debate concerning the question of preservation of the so-called ATZ when forming a pouch-anal anastomosis. Some argue it should be retained because of the functional advantage it brings, while others argue it should be removed because of the long term risk of neoplasia and inflammation.<sup>5,10</sup>

Keighley *et al* found no difference in clinical function between those patients who did or did not undergo mucosectomy.<sup>10</sup> Choen-Seow *et al* reported no difference between hand sewn ileoanal pouch anastomosis and stapled IPAA without mucosectomy in their prospective trial.<sup>11</sup>

The ATZ is much smaller than commonly thought; it extends 4–5 mm above the dentate line and beyond this there is columnar epithelium. The columnar cuff is defined as the retained columnar epithelium between the upper border of the ATZ below, and the pouch-anal anastomosis above. After a double stapled restorative proctocolectomy, a 1.5–2.0 cm cuff of columnar epithelium is retained in the upper anal canal above the ATZ. This is an important concept for follow up after IPAA.<sup>5</sup>

Regardless of the anastomosis technique in restorative proctocolectomy (hand sewn or stapled), mucosectomy should be performed in patients with FAP. However, mucosectomy should never be deemed complete as residual mucosal islands are known to persist after mucosectomy in 20% of cases.<sup>12–15</sup> Therefore, close endoscopic follow up of the pouch and columnar cuff with biopsies is warranted because of the possible late malignant change.

- 1 von Herbay A, Stern J, Herfarth C. Pouch-anal cancer after restorative proctocolectomy for familial adenomatous polyposis. *Am J Surg Pathol* 1996;20:995-9.
- 2 Hoehner JC, Metcalf AM. Development of invasive adenocarcinoma following colectomy with ileoanal anastomosis for familial polyposis coli. Report of a case. *Dis Colon Rectum* 1994;37:824-8.
- 3 Nugent KP, Phillips RKS. Rectal cancer risk in older patients with familial adenomatous polyposis and an ileorectal anastomosis: a cause for concern. *Br J Surg* 1992;79:1204-6.
- 4 De Cosse JJ, Bulow S, Neale K, et al. Rectal cancer risk in patients treated for familial adenomatous polyposis. The Leeds Castle Polyposis Group. *Br J Surg* 1992;79:1372-5.
- 5 Thompson-Fawcett MW, Warren BF, Mortensen NJMcC. A new look at the anal transitional zone with reference to restorative proctocolectomy and the columnar cuff. *Br J Surg* 1998;85:1517-21.
- 6 Wiltz O, Hashmi HF, Schoetz DJJ, et al. Carcinoma and the ileal pouch-anal anastomosis. *Dis Colon Rectum* 1991;34:805-9.
- 7 Stern H, Walfisch S, Mullen B, McLeod R, Cohen Z. Cancer in an ileoanal reservoir: a new late complication? *Gut* 1990;31:473-5.
- 8 Taylor BA, Wolff BG, Dozois RR, Kelly KA, Pemberton JH, Beart RW. Ileal pouch-anal anastomosis for chronic ulcerative colitis and familial polyposis coli complicated by adenocarcinoma. *Dis Colon Rectum* 1988;31:358-62.
- 9 Ziv Y, Fazio VW, Sirimarco MT, Lavery IC, Goldblum JR, Petras RE. Incidence, risk factors, and treatment of dysplasia in the anal transitional zone after ileal pouch-anal anastomosis. *Dis Colon Rectum* 1994;37:1281-5.
- 10 Keighley MRB, Winslet MC, Yoshioka K, Lightwood R. Discrimination is not impaired by excision of the anal transition zone after restorative proctocolectomy. *Br J Surg* 1987;74:1118-21.
- 11 Choen S, Tsunoda A, Nicholls RJ. Prospective randomized trial comparing anal function after hand sewn ileoanal anastomosis with mucosectomy versus stapled ileoanal anastomosis without mucosectomy in restorative proctocolectomy. *Br J Surg* 1991;78:430-4.
- 12 Sequens R. Cancer in the anal canal (transitional zone) after restorative proctocolectomy with stapled ileal pouch-anal anastomosis. *Int J Colorectal Dis* 1997;12:254-5.
- 13 Heppell J, Weiland LH, Perrault J, Pemberton JH, Telander RL, Beart RW. Fate of the rectal mucosa after rectal mucosectomy and ileoanal anastomosis. *Dis Colon Rectum* 1983;26:768-71.
- 14 O'Connell PR, Pemberton JH, Weiland LH, et al. Does rectal mucosa regenerate after ileoanal anastomosis? *Dis Colon Rectum* 1987;30:1-5.
- 15 O'Connell PR, Williams NS. Mucosectomy in restorative proctocolectomy. *Br J Surg* 1991;78:129-30.