

# About the performance of multi-dimensional radial self-navigation incorporating compressed sensing for free-breathing coronary MRI

Gabriele Bonanno<sup>1,2</sup>, Gilles Puy<sup>3,4</sup>, Yves Wiaux<sup>3,5</sup>, Ruud B. van Heeswijk<sup>1,2</sup>, and Matthias Stuber<sup>1,2</sup>

<sup>1</sup>Department of Radiology, University Hospital (CHUV) and University of Lausanne, Lausanne, Vaud, Switzerland, <sup>2</sup>Center for Biomedical Imaging (CIBM), Lausanne, Vaud, Switzerland, <sup>3</sup>Institute of Electrical Engineering, École Polytechnique Fédérale de Lausanne (EPFL), Lausanne, Vaud, Switzerland, <sup>4</sup>Institute of the Physics and Biological Systems, École Polytechnique Fédérale de Lausanne (EPFL), Lausanne, Vaud, Switzerland, <sup>5</sup>Institute of Bioengineering, École Polytechnique Fédérale de Lausanne (EPFL), Lausanne, Vaud, Switzerland

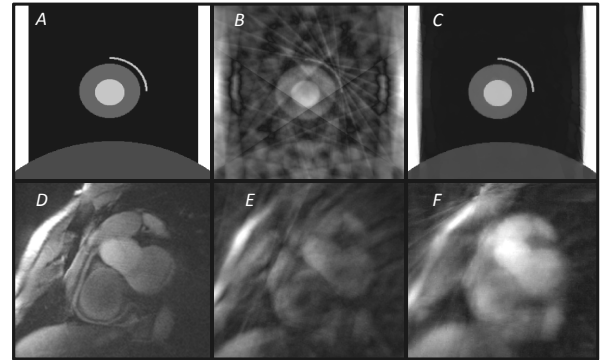
**Introduction:** Respiratory motion is a major challenge in cardiac magnetic resonance imaging (MRI) and contemporary state-of-the-art motion compensation strategies like diaphragmatic navigators still suffer from sub-optimal time efficiency. In response, *k*-space-based one-dimensional self-navigation techniques have recently been developed that extract respiratory-induced motion of the heart directly from the imaging data themselves for subsequent motion correction on a beat-to-beat basis [1]. This affords the advantage of 100% scan efficiency while meticulous plan scanning and navigator placement can be avoided. In the present study, this concept was advanced to the next level by implementing an image-based self-navigation technique that incorporates compressed sensing and allowing for multi-dimensional motion correction. The new approach was investigated using computer simulations of a moving heart phantom before it was implemented on a 3T human scanner. In 12 healthy adult human subjects, the performance of this methodology was then quantitatively ascertained in comparison to free-breathing coronary MRI, both with and without conventional respiratory navigators.

**Materials and Methods:** To estimate motion parameters, under-sampled sub-images were collected during each cardiac cycle and co-registered to a reference sub-image. In-plane displacement parameters were then extracted for each heartbeat before they were applied for motion correction in *k*-space. A computer simulation that mimics cardiac and liver anatomy with superimposed cardiac and respiratory motion was implemented in MATLAB (The Mathworks, Natick, MA, USA). Motion patterns and signal intensity levels were borrowed from conventional coronary MRI *in vivo* data. Sub-image reconstruction was then simulated using A) a non-linear Total-Variation-based reconstruction [4,5], that is related to compressed sensing, and B) a conventional method [2]. The displacement values extracted from these sub-images were then compared to the ground truth using linear correlation. Furthermore, these same displacement parameters were exploited for motion correction of each individual sub-image. *K*-space data from all these motion-corrected sub-images were ultimately combined for final image reconstruction. The identical reconstruction pipeline was used for offline processing of the *in vivo* data obtained at 3T (Siemens Trio, Erlangen, Germany) and in 12 healthy adult subjects. Segmented 2D radial gradient-echo image data of the RCA were acquired during free breathing with ECG triggering only (320 samples per projection, 364 projections in *k*-space, 24 interleaves, 15 projections per interleave, 320matrix, 320x320mm FoV, 1x1x8mm spatial resolution, TR/TE=8.9/4.2ms, TE<sub>T2prep</sub>=50ms, α=15°) and resulted in images that were corrupted by respiratory motion. Subsequently, these images were also retrospectively corrected with the above-described self-navigation technique (Self-NAV). In each subject, images were additionally acquired with a diaphragmatic respiratory navigator (4mm gating window) for reference standard comparison (NAV). Scan time as well as scan efficiency were compared for the Self-NAV and NAV acquisitions. Quantitative image analysis was then performed on all motion corrupted, self-navigated, and navigated images using the Soap-Bubble tool [6]. SNR of the blood pool, CNR between the blood pool and the myocardium, average vessel diameter and vessel sharpness (%VS) were obtained for comparison. For statistical analyses, a paired two-tailed Student's *t*-test was used and *p* < .05 was considered statistically significant after Bonferroni correction for multiple comparisons.

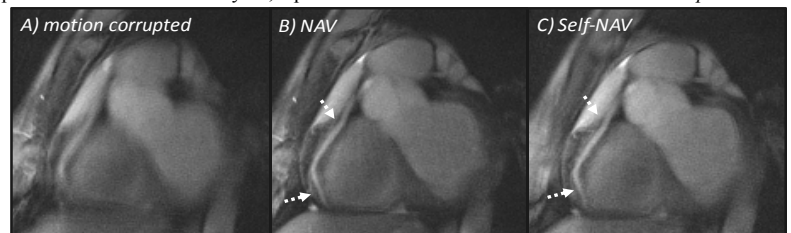
**Results and Discussion:** Using the numerical simulation, significant streaking artifacts were observed on the sub-images that were generated using the conventional reconstruction (Fig.1B). This adversely affected motion estimation as demonstrated by a modest correlation between the actual and the measured displacement ( $R^2=0.89$ ). In contrast, non-linear reconstruction yielded sub-images in which the anatomy was better defined (Fig.1C) and motion estimation substantially improved ( $R^2=0.99$ ). This is consistent with the findings on the corresponding *in vivo* sub-images in Fig.1E and 1F, where the non-linear reconstruction leads to a higher signal from the heart while streaking artifacts are reduced. Based on these results, Self-NAV with compressed sensing was used for *in vivo* acquisitions and compared to the conventional NAV. In a representative *in vivo* coronary MR image (Fig.2) after motion correction (Fig.2C), an improved visual delineation of the RCA is obtained with Self-NAV (compared to motion corrupted, Fig.2A) and the image quality approaches that of the reference standard (NAV, Fig.2B). Accordingly the %VS (Fig.3) is significantly improved with Self-NAV (motion-corrupted vs. Self-NAV: 24.2±4 vs. 29.8±4.7, *p*<0.005). By comparison, conventional navigator gating still leads to the highest vessel sharpness (35±5.5, *p*<0.001 vs. motion corrupted, *p*<0.005 vs. Self-NAV) but suffers from a low scan efficiency (34.3±9%) and long scanning time (NAV vs. Self-NAV: 72.9±26s vs. 23±3.4s, *p*<0.001). SNR of the blood pool, CNR and average diameter did not show significant differences among the three techniques (*p*=NS). Residual artifacts on self-navigated coronary MRI may be explained by the fact that motion correction is applied to the entire image including the stationary structures. While self-navigation accounts for the displacement of the moving structures as a result of respiration, this same reconstruction may still introduce some motion artifacts originating from static structures such as the chest wall.

**Conclusion:** We have developed and tested a new image-based self-navigation approach that exploits non-linear reconstruction for multi-dimensional motion-correction in free-breathing coronary MRI. Motion correction parameters are directly extracted from the sub-images while avoiding the need for a motion model or navigator planning. In a computer simulation, the accuracy of motion estimation was significantly higher with this technique when compared to that obtained with conventional reconstruction. *In vivo* and in humans, Self-NAV improved %VS significantly by 25% relative to the motion corrupted images. When comparing NAV and Self-NAV, scanning time for Self-NAV was reduced by 50% while its %VS was 14% lower. SNR, CNR or vessel diameter measurements remained unchanged between the two techniques.

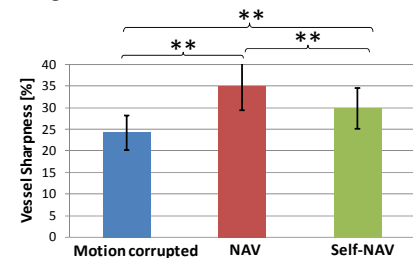
**References:** 1.Stehning et al.MRM(2005)54,2:476 2.McLeish et al.MRM(2004)52,5:1127 3.Jackson et al.IEEE-TMI(1991)10:473 4.Beck et al,IEEE-TIP(2009)18:2419 5.Combettes et al.IEEE-JSTSP(2007)1,4:564 6.Etienne et al.,MRM(2002)48,4:658



**Figure 1 – In vitro sub-images.** A) Original image. B) Sub-image reconstructed with the conventional method. C) Sub-image reconstructed with the non-linear method. **In vivo sub-images.** D) Representative targeted RCA from NAV acquisition. E) Sub-image reconstructed with the conventional approach. F) Sub-image reconstructed with the non-linear method.



**Figure 2 – In vivo result: right coronary artery.** A) Motion corrupted image without any motion correction. B) state-of-the-art NAV acquisition. C) Self-NAV corrected acquisition for which coronary delineation (dotted arrows) and overall image quality approaches the one in B) albeit with a 2-fold accelerated scanning time.



**Figure 3 – Vessel sharpness.** Self-NAV consistently increases vessel sharpness when compared to the motion corrupted acquisition. NAV shows higher vessel sharpness at the expense of prolonged scan times. \*\*=*p*<0.005, after Bonferroni correction.