

Neurology[®]

Rituximab is successful in an HIV-positive patient with MuSK myasthenia gravis

T. Kuntzer, A. Carota, J. Novy, et al.

Neurology 2011;76;757-758

DOI 10.1212/WNL.0b013e31820d6290

This information is current as of February 21, 2011

The online version of this article, along with updated information and services, is located on the World Wide Web at:

<http://www.neurology.org/content/76/8/757.full.html>

Neurology® is the official journal of the American Academy of Neurology. Published continuously since 1951, it is now a weekly with 48 issues per year. Copyright Copyright © 2011 by AAN Enterprises, Inc.. All rights reserved. Print ISSN: 0028-3878. Online ISSN: 1526-632X.



T. Kuntzer, MD
 A. Carota, MD
 J. Novy, MD
 M. Cavassini, MD
 R.A. Du Pasquier, MD

RITUXIMAB IS SUCCESSFUL IN AN HIV-POSITIVE PATIENT WITH MuSK MYASTHENIA GRAVIS

There exists almost no literature on how to treat myasthenia gravis (MG) in HIV-infected patients. We report a 21-year-old HIV+ African woman (A3 Centers for Disease Control and Prevention staging) who developed a bulbar form of MG concomitant with significant CD4+ T-cell increase on highly active antiretroviral therapy (HAART) and who was eventually successfully treated by rituximab.

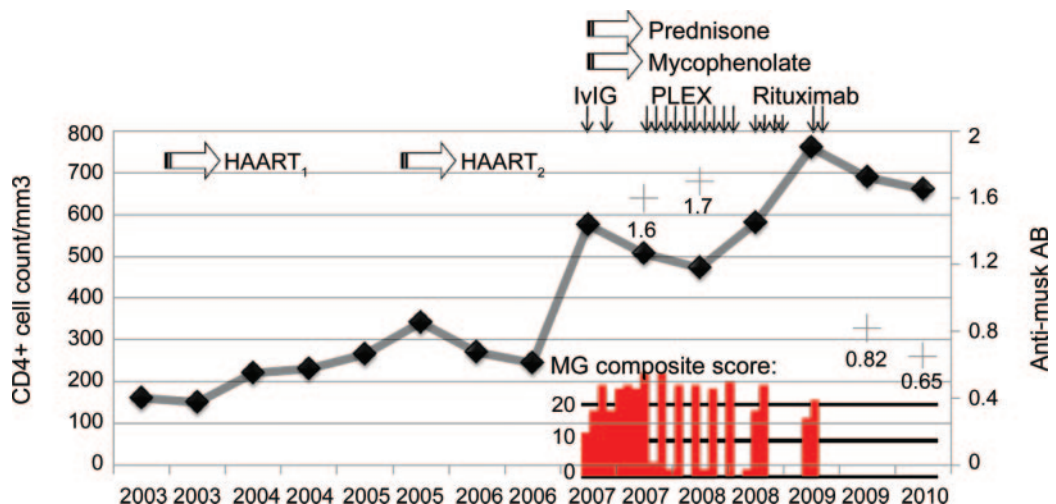
This case report provides Class IV evidence that treatment with IV rituximab (2 cycles of 1 g each) was associated with improvement in clinical signs of MG in an HIV-positive patient with MuSK MG.

Case report. In April 2003, the patient started HIV treatment with zidovudine, lamivudine, and efavirenz. Although HIV viral load became undetectable, immune restoration was slow. In 2005, zidovudine was switched to tenofovir. Within 8 months, she showed a marked increase (235%) in CD4+ lymphocyte cell count (from 244 to 575/mm³) (figure). Concomitant with this count peak, the patient presented with intermittent diplopia, eyelid ptosis, dysarthria, dysphagia, and fatigue in the

upper limbs (MG composite score; figure). Clinical examination revealed lymphadenopathy, symmetric ptosis, weakness, and fatigability involving the facial, pharyngeal, palatal, tongue, neck, shoulder abductor, and respiratory muscles. A 3-Hz repetitive facial nerve stimulation showed a significant decrement at 34% (normal <10%). Anti-acetylcholine receptor (AChR) antibodies were absent but antibodies against muscle-specific tyrosine kinase (MuSK) were positive at 1.6 nmol/L (normal <0.05 nmol/L), establishing the diagnosis of MuSK-MG.

Routine blood tests, serum immunity markers, and serum anti-toxoplasma, varicella zoster virus, herpes simplex virus, and cytomegalovirus antibodies were normal or negative. Pyridostigmine, prednisone, and thymectomy (without histologic abnormalities) did not alter the clinical course over the following 12 months. The response to IV immunoglobulin infusions was poor but plasma exchange (PLEX, 3 or 5 exchanges) improved the bulbar symptoms dramatically, but for less than 10 days. At 1-year follow-up, anti-MuSK antibodies showed similar serum titles, despite therapy with prednisone (0.5 mg/kg/day), mycophenolate mofetil (1 g/day),

Figure Evolution of clinical and laboratory findings over time



Left scale: CD4+ T-cell count; right scale: anti-MuSK antibody title (+, normal <0.05 nmol/L). HAART = highly active antiretroviral therapy (2 when zidovudine was switched to tenofovir, see text); IVIg = IV immunoglobulin; PLEX = plasma exchange.

and 3 PLEX on a bimonthly basis. In January 2009, 4 weekly IV cycles of 375 mg/m² of rituximab were administered and a clear clinical improvement was documented within 10 days, followed by a rapid motor worsening following the next 2 weeks, causing PLEX to be resumed. It was decided to administrate 2 additional cycles of 1 g of rituximab on a 2-week interval. Shortly after the second infusion, the patient improved, with a complete regression of all her neurologic signs. At the time of manuscript submission, 11 months later, she was in good health and had no abnormal signs, and was on usual HAART, prednisone 5 mg qd, and mycophenolate mofetil (1 g qd). HIV viral load was undetectable, CD4⁺ T cells were at 660/μL, B-cell count (CD20⁺) was 3/μL, and anti-MuSK antibodies were 0.65 nmol/L.

Discussion. Our case presents several salient features. First, we describe the initial HIV-infected patient with MuSK-MG who improved with rituximab. The few patients with MG who were also HIV⁺ reported so far had a milder course, and only one had MuSK-MG.¹ Small series in HIV-negative patients presenting with refractory MG have suggested that rituximab was beneficial.² Thus, our patient responding only to PLEX, we opted for rituximab, a choice that was decisive in her improvement, suggesting that the overall treatment approach for MuSK-MG is likely to be similar regardless of HIV status.

Second, our observation may provide some insights on the poorly known pathogenesis of MuSK-MG. Indeed, the disease became manifest concomitantly with a marked increase in CD4⁺ T cells, suggesting these cells may play a triggering role in the disease. Supporting this hypothesis, an HIV⁺ patient with AChR-MG improving in parallel with the progression of HIV infection and consequent CD4⁺ T-lymphocyte reduction has been reported.³

Third, although we cannot rule out that HIV infection and MuSK-MG occurred coincidentally, HIV frequently causes autoimmune dysregulation with loss of self tolerance and increased autoimmunity.⁴ A dysfunction in regulatory T cells may also have been at play. Indeed, this phenomenon has been observed in HIV⁻ patients with MG,⁵ as well as in HIV⁺ patients with immune reconstitution inflammatory syndrome (IRIS).⁶ Our patient presented some IRIS features, i.e., a brisk increase in the CD4⁺ T-cell count and symptoms consistent with an inflammatory process. Regardless of whether this patient had IRIS, the brisk rise in CD4⁺ T cells, possibly associated with a dysfunction of regulatory

T cells, was likely instrumental in unmasking the MuSK-MG. Rituximab may have been crucial not only by decreasing the secretion of pathogenic autoantibodies, but also by impeding autoantigen presentation by B cells to T cells.⁷

From the Service of Neurology (T.K., A.C., J.N., R.A.D.P.), Department of Clinical Neurosciences, and the Services of Immunology and Allergy (R.A.D.P.) and Infectious Diseases (M.C.), Department of Internal Medicine, Lausanne University Hospital CHUV, Lausanne, Switzerland; and Hildebrand Clinic (A.C.), Rehabilitation Center, Brissago, Switzerland.

Disclosure: Dr. Kuntzer serves on scientific advisory boards for Société Française de Myologie and Société Francophone du Nerf Périphérique; and serves on the editorial boards of the Journal of the Peripheral Nervous System, Neurophysiologie clinique/Clinical Neurophysiology, and Swiss Archives of Neurology and Psychiatry. Dr. Carota and Dr. Novy report no disclosures. Dr. Cavassini has received funding for travel from Abbott, Boehringer Ingelheim, Gilead Sciences, Inc. and Roche; and serves on the editorial board of Revue Médicale Suisse. Dr. Du Pasquier serves on scientific advisory boards for Biogen Idec, Merck Serono, and Novartis; has received funding for travel or speaker honoraria from Biogen Idec, Sanofi-Aventis, Merck Serono, and Bayer Schering Pharma; serves on the editorial boards of the European Journal of Neurology and the Journal of Neurovirology; and receives research support from the Swiss National Foundation, the Swiss Society for Multiple Sclerosis, and the Biaggi Foundation.

Received March 15, 2010. Accepted in final form August 31, 2010.

Address correspondence and reprint requests to Dr. Thierry Kuntzer, Neurology Service, CHUV, 1011 Lausanne, Switzerland; thierry.kuntzer@chuv.ch

Copyright © 2011 by AAN Enterprises, Inc.

1. Kurokawa T, Nishiyama T, Yamamoto R, Kishida H, Hakii Y, Kuroiwa Y. [Anti-MuSK antibody positive myasthenia gravis with HIV infection successfully treated with cyclosporin: a case report.] *Rinsho Shinkeigaku* 2008;48:666–669.
2. Stieglbauer K, Topakian R, Schaffer V, Aichner FT. Rituximab for myasthenia gravis: three case reports and review of the literature. *J Neurol Sci* 2009;280:120–122.
3. Nath A, Kerman RH, Novak IS, Wolinsky JS. Immune studies in human immunodeficiency virus infection with myasthenia gravis: a case report. *Neurology* 1990;40:581–583.
4. Krupica T Jr, Fry TJ, Mackall CL. Autoimmunity during lymphopenia: a two-hit model. *Clin Immunol* 2006;120:121–128.
5. Masuda M, Matsumoto M, Tanaka S, et al. Clinical implication of peripheral CD4(+)CD25(+) regulatory T cells and Th17 cells in myasthenia gravis patients. *J Neuroimmunol Epub* 2010 May 14.
6. Seddiki N, Sasson SC, Santner-Nanan B, et al. Proliferation of weakly suppressive regulatory CD4⁺ T cells is associated with over-active CD4⁺ T-cell responses in HIV-positive patients with mycobacterial immune restoration disease. *Eur J Immunol* 2009;39:391–403.
7. Cross AH, Stark JL, Lauber J, Ramsbottom MJ, Lyons JA. Rituximab reduces B cells and T cells in cerebrospinal fluid of multiple sclerosis patients. *J Neuroimmunol* 2006;180:63–70.

Rituximab is successful in an HIV-positive patient with MuSK myasthenia gravis

T. Kuntzer, A. Carota, J. Novy, et al.

Neurology 2011;76;757-758

DOI 10.1212/WNL.0b013e31820d6290

This information is current as of February 21, 2011

Updated Information & Services	including high resolution figures, can be found at: http://www.neurology.org/content/76/8/757.full.html
References	This article cites 6 articles, 1 of which you can access for free at: http://www.neurology.org/content/76/8/757.full.html##ref-list-1
Subspecialty Collections	This article, along with others on similar topics, appears in the following collection(s): Class IV http://www.neurology.org/cgi/collection/class_iv HIV http://www.neurology.org/cgi/collection/hiv Myasthenia http://www.neurology.org/cgi/collection/myasthenia
Permissions & Licensing	Information about reproducing this article in parts (figures, tables) or in its entirety can be found online at: http://www.neurology.org/misc/about.xhtml#permissions
Reprints	Information about ordering reprints can be found online: http://www.neurology.org/misc/addir.xhtml#reprintsus

