UNIVERSITE DE LAUSANNE - FACULTE DE BIOLOGIE ET DE MEDECINE

Département des services de chirurgie et d'anesthésiologie

Division d'ORL et de chirurgie cervico-faciale

Analysis of functional and anatomical success following endonasal dacryocystorhinostomy

THESE

préparée sous la direction du Professeur Philippe Monnier
(avec la collaboration du Dr. Jean Paul Friedrich et Dr. Jean-Jacques Tritten)

et présentée à la Faculté de biologie et de médecine de
l'Université de Lausanne pour l'obtention du grade de

DOCTEUR EN MEDECINE

par

Barbara Friederike ZÜRCHER

Médecin diplômée de la République fédérale d'Allemagne
Originaire de Karlsruhe / Allemagne

Lausanne

2011

UNIL | Université de Lausanne
Faculté de biologie
et de médecine

Ecole Doctorale
Doctorat en médecine

Imprimatur

Vu le rapport présenté par le jury d'examen, composé de

Directeur de thèse	*Monsieur le Professeur* **Philippe Monnier**
Co-Directeur de thèse	
Expert	
Directrice de l'Ecole doctorale	*Madame le Professeur* **Stephanie Clarke**

la Commission MD de l'Ecole doctorale autorise l'impression de la thèse de

Madame Barbara Zürcher

intitulée

Analysis of functional and anatomical success following endonasal dacryocystorhinostomy

Lausanne, le 23 septembre 2011

pour Le Doyen
de la Faculté de Biologie et de Médecine

Madame le Professeur Stephanie Clarke
Directrice de l'Ecole doctorale

Résumé

Les sténoses des voies lacrymales sont fréquentes surtout chez les patients âgés et provoquent en général un epiphora avec parfois des dacryocystites aigues ou chroniques. La dacryocystorhinostomie par voie externe (DCREX) a été la technique de choix pour traiter les sténoses post-canaliculaires au XXe siècle. Avec l'avènement de l'endoscopie nasale, l'abord endonasal est devenu facilement accessible et depuis une dizaine d'années, la dacryocystorhinostomie par voie endonasale (DCREN) est en train de supplanter la DCREX dans la majorité des cas.

Le but de ce travail est de déterminer les étiologies des sténoses des voies lacrimales, d'évaluer le taux de succès et les complications de la DCREN et de détailler les gestes associés peropératoires.

Cette étude rétrospective porte sur 98 patients ayant subi 104 DCREN entre janvier 1994 et février 2006. 78 patients (53 femmes et 25 hommes) présentant 84 sténoses post-canaliculaires remplissent les critères d'inclusion de l'étude. L'âge moyen est de 59 ans (4 – 89 ans).

Les résultats obtenus montrent un taux de succès fonctionnel de 94.9% après une première intervention (59/84 DCREN) et de 63.6% pour les DCREN secondaires qui nous ont été référées après d'autres interventions des voies lacrymales (25/84 DCREN). Le suivi postopératoire est de 36,8 mois (12-77 mois). On dénombre 61 gestes rhino-sinusaux associés à la DCREN. Les complications per- et postopératoires sont rares, essentiellement liées aux drains bicanaliculaires. Une étiologie n'a été retrouvée que dans 28% des cas.

En conclusion, la DCREN donne d'excellents résultats et peu de complications. En raison des nombreux avantages par rapport à la voie externe et la possibilité du traitement simultané de la pathologie ORL parfois associée, la DCREN est devenue le traitement de premier choix pour les sténoses postcanaliculaires. Le principal défi, quelque soit le type de DCR, est de poser la bonne indication opératoire et en cas d'échec opératoire savoir méticuleusement analyser ses causes

Résumé

Les sténoses des voies lacrymales sont fréquentes surtout chez les patients âgés et provoquent en général un epiphora avec parfois des dacryocystites aigues ou chroniques. La dacryocystorhinostomie par voie externe (DCREX) a été la technique de choix pour traiter les sténoses post-canaliculaires au XXe siècle. Avec l'avènement de l'endoscopie nasale, l'abord endonasal est devenu facilement accessible et depuis une dizaine d'années, la dacryocystorhinostomie par voie endonasale (DCREN) est en train de supplanter la DCREX dans la majorité des cas.

Le but de ce travail est de déterminer les étiologies des sténoses des voies lacrimales, d'évaluer le taux de succès et les complications de la DCREN et de détailler les gestes associés peropératoires.

Cette étude rétrospective porte sur 98 patients ayant subi 104 DCREN entre janvier 1994 et février 2006. 78 patients (53 femmes et 25 hommes) présentant 84 sténoses post-canaliculaires remplissent les critères d'inclusion de l'étude. L'âge moyen est de 59 ans (4 – 89 ans).

Les résultats obtenus montrent un taux de succès fonctionnel de 94.9% après une première intervention (59/84 DCREN) et de 63.6% pour les DCREN secondaires qui nous ont été référées après d'autres interventions des voies lacrymales (25/84 DCREN). Le suivi postopératoire est de 36,8 mois (12-77 mois). On dénombre 61 gestes rhino-sinusaux associés à la DCREN. Les complications per- et postopératoires sont rares, essentiellement liées aux drains bicanaliculaires. Une étiologie n'a été retrouvée que dans 28% des cas.

En conclusion, la DCREN donne d'excellents résultats et peu de complications. En raison des nombreux avantages par rapport à la voie externe et la possibilité du traitement simultané de la pathologie ORL parfois associée, la DCREN est devenue le traitement de premier choix pour les sténoses postcanaliculaires. Le principal défi, quelque soit le type de DCR, est de poser la bonne indication opératoire et en cas d'échec opératoire savoir méticuleusement analyser ses causes

1093-120-D

Annals of Otology, Rhinology & Laryngology 11?(?):??-??.

Analysis of Functional and Anatomic Success Following Endonasal Dacryocystorhinostomy

Barbara Zuercher, MD; Jean-Jacques Tritten, MD;
Jean Paul Friedrich, MD; Philippe Monnier, MD

Objectives: The aim of this study was to assess the concomitant perioperative procedures, the causes of nasolacrimal duct obstruction, the success rate, and the complications associated with endonasal dacryocystorhinostomy (ENDCR).

Methods: In this single-center retrospective study, 98 patients underwent 104 ENDCRs between January 1994 and February 2006. There were 78 patients with 84 nasolacrimal duct obstructions who were included in this study.

Results: The overall functional success rate with improvement in symptoms was 94.9% for primary surgery (59 of 84 obstructions) and 63.6% for salvage surgery after failure of primary surgery performed in another hospital (25 of 84 obstructions). The mean follow-up time was 36.8 ± 17.11 months. Primary surgery showed better results, with a complete success rate of 93.2%, than did salvage surgery, with a success rate of only 68%. Persistent symptoms, despite an open rhinostomy, were found in 1.7% of patients with primary surgery and in 12% of those with salvage surgery. Failure of ENDCR was observed in 3.4% of patients after primary surgery and in 20% after salvage surgery. We encountered only minimal perioperative complications, and these were essentially related to lacrimal intubation.

Conclusions: Because of the possibility of treating concomitant sinonasal disorders, the cosmetic advantages, and the excellent results, ENDCR represents the procedure of choice for treating nasolacrimal duct obstructions. The main challenge lies in the exact preoperative assessment, as well as postoperative evaluation in case of failure.

Key Words: endonasal dacryocystorhinostomy, endoscopy, functional success.

INTRODUCTION

Epiphora is a frequent symptom of acquired nasolacrimal duct obstruction in the elderly population, but can be of congenital origin in children. It may be associated with acute or chronic dacryocystitis. The treatment consists of creating a rhinostomy at the level of the lacrimal sac to bypass the obstruction of the nasolacrimal duct. External dacryocystorhinostomy (EXDCR), as described in 1904 by Toti,[1] was the procedure of choice for the treatment of postcanalicular stenosis in the 20th century. The endonasal approach was first described in 1893 by Caldwell,[2] but was not commonly performed because of poor visibility of and limited access to the endonasal anatomy. The advent of nasal endoscopes has made endonasal approaches more accessible, and otolaryngology specialists began to be involved in this surgery in the early 1990s.[3] Several variations of endonasal dacryocystorhinostomy (ENDCR) have been described, using mucosal flaps, monocanalicular or bicanalicular tubes, and application of mitomycin C.[3-5] Different ways to create the rhinostomy with different types of lasers have been examined,[6,7] and methods for improving access to the lacrimal fossa and establishing a standardized procedure have been reported in the literature.[8,9] The success rates of ENDCR vary between 63% and 93.5%, whereas EXDCR has success rates of 70% to 95.8%.[3,5,9-13] However, the major problem lies in comparing the reported outcomes, because there is no standardized classification of success and systematic clinical evaluation. Many authors only rely on patients' assessments,[14,15] some use endoscopy to visualize the rhinostomy,[16] and others examine the lacrimal drainage system with fluorescein dye testing.[17]

The aim of our study was to analyze the exact rates of different types of success with precise assessment of outcomes by examining all patients with endoscopy and syringing or with fluorescein dye testing to understand the causes of failure. We also examined the complications, concomitant endonasal procedures, and causes of nasolacrimal duct

From the Department of Otorhinolaryngology–Head and Neck Surgery, University Hospital (CHUV), Lausanne (Zuercher, Monnier), and the Departments of Ophthalmology (Tritten) and Otorhinolaryngology (Friedrich), Hospital of Neuchâtel, La Chaux-de-Fonds, Switzerland.

Correspondence: Barbara Zuercher, MD, Dept of Otorhinolaryngology–Head and Neck Surgery, University Hospital, Inselspital, 3010 Bern, Switzerland.

Fig 1. Dacryocystography shows bilateral nasal duct obstruction.

obstruction.

MATERIALS AND METHODS

This is a retrospective study of 98 consecutive patients who underwent 104 ENDCRs for nasolacrimal obstruction performed between January 1994 and February 2006 in the cantonal hospital of La Chaux-de-Fonds, Switzerland. The surgery was performed in cooperation with the ophthalmology unit. The inclusion criteria comprised nasolacrimal duct obstruction without canalicular stenosis, a minimum follow-up of 12 months, and an endoscopic examination of the nasal fossa that included testing of the lacrimal drainage by syringing (until February 2002) or by fluorescein dye testing (since March 2002) at the end of follow-up to assess the objective success.

Preoperative Assessment. The preoperative evaluation included an ophthalmologic examination with lacrimal duct probing and irrigation and an otolaryngological examination including nasal endoscopy and imaging. For all patients, dacryocystography (contrast injection into the lacrimal drainage system; Fig 1) and computed tomographic scanning of the lacrimal drainage system (application of contrast product in the conjunctival sac for functional evaluation of lacrimal drainage), called Dacryo-Scan (Pickler PQ 5000, Cleveland, Ohio), were required (Fig 2).

Surgical Technique. The surgery was performed under general anesthesia. The surgical method has been previously described in the literature.[15] After placement of cottonoids soaked with lidocaine hydrochloride solution at 2% with epinephrine 1:2,000 in the nasal cavity, mucosa in the lacrimal fossa was injected with 2 mL of lidocaine hydrochloride 2% with epinephrine at 1:80,000. The technique consisted of using either a chisel, a drill, or a Kerrison forceps to create the rhinostomy. The uncinate process was resected, and septoplasty or excision of a wide concha bullosa was performed when access to the lacrimal window was hindered. The ophthalmologist probed both canaliculi, and the lacrimal sac was endoscopically visualized and opened by the otolaryngologist. The lacrimal window was created with a minimal length of 15 mm. We did not routinely use local mitomycin C or create mucosal flaps. The lacrimal sac was examined and irrigated, and existing debris or calculi were removed. If necessary, biopsy of the lacrimal mucosa was performed. Intubation of both canaliculi with placement of bicanalicular silicone tubes was carried out in all patients. According to the preoperative findings of Dacryo-Scan, sinonasal treatment was added.

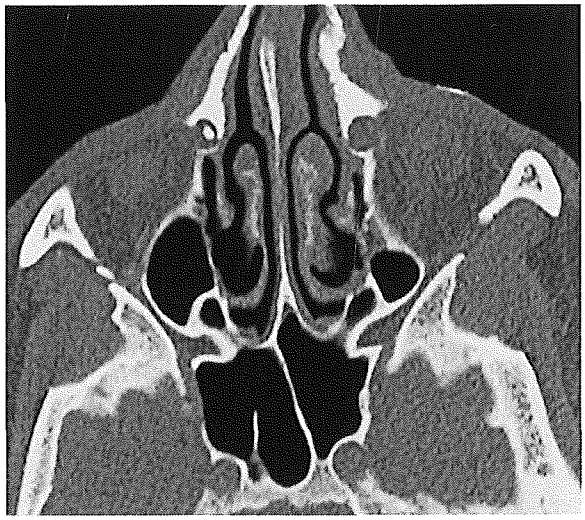

Fig 2. Dacryo-Scan shows unilateral nasal duct obstruction.

Postoperative Period. The patients were treated with a 10-day course of topical ophthalmic steroids and antibiotic drops combined with nasal povidone-iodine ointment. During the postoperative period, the patients underwent weekly rhinoscopy for a period of 3 weeks with removal of crusts to prevent synechia formation. Silicone tubes were usually removed 8 weeks after the operation.

After a minimum follow-up period of 1 year, the last examination included assessment and recording of patients' symptoms, nasal endoscopic and ophthalmic findings, and nasolacrimal irrigation or fluorescein dye testing (Fig 3). This examination consists of intraocular application of fluorescein dye drops into the conjunctival sac, which can be observed around the internal rhinostomy by direct nasal endoscopy if lacrimal drainage is functional.

In children, the postoperative follow-up consisted

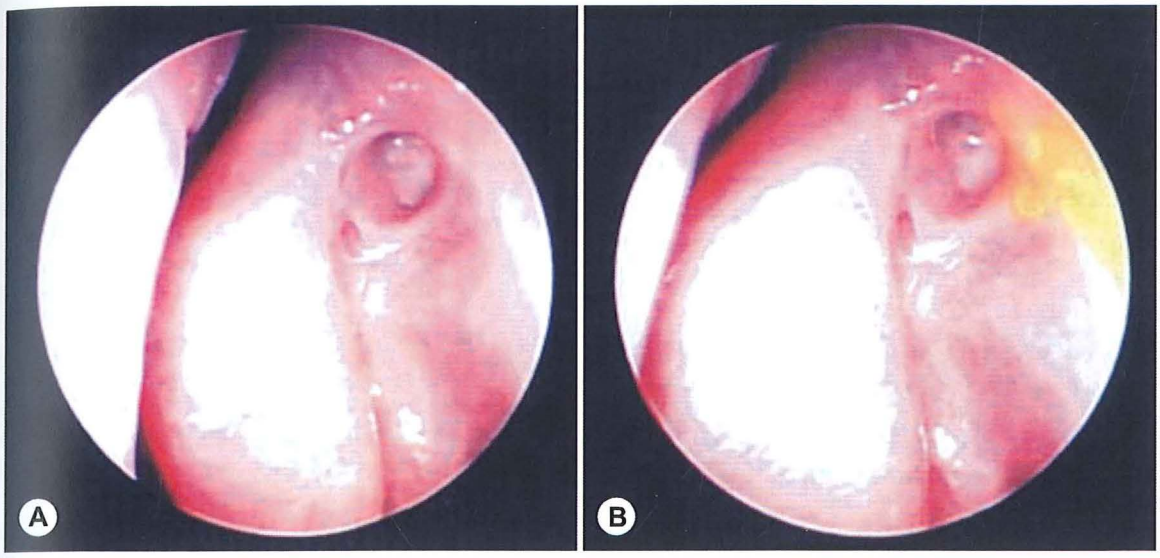

Fig 3. Fluorescein dye test. **A)** Endoscopic view of ostium of endonasal dacryocystorhinostomy. **B)** After application of fluorescein dye in lower fornix of eye.

of 1 postoperative rhinoscopy under general anesthesia for decrusting at 3 weeks and removal of the silicone tubes at 3 to 5 months. In these patients, fluorescein testing was performed and followed by endoscopic examination. If endoscopy was not possible because of lack of cooperation, the child was asked to blow his or her nose in a tissue that was then examined for fluorescein, thereby proving the patency of the rhinostomy.

Evaluation of Success. To evaluate the success of surgery, we used the classification of Ducasse et al,[18] who defined three types of success: 1) complete success, which includes functional and anatomic success (open rhinostomy with improvement in symptoms); 2) functional success, with improvement in symptoms but closed rhinostomy; and 3) anatomic success, with open rhinostomy but persistent symptoms.

RESULTS

Endonasal dacryocystorhinostomy was performed in 98 patients, of whom 78 met the inclusion criteria. Bilateral duct obstruction was found in 6 patients. The right lacrimal system was affected in 38 patients, and the left system in 34. There were 53 female and 25 male patients with a mean age of 59 years (range, 4 to 89 years). Nasolacrimal duct obstruction (n = 84) was associated in 79 cases (94%) with epiphora, in 4 cases (4.8%) with acute dacryocystitis, and in 5 cases (6%) with chronic dacryocystitis. The mean duration of symptoms was 73.38 ± 114.5 months (range, 1 to 684 months), and the initial symptoms occurred at 51.63 ± 19.91 years of age (range, 0 to 85 years).

The cause of obstruction was found in 27.4% of the 84 cases. The most common causes were chronic rhinosinusitis (8.33%), multiple facial fractures (3.57%), and prior sinus surgery (3.57%; Table 1). In our study group, there was a female preponderance that led us to examine the potential role of cosmetics in nasolacrimal duct obstruction. However, 89% of the women denied the frequent use of makeup.

In 61 of 84 obstructions (72.6%), concomitant intraoperative sinonasal procedures were necessary. These included uncinectomy in 32 cases (38.1%), other sinusal surgery in 16 cases (19%), and septoplasty in 9 cases (10.7%; Table 2). Bicanalicular tubes were left in place for a mean of 8.37 ± 3 weeks (range, 1.5 to 18 weeks). The mean follow-up time was 36.8 ± 17.11 months (range, 12 to 77 months).

We observed few intraoperative complications (7.1%). The early postoperative complications (up to 5 days) were essentially related to the nasolacri-

TABLE 1. CAUSES OF NASOLACRIMAL DUCT OBSTRUCTION

	Cases (N = 84)	
	No.	*%*
Sinusitis and/or rhinitis	7	8.3
Maxillofacial trauma	3	3.6
Cleft palate	2	2.4
Sinus surgery	3	3.6
Radiotherapy for nasopharyngeal cancer	1	1.2
Radiotherapy for melanoma of choroid	2	2.4
Radioiodine therapy for papillary cancer	2	2.4
Tear of eyelid	1	1.2
Congenital nasal duct obstruction	2	2.4
Undetermined	61	72.6

TABLE 2. ADDITIONAL INTRAOPERATIVE PROCEDURES

	Cases (N = 84)	
	No.	%
Uncinectomy	32	38.10
Sinusoscopy	10	11.90
Septoplasty	9	10.71
Middle meatal antrostomy	5	5.95
Excision of concha bullosa	2	2.38
Ethmoidectomy	1	1.19
Polypectomy	1	1.19
Incision of subcutaneous abscess	1	1.19

mal stent (7 of 84; 8.3%). Eyelid tumefaction and emphysema were found in 3.57% of the cases (3 of 84). Late postoperative complications were related to the bicanalicular tube (10.71%), synechia formation without functional consequences (13.1%), and inflammation of the lacrimal drainage system (7.14%; Table 3). Among the complications due to lacrimal intubation, 8 cases of tube migration and 2 cases of excessive fixation with tension in the canaliculi were observed. The tube was lost in 3 patients. Four cases of granulation tissue formation at the internal ostium were found, although it did not affect the lacrimal drainage. Persistent air reflux when blowing the nose was found in 26 of 84 cases (31%), and air reflux was intermittent in 2 cases (2.4%).

A complete success rate of 85.7%, including both primary and salvage surgery, was determined. Primary surgery showed better results, with a complete success rate of 93.2% (55 of 59 cases), than did salvage surgery, with a success rate of only 68% (17 of 25 cases). This latter group had an anatomic success rate of 12% and a complete failure rate of 20% (Table 4). Improvement in symptoms was seen in 94.9% after primary surgery (56 of 59 cases) and 68% after salvage surgery (17 of 25 cases). Recurrence or persistence of epiphora occurred in 11 of 84 cases (13.1%). Figure 4 illustrates the recurrence of epiphora as a function of time.

TABLE 3. INTRAOPERATIVE AND EARLY AND LATE POSTOPERATIVE COMPLICATIONS OF ENDONASAL DACRYOCYSTORHINOSTOMY

	Cases (N = 84)	
	No.	%
Intraoperative		
Trauma to vestibule during drilling	3	3.57
Diffuse bleeding	2	2.38
Injury to inferior canalicula	1	1.19
Total	6	7.14
Early postoperative (≤5 days)		
Problems related to tolerance and fixation of bicanalicular tube	7	8.33
Periorbital edema or emphysema	3	3.57
Bleeding	2	2.38
Subconjunctival hematoma	1	1.19
Total	13	15.48
Late postoperative (>6 days)		
Synechia formation without functional repercussion	9	10.71
Problems related to tolerance and fixation of bicanalicular tube	11	13.09
Inflammation and infection of lacrimal drainage system	6	7.14
Total	26	30.95

TABLE 4. SUCCESS RATES OF PRIMARY AND SALVAGE SURGERIES AND OVERALL SUCCESS

	Primary and Salvage Surgery (N = 84)		Primary Surgery (N = 59)		Salvage Surgery (N = 25)	
	No.	%	No.	%	No.	%
Complete success	72	85.7	55	93.2	17	68
Functional success	1	1.2	1	1.7	0	0
Anatomic success	4	4.8	1	1.7	3	12
Failure	7	8.3	2	3.4	5	20

DISCUSSION

Preoperative Imaging. Before operation, every patient was evaluated by dacryocystography and Dacryo-Scan. In some previously reported series, preference was given only to dacryocystography[19] or a computed tomographic scan of the lacrimal drainage system.[8,9] Dacryocystography may mask anatomic obstruction by generating a high pressure and may bypass possible presaccal disorders with injection of the contrast medium into the lacrimal punctum.[20] Dacryo-Scan allows evaluation of the functional lacrimal drainage system after application of contrast into the lower fornix of the eye.[21] Absence of contrast visualization in different levels of the lacrimal system as compared to the other eye allows classification of the stenosis into canalicular, presaccal, and saccal. Some authors[20,22,23] recommend lacrimal scintigraphy, in which a small amount of radioisotope is placed in the conjunctival region to assess filling of the sac and progression of the radioisotope into the nasal cavity. However, Dacryo-Scan is more routinely accessible than lacrimal scintigraphy in local hospitals and provides extra information pertaining to nasal anatomy and the lacrimal system, adjacent bony structures, and associated sinonasal problems. Possible complications can be prevented by assessing anatomic problems before operation. In our series, the uncinate process was resected in 32 patients, septoplasty was performed in 9 cases for septal deviation, and the concha bullosa was excised in 2 patients. Dacryo-Scan also provides information on concomitant sinonasal

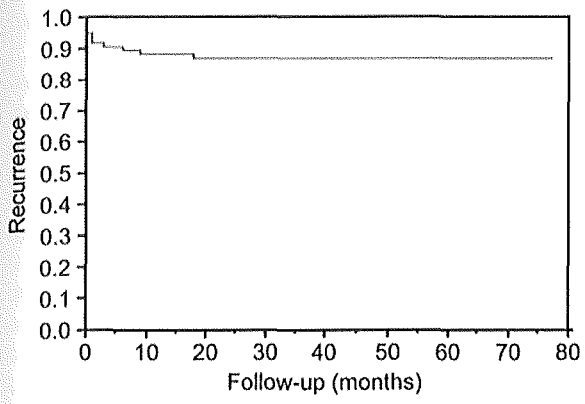

Fig 4. Rate of recurrence of epiphora in months.

disorders that may require surgery. Sixteen interventions for sinonasal disease and 1 nasal polypectomy were performed in our series. Therefore, preoperative assessment of a case of epiphora should always include nasal endoscopy, as well as a Dacryo-Scan including the sinuses, to evaluate the possible need for sinus surgery.

Causes of Obstruction. The cause of nasolacrimal duct obstruction remained unknown in 73% of the cases in our series. Despite a female predisposition of 2 to 1, the role of cosmetics in this disorder could not be proven from our results. One of our patients was treated by thyroidectomy and radioiodine therapy for papillary thyroid carcinoma 3 years before presenting with bilateral epiphora. Intraoperative examination in this patient showed a very narrow nasolacrimal sac with mucosal fibrosis. Burns et al[24] reported an incidence of 3.4% of nasolacrimal duct obstruction in 563 patients treated by iodine 131 therapy for thyroid carcinoma. Sakahara et al[25] were able to prove an uptake of iodine 131 by the nasolacrimal system after radioiodine therapy in 3 patients by visualization with single-photon emission computed tomography 3 days after administration of radioiodine therapy. Iodine 131, which is accumulated in the lacrimal drainage system and excreted in tears, can cause nasolacrimal duct obstruction after high-dose radioiodine therapy. In our study, 1 patient presented with bilateral epiphora 2 years after irradiation of a melanoma in the right choroidea. Another patient underwent combined chemoradiation for cT4 cN1 cM0 nasopharyngeal cancer and presented with unilateral epiphora 5 years after his oncological treatment. Good functional results were obtained in 2 of 3 ENDCRs. In 1 case, improvement of symptoms was observed despite the fact that the rhinostomy was closed.

Nakissa et al[26] reported 4 cases of epiphora due to nasolacrimal duct obstruction in 30 patients treated with radiotherapy for paranasal sinus malignancies. It has been reported that irradiation of ocular, sinusal, and nasopharyngeal malignancies can cause desquamation of the epithelium in the nasolacrimal duct, inflammation, fat atrophy, and fibrosis of the orbital soft tissue resulting in epiphora.[27]

Bicanalicular Tubes. The systematic use of bicanalicular tubes is still controversial. Although some authors report better results with bicanalicular tubes when compared to no lacrimal intubation, with a success rate of 82% to 89% versus 67% to 75%, respectively,[3,4] many surgeons refrain from the systematic use of stents[16,28] or use them only in cases of presaccal stenosis.[16] Poor results, with a success rate of 18.5% to 31%, were published for a series using polyurethane stents.[28,29] Silicone tubes with stainless steel probes on either end (BIKA, FCI, Groupe IOLTECH, Paris, France) were used in all of our patients. In the literature, removal of bicanalicular tubes was done within 1 to 6 months (average, 3 months).[7,17,30] In our series, the stent was removed at an average postoperative time of 8 weeks. Healing of the rhinostomy is assumed to be completed by this time. Keeping the tube in place for a longer period of time is contraindicated, because it may induce a foreign body reaction and granulation tissue formation at the internal ostium.[7] All complications due to lacrimal intubation were minor, and they did not influence lacrimal drainage. Tube migration and excessive fixation of the tube were observed mainly in the early part of the series, until a better tube fixation at the right length was used. Four cases of granulation tissue at the internal ostium (4.8%) were encountered without impairment of lacrimal drainage. These granulations were removed under local anesthesia and treated by topical betamethasone dipropionate–gentamicin ointment. Even though there were many minor postoperative complications related to fixation or tolerance of the bicanalicular tubes, the high success rate of our series might well be explained by their systematic use.

Functional Success. In the literature, reported success is usually based on a purely functional outcome. The absence of symptoms becomes the basis of success by ignoring the intranasal clinical findings. In the 11 cases of functional failure with persistence or recurrence of epiphora, 4 cases of anatomic success (36%) with an open orifice were found, of which 3 were cases of revision of the lacrimal system. Typical of this type of failure, all 3 patients complained of no postoperative symptom improvement, as is normally observed in patients with scarring from a primary functional dacryocystorhinostomy. A defective tear pump was suspected in 2 of these patients, and 1 patient with bilateral symptoms was finally treated successfully for conjunctival cysts. A posi-

tive fluorescein dye test allowed identification of the real problem, which was situated proximal to the nasolacrimal duct. Endonasal dacryocystorhinostomy was not repeated in these cases. Beigi et al[31] examined a methodical strategy for assessing epiphora and found that diagnostic preoperative syringing presents a high rate of false-positive results for nasolacrimal duct obstruction. Canalicular disease is not uncommon in patients with epiphora and is often underdiagnosed by syringing alone. This may explain the high rate of anatomic successes, especially following salvage surgery. However, ENDCR can improve symptoms in patients with a patent nasolacrimal duct on syringing.[32] Among patients who present with epiphora and a patent nasolacrimal duct on syringing, ENDCR still relieves symptoms in 50%.[33] These patients may have had a canalicular stenosis, and the improvement in symptoms could be ascribed to the surgical manipulation and placement of bicanalicular tubes. Because the lacrimal drainage system is situated proximal to the nasolacrimal duct, problems such as canalicular stenosis or a tear pump defect may be missed if only preoperative and postoperative assessment with syringing is used.

Salvage Surgery. Irrespective of the type of prior lacrimal operation, salvage ENDCR was less successful than primary surgery. The functional success rate was 95% for primary ENDCR and 68% for salvage ENDCR. Our results of salvage ENDCR are comparable with those of other published series, which vary between 50% and 76.5%.[10,23] The rates of anatomic success (12%) and complete failure (20%) in patients with salvage surgery were surprising. Anatomic success rates reported in other series are 1.5%,[34] 5.7%,[10] and even 39%.[35] The incidence of this type of partial success is probably much higher, but is not always searched for by fluorescein dye testing and nasal endoscopy. It is important to understand why patients continue to have symptoms. For assessing failures, endonasal examination should be combined with fluorescein dye testing to define the type of failure, to identify the real problem, and to reconsider the treatment.

Reopening of Nasolacrimal Duct. Reopening of the natural lacrimal system was found in 1 patient, although the rhinostomy had closed spontaneously. This phenomenon of resolution of epiphora due to reopening of the nasolacrimal duct, and not because of a patent rhinostomy, was described previously by Arullendran et al[36] in 5 patients. The reason is not known, but two hypotheses were advanced. Either the obstruction can be proximal to the nasolacrimal duct, with resolution occurring by surgical manipulation and intubation of the canaliculi, or the disease causing the obstruction can resolve spontaneously, as was probably the case in our patient. He was known for having recurrent sinusitis and reported resolution of epiphora only after removal of the bicanalicular tube. The role of rhinitis in patients with epiphora is often underestimated. McNeill et al[37] found a significant improvement of epiphora in 7 of 11 patients with rhinitis after topical steroid application. In our series, 7 patients had a history of chronic rhinitis and/or sinusitis. In cases of a positive history of rhinitis, nasal endoscopy should be performed, and treatment with topical nasal steroids should be tried before dacryocystorhinostomy.

Time Delay to Recurrence of Symptoms. In our series, 91% of cases of epiphora (10 of 11 functional failures) recurred within the first year. There was no recurrence of epiphora after 18 months. Fayet et al[8,9] reported maximum recurrence of epiphora in the first year, with no recurrence after 2 years, and Adenis et al[38] found 83% recurrence within the first 3 months. On the basis of our results, we recommend waiting at least 1 year before considering ENDCR a success.

Concomitant Intraoperative Surgery. In our series, 61 concomitant procedures were added to ENDCR. As most of the concomitant surgical procedures were part of the surgical approach, the results were not compared between the two groups. In 43 cases (51%), these procedures were performed to improve access to the lacrimal area. Uncinectomy, which is becoming more and more common, helps orient the surgeon in light of the variability of the endonasal structures, helps standardize ENDCR, and provides safe access to the lacrimal fossa.[8,9] The results are comparable to those of conventional ENDCR, and very few complications related to this procedure have been reported.[8,9] Septoplasty was described in up to 30% of ENDCRs in the literature, and resection of the middle turbinate in up to 21%.[8,9,15,22] We did not perform resection of the middle turbinate. Septoplasty was carried out in only 11% of the cases in our series. Additional trauma to the inner nasal structures may cause other complications such as infections, bleeding, or synechia formation. To avoid open septoplasty, we mainly dislocated the septum on the contralateral side to improve preoperative access for manipulation in the lacrimal area. Synechia formation between the ostium and the septum or the middle turbinate is known to be a major cause of failure in ENDCR. It can occur in up to 37.5% of cases and can impair lacrimal drainage in up to 40%.[8,9,17] To prevent synechia formation, we recommend weekly decrusting of the nasal fossa by endoscopy until the third postoperative week. As described in the

literature,[16,17] postoperative nasal endoscopy is important for identifying iatrogenic nasal mucosal disease, preventing complications, avoiding recurrences, and assessing the subjective outcome in combination with fluorescein dye testing.

Air Reflux. In our series, persistent air reflux when blowing the nose after ENDCR was found in 26 of 84 cases (31%), and intermittent air reflux was found in 2 cases (2.4%). Herbert and Rose[14] described air reflux after EXDCR in 47% of operations (46 of 98), which was persistent in 36.7%, and was generally associated with a higher success rate. As in EXDCR, the valve of Rosenmüller can be damaged by surgical manipulations and silicone intubation. Air reflux was not considered to be a problem by our patients, but it should be mentioned as a possible side effect of ENDCR.

CONCLUSIONS

Because of the possibility of treating concomitant sinonasal disorders, the cosmetic advantages, and the excellent results, ENDCR represents the procedure of choice for treating nasolacrimal duct obstructions. The main challenge lies in the exact preoperative assessment and in postoperative evaluation in cases of failure. The success rate associated with this procedure depends mainly on the patient selection and the quality of the operative indication.

REFERENCES

1. Toti A. Nuovo metodo conservatore di cura radicale delle suppurazioni cronici del sacco lacrimale (dacriocistorinostomia). Clin Med Firenze 1904;10:385-7.

2. Caldwell GW. Two new operations for obstruction of the nasal duct. N Y J Med 1893;57:581-2.

3. Sadiq SA, Ohrlich S, Jones NS, Downes RN. Endonasal laser dacryocystorhinostomy — medium term results. Br J Ophthalmol 1997;81:1089-92.

4. Smirnov G, Tuomilehto H, Teräsvirta M, Nuutinen J, Seppä J. Silicone tubing after endoscopic dacryocystorhinostomy: is it necessary? Am J Rhinol 2006;20:600-2.

5. Tsirbas A, Wormald PJ. Endonasal dacryocystorhinostomy with mucosal flaps. Am J Ophthalmol 2003;135:76-83.

6. Sadiq SA, Hugkulstone CE, Jones NS, Downes RN. Endoscopic holmium:YAG laser dacryocystorhinostomy. Eye (Lond) 1996;10:43-6.

7. Ressiniotis T, Voros GM, Kostakis VT, Carrie S, Neoh C. Clinical outcome of endonasal KTP laser–assisted dacryocystorhinostomy. BMC Ophthalmol 2005;5:2.

8. Fayet B, Racy E, Assouline M. Complications of standardized endonasal dacryocystorhinostomy with unciformectomy. Ophthalmology 2004;111:837-45.

9. Fayet B, Racy E, Assouline M. Systematic unciformectomy for a standardized endonasal dacryocystorhinostomy. Ophthalmology 2002;109:530-6.

10. Ben Simon GJ, Joseph J, Lee S, Schwarcz RM, McCann JD, Goldberg RA. External versus endoscopic dacryocystorhinostomy for acquired nasolacrimal duct obstruction in a tertiary referral center. Ophthalmology 2005;112:1463-8.

11. Cokkeser Y, Everekliogiu C, Er H. Comparative external versus endoscopic dacryocystorhinostomy: results in 115 patients (130 eyes). Otolaryngol Head Neck Surg 2000;123:488-91.

12. Dolman PJ. Comparison of external dacryocystorhinostomy with nonlaser endonasal dacryocystorhinostomy. Ophthalmology 2003;110:78-84.

13. Hartikainen J, Grenman R, Puukka P, Seppä H. Prospective randomized comparison of external dacryocystorhinostomy and endonasal laser dacryocystorhinostomy. Ophthalmology 1998;105:1106-13.

14. Herbert HM, Rose GE. Air reflux after external dacryocystorhinostomy. Arch Ophthalmol 2007;125:1674-6.

15. Nussbaumer M, Schreiber S, Yung MW. Concomitant nasal procedures in endoscopic dacryocystorhinostomy. J Laryngol Otol 2004;118:267-9.

16. Keerl R, Weber R. Dacryocystorhinostomy — state of the art, indications, results [in German]. Laryngorhinootologie 2004;83:40-50.

17. Minasian M, Olver JM. The value of nasal endoscopy after dacryocystorhinostomy. Orbit 1999;18:167-76.

18. Ducasse A, Reynal C, Ségal A. Les échecs de la dacryocystorhinostomie. Bull Soc Ophtalmol Fr 1993;93:35-9.

19. Merkonidis C, Brewis C, Yung M, Nussbaumer M. Is routine biopsy of the lacrimal sac wall indicated at dacryocystorhinostomy? A prospective study and literature review. Br J Ophthalmol 2005;89:1589-91.

20. Wormald PJ, Tsirbas A. Investigation and endoscopic treatment for functional and anatomical obstruction of the nasolacrimal duct system. Clin Otolaryngol Allied Sci 2004;29:352-6.

21. Boldea RC, Friedrich JP, Pazera A, Tritten JJ. Dacryocystorhinographie versus dacryoscanner: quel bilan pré-opératoire pour les dacryocystorhinostomies par voie endoscopique? Rev Med Suisse Rom 2004;124:265-8.

22. Tsirbas A, Davis G, Wormald PJ. Mechanical endonasal dacryocystorhinostomy versus external dacryocystorhinostomy. Ophthal Plast Reconstr Surg 2004;20:50-6.

23. Tsirbas A, Davis G, Wormald PJ. Revision dacryocystorhinostomy: a comparison of endoscopic and external techniques. Am J Rhinol 2005;19:322-5.

24. Burns JA, Morgenstern KE, Cahill KV, Foster JA, Jhiang SM, Kloos RT. Nasolacrimal obstruction secondary to I^{131} therapy. Ophthal Plast Reconstr Surg 2004;20:126-9.

25. Sakahara H, Yamashita S, Suzuki K, Imai M, Kosugi T. Visualization of nasolacrimal drainage system after radioiodine therapy in patients with thyroid cancer. Ann Nucl Med 2007;21:525-7.

26. Nakissa N, Rubin P, Strohl R, Keys H. Ocular and orbital complications following radiation therapy of paranasal sinus malignancies and review of literature. Cancer 1983;51:980-6.

27. Gordon KB, Char DH, Sagerman RH. Late effects of radiation on the eye and ocular adnexa. Int J Radiat Oncol Biol Phys 1995;31:1123-39.

28. Bertelmann E, Rieck P. Polyurethane stents for lacrimal

duct stenoses: 5-year results. Graefes Arch Clin Exp Ophthalmol 2006;244:677-82.

29. Oztürk S, Konuk O, Ilgit ET, Unal M, Erdem O. Outcome of patients with nasolacrimal polyurethane stent implantation: do they keep tearing? Ophthal Plast Reconstr Surg 2004; 20:130-5.

30. Yung MW, Hardman-Lea S. Endoscopic inferior dacryocystorhinostomy. Clin Otolaryngol Allied Sci 1998;23:152-7.

31. Beigi B, Uddin JM, McMullan TF, Linardos E. Inaccuracy of diagnosis in a cohort of patients on the waiting list for dacryocystorhinostomy when the diagnosis was made by only syringing the lacrimal system. Eur J Ophthalmol 2007;17:485-9.

32. O'Donnell BA, Clement CI. Assessing patients with epiphora who are patent to syringing: clinical predictors of response to dacryocystorhinostomy. Ophthal Plast Reconstr Surg 2007;23:173-8.

33. Sahlin S, Rose GE. Lacrimal drainage capacity and symptomatic improvement after dacryocystorhinostomy in adults presenting with patent lacrimal drainage systems. Orbit 2001;20:173-9.

34. Moore WM, Bentley CR, Olver JM. Functional and anatomic results after two types of endoscopic endonasal dacryocystorhinostomy: surgical and holmium laser. Ophthalmology 2002;109:1575-82.

35. Ibrahim HA, Batterbury M, Banhegyi G, McGalliard J. Endonasal laser dacryocystorhinostomy and external dacryocystorhinostomy outcome profile in a general ophthalmic service unit: a comparative retrospective study. Ophthalmic Surg Lasers 2001;32:220-7.

36. Arullendran P, Robson AK, Bearn M. Endoscopic laser dacryocystorhinostomy. An unusual postoperative finding: reopening of the nasolacrimal duct. J Laryngol Otol 2001;115: 1015-7.

37. McNeill EJ, Kubba H, Bearn MA, Robson AK. The management of rhinitis in patients with functional epiphora: a randomized controlled crossover trial. Am J Rhinol 2005;19:588-90.

38. Adenis JP, Mathon C, Lebraud P, Franco JL. La dacryocystorhinostomie. Etude rétrospective de 165 cas. Indications. Technique. Résultats. J Fr Ophthalmol 1987;10:323-9.