



Hematuria in a 12-year-old child, a rare case of urothelial papilloma of the urinary bladder



Alexis Litchinko^a, Blaise Julien Meyrat^a, Antoine Nobile^b, Lara Raffoul^a, Gezim Dushi^a, Vanina Estremadoyro^{a,*}

^a Department of Pediatric Surgery, University Hospital of Lausanne, Rue de Bugnon 46, CH-1011 Lausanne, Switzerland

^b Department of Pathology, University Hospital of Lausanne, Rue du Bugnon 25, 1011 Lausanne, Switzerland

ARTICLE INFO

Article history:

Received 11 January 2016

Received in revised form

23 February 2016

Accepted 27 February 2016

Key words:

Hematuria

Bladder

Urothelial tumor

ABSTRACT

We describe a case of a 12-year-old boy with an isolated macroscopic hematuria. A urinary ultrasound revealed a bladder tumor next to the right ureteric orifice. A biopsy revealed a urothelial papilloma. He underwent a successful resection by cystostomy. This benign tumor is extremely rare in children and its management remains controversial.

© 2016 The Authors. Published by Elsevier Inc. This is an open access article under the CC BY-NC-ND license (<http://creativecommons.org/licenses/by-nc-nd/4.0/>).

1. Case report

A 12-year-old boy presented in January 2015 with a painless macroscopic hematuria. There was no history of trauma and no family history of urinary lithiasis.

On physical examination the patient's vital signs were stable. There was no abdominal or flank pain, and the abdomen was not distended.

A urinary tract ultrasound showed a heterogeneous hyperechogenic bladder wall tumor emerging near the right ureteric orifice, described by the radiologist as a probable blood clot (Fig. 1).

After one month a second ultrasound was performed to confirm or infirm the diagnosis of a blood clot. As the aspect of the lesion was the same, we decided to realize a cystoscopy under general anesthesia.

The endoscopy revealed an exophytic, fungating tumor at the postero-lateral bladder wall near the right ureteric orifice (Fig. 2). The tumor looked like a small bunch of grapes with a broad stem (Fig. 3). A first biopsy was inconclusive as the sample was too small. A second biopsy revealed a polypoid lesion with no signs of malignancy.

As the macroscopic hematuria persisted, in April 2015, a cystostomy through a Pfannestiel incision was performed. A complete resection of the tumor was possible via this approach. The anato-pathological analysis concluded in an urothelial papilloma of the bladder (Figs. 4 and 5).

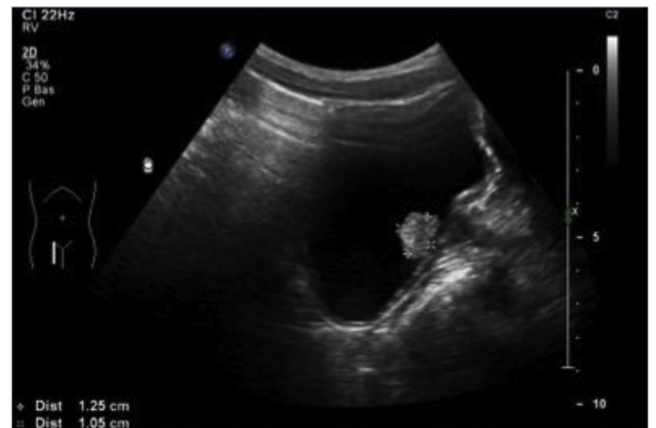

Fig. 1. Ecographic intravesical hyperechogenic lesion described as a blood clot.

* Corresponding author. Tel.: +41 79 5566854.

E-mail address: Vanina.Estremadoyro-Espinoza@chuv.ch (V. Estremadoyro).

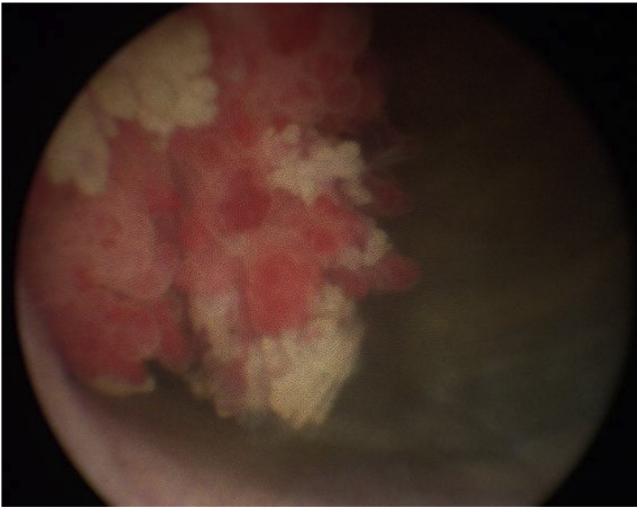


Fig. 2. Macroscopic aspect of the lesion by cystoscopy.

The postoperative course was simple. There was no recurrence of the hematuria. Our patient is now in good health and standard surveillance is provided.

2. Discussion

Hematuria is a common symptom at the emergency room. Most hematuria are benign signs of a urinary tract infection or a nephrological disease that require medical treatment and ambulatory care [1].

The source of bleeding can originate from the glomerulus, the medullary interstitium, the urinary tract or the renal vasculature. In our case, the urinal sediment confirmed a macro-hematuria with no dysmorphic red cells, which removed the possibility of any glomerular causes (acute poststreptococcal glomerulonephritis, Alport syndrome, rapidly progressive glomerulonephritis, systemic lupus erythematosus, Wegener granulomatosis). The most common causes of non-glomerular hematuria are urinary tract infections, trauma, hypercalciuria, renal masses and urolithiasis. Cytobacteriological examination of the urine in our patient was sterile, creatinine level was normal and there was no calciuria.

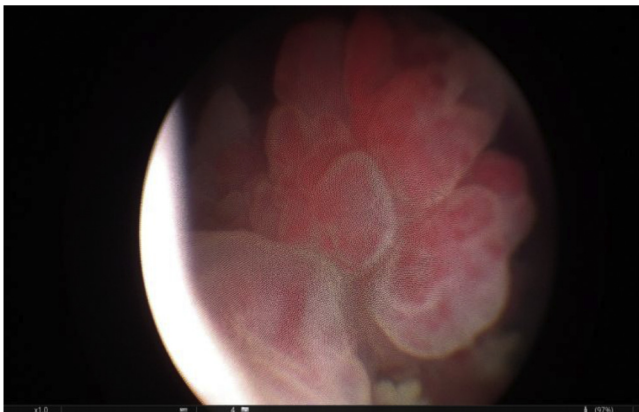


Fig. 3. Aspect of the intravesical lesion by cystoscopy.

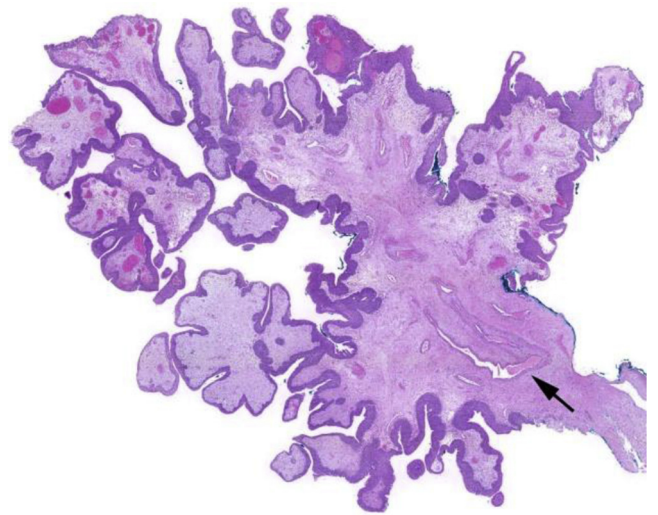


Fig. 4. At low power, thick-walled vessels (arrow) are branching into the polyp stalk.

In our case, since the urinalysis was negative, the next logical step was the radiologic investigations of the urinary tract for evaluating the hematuria.

In some cases, hematuria in children can reveal bladder tumors such as rhabdomyosarcoma of the bladder or papillary urothelial neoplasm of low malignant potential (PUNLMP) [2].

An uncommon type of lesion in children are urothelial papillomas. These tumors are benign exophytic lesions characterized by simple non branching papillary fronds lined by normal-appearing urothelium lacking atypia. The World Health Organisation/International Society of Urologic Pathology (WHO/ISUP) considers them as a distinct but uncommon entity. This benign tumor is very rare in children and the typical presenting symptom is hematuria [3,4].

Most urothelial papillomas are located on the posterior or lateral walls of the bladder close to the ureteric orifices or in the

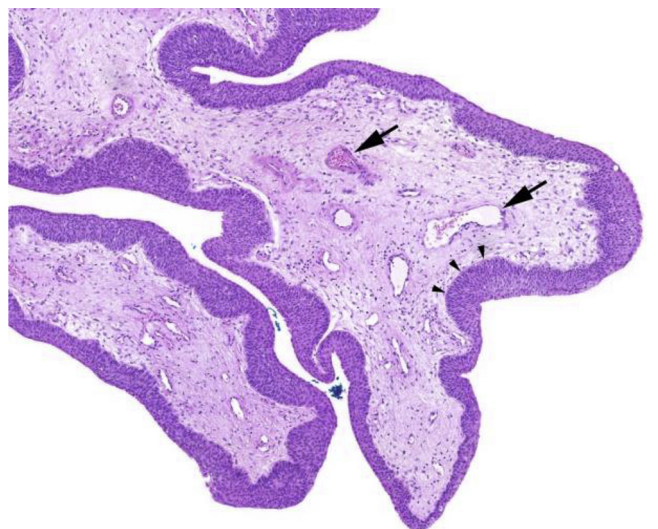


Fig. 5. At medium power, one can appreciate an urothelial lining of even thickness throughout the whole polyp (arrow heads), bordering a loose connective tissue containing numerous small capillaries (arrows).

urethra. The cystoscopic appearance is identical to other low-grade papillary urothelial neoplasms. We believe the combination of standard procedure and the malignancy potential of the lesion made the open surgery the safest way to totally remove it.

3. Conclusion

Urothelial papillomas are extremely rare tumors and are mainly described in adult patients. Pediatric guidelines are currently unavailable given the small number of cases found in literature, and their management still remains controversial. Additional studies are still needed to evaluate the risk of recurrence and progression.

Disclosure treatment

The authors have received no financial support, and do not have any potential conflicts of interest to report.

References

- [1] Diven SC, Travis LB. A practical primary care approach to hematuria in children. *Paediatr Nephrol* 2000;14:65.
- [2] Alanee Shaheen, Shukla Aseem R. Bladder malignancies in child aged <18 years: results from the Surveillance, Epidemiology and End Results Database. *BJU Int* 2009;106:557–60.
- [3] Cheng L. Urothelial papilloma of the bladder. Clinical and biologic implications. *Cancer* 1999 Nov 15;86(10):2098–101.
- [4] Rifat Usama N, Hamadalla Nader Y, Chiad Safi Khalid C, Mohammed Mustafa. Urothelial bladder tumor in childhood: a report of two cases and a review. *Arab J Urol* 2015;13:116–21.