

Prolonged Treatment With Almitrine for Refractory Hypoxemia in Adult Respiratory Distress Syndrome*

Jean-Benoît Thorens, M.D.; Philippe Jolliet, M.D.; and Jean-Claude Chevrolet, M.D.

A 49-year-old man presented with an atypical pneumonia entailing an adult respiratory distress syndrome (ARDS). The refractory hypoxemia caused a myocardial infarction, leading us to try pharmacologic treatments. Almitrine bismesilate (AB) infusion allowed improvement of arterial oxygenation during 115 h without adverse effect. This case is, to our knowledge, the first reported prolonged treatment using AB for hypoxemia due to ARDS. (*Chest* 1994; 105:1579-80)

AB=almitrine bismesilate; ARDS=adult respiratory distress syndrome; PEEP=positive end-expiratory pressure; PIP=peak inspiratory pressure; PAP= pulmonary artery pressure; Qs/Qr=shunt

Almitrine bismesilate (AB) increases PaO₂ and decreases PaCO₂ in patients with COPD.¹⁻³ The AB has also been assessed in patients with the adult respiratory distress syndrome (ARDS).⁴⁻⁶ It entails a transient but significant improvement in PaO₂ and in the alveolar-arterial PO₂ difference,⁴ a reduction in ventilation/perfusion inequalities as measured by the multiple inert gas elimination technique,⁵ and an increase in PaO₂ comparable with that of a PEEP of 10 cm H₂O.⁶ The major side effects of AB are an increase in pulmonary arterial pressure⁷ and a peripheral neuropathy during long-term administration.¹

We report on a patient with ARDS, due to atypical pneumonia, presenting with severe refractory hypoxemia having caused a myocardial infarction, in whom a treatment of AB allowed a prolonged and reproducible improvement of arterial oxygenation without any apparent adverse effects.

CASE REPORT

A 49-year-old male teacher was admitted to the ICU for respiratory failure. His medical history revealed a coronary arterial bypass 5 years previously, without subsequent symptoms. He was a heavy tobacco smoker and was treated for hyperlipemia. During the week preceding admission, the patient complained of fever (38°C), increasing dyspnea, and dry cough. On physical examination, he was febrile (38.2°C), the pulse rate was 120 beats per minute, and the blood pressure 90/45 mm Hg. Respiratory rate was 50 per minute. Dry rales were heard bilaterally. Laboratory examination results follow: hematocrit was 38.6 percent; hemoglobin, 12.9 g/dl; WBC count, 7.7 · 10⁹/L with 6 percent band cells; platelet count, 164 · 10⁹/L; prothrombin time, 65 percent of control and activated partial thromboplastin time, 30.4 s; bilirubin, 16 μM/L; alkaline phosphatase, 35 U/L; aspartate

*From the Division of Pneumology (Dr. Thorens) and Medical Intensive Care Unit (Drs. Thorens, Jolliet, and Chevrolet), University Hospital, Geneva, Switzerland.

Table 1—Hemodynamic Data and Gas Exchange During Almitrine Bismesilate Trials*

	Trial 1		Trial 2	
	t=0	t=60'	t=0	t=60'
QT, L/min	7.28	7.2	10.33	9.32
MAP, mm Hg	71	75	66	64
PAP m, mm Hg	22	24	15	21
SVR, dynes · s · cm ⁻⁵	672	700	449	515
PVR, dynes · s · cm ⁻⁵	121	100	77.4	86
FI _{O2}	.85	.85	1.0	1.0
pH a	7.37	7.38	7.37	7.35
PaCO ₂ , kPa	5.69	4.9	7.0	6.9
PaO ₂ , kPa	7.73	12.16	7.1	8.3
SaO ₂ , %	81	97	85	90
pH v	—	—	7.33	7.33
PvCO ₂ , kPa	—	—	7.8	7.8
PvO ₂ , kPa	—	—	5.0	5.3
SvO ₂ , %	—	—	65.7	68.6
Qs/Qr	—	—	47	35

*QT=cardiac output; MAP=mean arterial systemic pressure; PAPm=mean arterial pulmonary pressure; SVR=systemic vascular resistance; PVR=pulmonary vascular resistance; a=arterial; v=mixed venous; t=0, before AB treatment; t=60', after 1 h of AB treatment.

aminotransferase and alanine aminotransferase, 450 and 537 U/L, respectively; lactate dehydrogenase, 2,103 U/L; chest x-ray, bilateral interstitial infiltrates; and arterial blood gases (FI_{O2}=0.4), pH 7.2, PaCO₂ 2.5 kPa, PaO₂ 8.0 kPa, oxygen saturation (SaO₂) 88 percent, base excess—15 mmol/L.

Broad spectrum antibiotic therapy with amoxicillin/clavulanic acid and erythromycin was started. The next day, because of worsening hypoxemia and clinical signs of respiratory muscle fatigue, the patient was intubated and mechanical ventilation initiated. Bronchoalveolar lavage showed 14 × 10⁴ cells/ml, 34 percent macrophages, 2 percent lymphocytes, 62 percent polymorphonuclear, 1 percent eosinophils, and 1 percent basophils. Blood and lavage cultures remained sterile. While receiving 100 percent O₂ with a PEEP of 5 cm H₂O, arterial blood gases were pH 7.34, PaCO₂ 5.7 kPa, PaO₂ 9.88 kPa, and SaO₂ 91 percent. Peak inspiratory pressure (PIP) was 40 cm H₂O. A mixed ventilatory mode combining high frequency jet and conventional ventilations was started the same day, allowing both a decrease in PIP (25 to 30 cm H₂O) and a transiently better oxygenation (FI_{O2} 0.55, SaO₂ 90 percent). The situation worsened over the next 6 days, however, requiring a progressive increase in FI_{O2} to 1.0 with SaO₂ between 80 and 90 percent. As a complication of this severe hypoxemia, the patient had an inferior myocardial infarction (creatinine kinase/creatinine kinase-MB=769/120 U/L). A trial of nitric oxide (35 to 50 ppm) delivered via the inspiratory line was unsuccessful for increasing PaO₂. As pulmonary arterial pressure was in the normal range, two tests with AB, 1 mg/kg intravenously during 1 h were performed, 24 h apart (Table 1). As both tests were beneficial to SaO₂ and well tolerated, a continuous infusion was administered, the dosage being adjusted (0.1 to 0.5 mg/kg/h) to maintain a SaO₂ ≥ 85 percent. The AB was infused for a total of 115 h.

Figure 1 shows calculated shunt (Qs/Qr) while the patient was ventilated with 100 percent O₂ during the AB infusion at different dosages. The only significant complications of ARDS were recurrent pneumothoraces requiring chest tube drainage. Otherwise, the patient progressed well and was extubated after 26 days. He presented a marked weakness for which a muscular biopsy and an electromyography were performed. The diagnosis was mild myogenic muscular

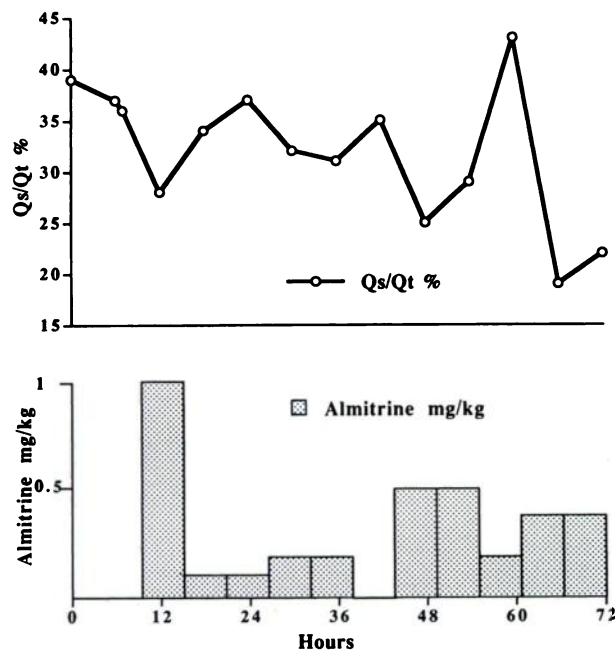


FIGURE 1. Effect of almitrine bismesilate on Q_s/Q_t .

atrophy without inflammation. There were no electrophysiologic signs of peripheral neuropathy. The patient improved and was discharged from the hospital after 42 days. Three months later, the patient walks freely without any paresthesia or dysesthesia.

DISCUSSION

This report confirms the efficacy of AB in improving refractory hypoxemia in ARDS. This effect is most probably a result of an improvement in ventilation/perfusion inequality, as has been shown in clinical studies,^{5,8,9} in the absence of any ventilatory or significant hemodynamic variations. The dosage necessary to obtain a significant effect was 0.35 to 0.5 mg/kg/h, consistent with previous reports.^{4,5}

There are three points of interest in this case report. First, it is, to our knowledge, the longest intravenous high dose AB treatment reported in a patient with ARDS. The AB was maintained because serial attempts to reduce it met with a significant worsening of hypoxemia, which had been, most certainly, in part responsible for the myocardial infarction.

Second, our main fear during AB infusion was the potential development of pulmonary arterial hypertension, which is thought to result from AB-induced vasoconstriction.⁷ Continuous monitoring with a Swan-Ganz catheter, however, showed a maximal mean pulmonary arterial pressure of 25 mm Hg and no significant change in cardiac output. By comparison, in patients with ARDS, two studies have shown a significant albeit small increase in pulmonary artery pressure (PAP) during a short AB perfusion.^{4,5} Conversely, Prost et al⁶ have observed no such change in their patients. None of these authors measured significant modifications in cardiac output. Recently, Plaisance and Payen¹⁰ have shown that the improvement in PaO_2 is not correlated with an increase in PAP.

Finally, peripheral neuropathy, another recognized complication of long-term AB treatment, usually occurs after several months of treatment,¹ and seems to be accentuated by

high doses of AB.³ When our patient awakened, signs of muscular weakness became apparent, but without paresthesia or dysesthesia. The differential diagnoses of this condition included the effects of long-term immobilization, treatment with neuromuscular-blocking drugs,¹¹ the neurologic complications of ARDS¹² and the prolonged treatment with AB. A muscular biopsy and an electromyography were performed, which allowed a diagnosis of myogenic atrophy, without peripheral neuropathy, and the clinical recovery confirmed the diagnosis.

In conclusion, AB acutely increased PaO_2 and decreased Q_s/Q_t in a patient with ARDS and severe refractory hypoxemia. Furthermore, these benefits were maintained during a prolonged course (115 h) until the improvement of ARDS occurred. No side effects such as pulmonary arterial hypertension or peripheral neuropathy were observed. Almitrine bismesilate could be an effective treatment of ARDS-induced hypoxemia, particularly in a subgroup of patients without pulmonary arterial hypertension but with severe hypoxemia where high FIO_2 is both insufficient and potentially deleterious.

REFERENCES

- Voisin C, Howard P, Ansquer J. Almitrine bismesilate: a long-term placebo-controlled double-blind study in COAD. Vectarion international multicentre study group. *Bull Eur Physiopathol Respir* 1987; 23(suppl 11):169-82
- Evans T, Tweney J, Waterhouse J, Nichol J, Suggett A, Howard P. Almitrine bismesilate and oxygen therapy in hypoxic cor pulmonale. *Thorax* 1990; 45:16-21
- Watanabe S, Kanner R, Cutillo A, Menlove RL, Bachand RT, Szalkowski MB. Long-term effect of almitrine bismesilate in patients with hypoxemic chronic obstructive pulmonary disease. *Am Rev Respir Dis* 1989; 140:1269-73
- Reyes A, López-Messa J, Alonso P. Almitrine in acute respiratory failure: effects on pulmonary gas exchange and circulation. *Chest* 1987; 91:388-93
- Reyes A, Roca J, Rodriguez-Roisin R, Torres A, Ussetti P, Wagner P. Effect of almitrine on ventilation-perfusion distribution in adult respiratory distress syndrome. *Am Rev Respir Dis* 1988; 137:1062-67
- Prost J, Desché P, Jardin F, Margairaz A. Comparison of the effects of intravenous almitrine and positive-end-expiratory pressure on pulmonary gas exchange in adult respiratory distress syndrome. *Eur Respir J* 1991; 4:683-87
- Dull W, Polu J, Sadoul P. The pulmonary haemodynamic effects of almitrine infusion in men with chronic hypercapnia. *Clin Sci* 1983; 64:25-31
- Rigaud D, Dubois F, Boutet JCB, Verain A, Paramelle B. Effets de l'almitrine sur la distribution isotopique de la ventilation et de la perfusion régionales chez l'insuffisant respiratoire chronique. *Rev Mal Respir* 1980; 8:605-16
- Evrard Y. Bismésilate d'almitrine et rapports ventilation-perfusion. *Rev Mal Respir* 1985; 2(suppl 1):S17-22
- Plaisance P, Payen D. Role of almitrine-induced pulmonary arterial pressure (PAP) increase on gas exchange improvement. *Int Care Med* 1992; 18:S111
- Segredo V, Calwell J, Matthay M, Sharma M, Gruenke L, Miller R. Persistent paralysis in critically ill patients after long-term administration of vecuronium. *N Engl J Med* 1992; 327:524-28
- Witt N, Zochodne D, Bolton C, Grand'Maison F, Wells G, Young B, et al. Peripheral nerve function in sepsis and multiple organ failure. *Chest* 1991; 99:176-84