




Navigation-Assisted Posterior Open Reduction and Internal Fixation in a C-CLAMP Fashion for an Isolated C1 Fracture

Daniele Starnoni¹ Timo Ecker¹ Juan Barges-Coll¹ 

¹Neurosurgical and Spine division, Centre Hospitaliere Universitaire Vadois, Lausanne, Switzerland

Address for correspondence Juan Barges-Coll, MD, MSc, NCP/SPI, Centre Hospitalier Universitaire Vaudois, Rue de Bugnon 21, Lausanne, Switzerland 1004 (e-mail: juan.barges-coll@chuv.ch).

J Neurol Surg B 2021;82(suppl S1):S61–S62.

Abstract

C1 fractures with an intact transverse ligament are usually treated conservatively. Patients who present with a progressive diastasis of bone fragments and a progressive articular subluxation mainly attributed to progressive lengthening of the transverse ligament (TAL) fibers can be treated with a C1 “C-clamp” fusion.

A 75-year-old male who sustained a motor vehicle accident was neurologically intact. A computed tomography (CT) imaging demonstrated a Jefferson’s type-C1 fracture with a slight lateral displacement of the C1 left lateral mass (LM) and a rotatory subluxation on the right. MRI showed an intact TAL and demonstrated an isolated rupture of the left alar ligament. Conservative treatment was chosen. Radiographic follow-up showed, at 3 months, progressive lateral mass displacement, most likely due to elongation of the TAL fibers; this was also associated with a persistent mechanical neck pain. For this reason, we performed a posterior reduction and internal fixation in a C-clamp fashion by placement of C1 lateral mass screws and posterior compression sparing the C1–2 joint. Using navigation, a 3.5-mm screw was inserted into the LM bilaterally. The screw heads were then connected with a rod and compression was applied before tightening. Postoperative CT scan demonstrated a satisfying reduction and further imaging will be made during the follow-up. The patient had a considerable relief of neck pain. Simple lateral mass fixation with C-clamp technique is a reasonable option in case of isolated C1 fractures in patients who have failed conservative management while preserving the range of motion (ROM) at the atlanto–axial joint.

The link to the video can be found at: https://youtu.be/x8bsVwzCt_M.

Keywords

- ▶ atlas fracture
- ▶ Jefferson fracture
- ▶ transverse ligament
- ▶ open reduction and internal fixation



www.thieme.com/skullbasevideos

www.thieme.com/jnlsbvideos

received
March 22, 2019
accepted after revision
September 28, 2019
published online
March 20, 2020

DOI <https://doi.org/10.1055/s-0040-1701692>.
ISSN 2193-6331.

© 2020. The Author(s).

This is an open access article published by Thieme under the terms of the Creative Commons Attribution-NonDerivative-NonCommercial-License, permitting copying and reproduction so long as the original work is given appropriate credit. Contents may not be used for commercial purposes, or adapted, remixed, transformed or built upon. (<https://creativecommons.org/licenses/by-nc-nd/4.0/>)

Georg Thieme Verlag KG, Rüdigerstraße 14, 70469 Stuttgart, Germany

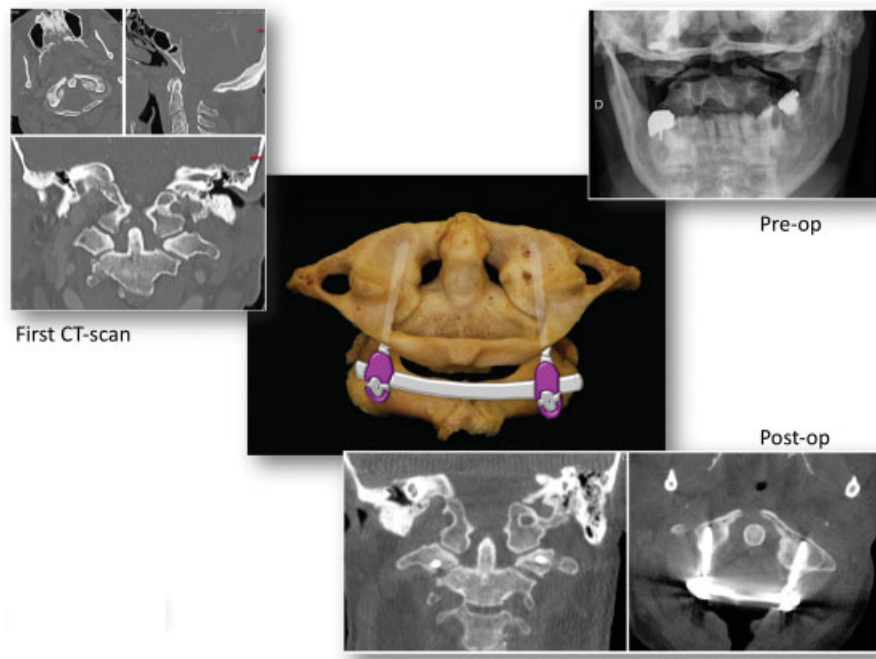


Fig. 1 C1 ORIF in a G-clamp fashion. Pre- and postoperative image and representative model. CT, computed tomography; ORIF, open reduction and internal fixation.

Conflict of Interest

None declared.