

# Caplacizumab for treating subacute intra-stent thrombus occurring despite efficacious double anti-platelet treatment and anticoagulation: a case report

Gregoire Stalder <sup>1,2†</sup>, Antoine Chatte<sup>3†</sup>, Noemy De Rossi<sup>1</sup>, Patrick Yerly<sup>3</sup>, Lorenzo Alberio <sup>1\*</sup>, and Eric Eeckhout<sup>3</sup>

<sup>1</sup>Service and Central Laboratory of Hematology, Centre Hospitalier Universitaire Vaudois (CHUV) and University of Lausanne (UNIL), rue du Bugnon 46, CH-1011 Lausanne, Switzerland; <sup>2</sup>Service of Hematology and Laboratory of Hematology, Institut Central des Hôpitaux, Hôpital du Valais, Av. du Grand-Champsec 86, CH-1951 Sion, Switzerland; and <sup>3</sup>Department of Cardiology, Centre Hospitalier Universitaire Vaudois (CHUV) and University of Lausanne (UNIL), rue du Bugnon 46, CH-1011 Lausanne, Switzerland

Received 23 June 2022; first decision 2 August 2022; accepted 30 December 2022; online publish-ahead-of-print 18 January 2023

## Background

Acute and subacute stent thromboses are a rare complication associated with high mortality and morbidity occurring in ~1.5% of patients treated with primary percutaneous intervention for ST-elevation myocardial infarction (STEMI). Recent publications describe a potential role of the von Willebrand factor (VWF) in thrombus formation at sites of critical coronary stenosis in STEMI.

## Case summary

We describe a 58-year-old woman with STEMI at initial presentation, who suffered subacute stent thrombosis despite good stent expansion, efficacious dual antiplatelet therapy, and therapeutic anticoagulation. Because of very high VWF values, we administered N-acetylcysteine in order to depolymerize VWF, but the drug was not well tolerated. Since the patient was still symptomatic, we used caplacizumab in order to prevent VWF from interacting with platelets. Under this treatment, the clinical and angiographic course was favourable.

## Discussion

Considering a modern view of intracoronary thrombus pathophysiology, we describe an innovative treatment approach, which eventually ended in a favourable outcome.

## Keywords

Subacute stent thrombosis • STEMI • von Willebrand factor • N-acetylcysteine • Caplacizumab • Case Report

## ESC Curriculum

3.1 Coronary artery disease • 3.4 Coronary angiography

## Learning points

- A prothrombotic state induced by highly increased levels of von Willebrand factor may be a cause of intra-stent thrombosis.
- von Willebrand factor plays a key role in thrombus formation and its pathologically increased ability to agglutinate platelets can be inhibited by caplacizumab.

\* Corresponding author. Tel: +41 21 314 34 32, Fax: +41 21 314 43 23, Email: [lorenzo.alberio@chuv.ch](mailto:lorenzo.alberio@chuv.ch)

<sup>†</sup>The first two authors contributed equally to the study.

Handling Editor: Dimitrios A. Vrachatis

Peer-reviewers: Felice Gragnano; Adam Hartley; Milenko Zoran Cankovic

Compliance Editor: Nikolaos Spinthakis

Supplementary Material Editor: Michael Waight

© The Author(s) 2023. Published by Oxford University Press on behalf of the European Society of Cardiology.

This is an Open Access article distributed under the terms of the Creative Commons Attribution-NonCommercial License (<https://creativecommons.org/licenses/by-nc/4.0/>), which permits non-commercial re-use, distribution, and reproduction in any medium, provided the original work is properly cited. For commercial re-use, please contact [journals.permissions@oup.com](mailto:journals.permissions@oup.com)

## Introduction

Acute and subacute stent thromboses are a rare complication associated with high mortality and morbidity that occur in ~1.5% of patients treated with primary percutaneous intervention for ST-elevation myocardial infarction (STEMI).<sup>1</sup> The causes of intra-stent thrombosis are classified into those related to the anatomical characteristics of the lesions, those related to the procedure (in particular malpositioning of the stent), those related to resistance to antiaggregant or anticoagulant treatment, and finally those related to the patient, for example, a prothrombotic state.<sup>2</sup> Recent publications describe a potential role of the von Willebrand factor (VWF) in thrombus formation at sites of critical coronary stenosis in STEMI.<sup>3</sup>

We present the case of a 58-year-old patient with STEMI who suffered subacute stent thrombosis despite good stent expansion, efficacious dual antiplatelet therapy, and therapeutic anticoagulation. The patient showed marked VWF elevation and the evolution was favourable after treatment with caplacizumab, which inhibits the interaction between platelets and VWF.

## Timeline

Initial presentation (D0)	A 58-year-old woman presented with acute chest pain, ventricular fibrillation, and cardiac arrest. After successful reanimation, a coronary angiography (CA) revealed bitroncular coronary disease with an acute occlusion of the left anterior descending (LAD) artery treated by a drug-eluting stent. A significant (70–90%) stenosis of the circumflex artery that was left to be treated later
D5	While on aspirin 100 mg o.d., ticagrelor 90 mg b.i.d., and prophylactic unfractionated heparin (UFH), the patient presented acute-onset chest pain aggravated by breathing, and a new swelling of the left leg. Duplex ultrasonography confirmed a deep vein thrombosis of the left popliteal vein. Start of therapeutic UFH
D7	CA demonstrated a large filling defect within the stent in the LAD artery compatible with early intra-stent thrombosis. Eptifibatide administration
D8	Start of <i>N</i> -acetylcysteine (NAC)
D19	CA showed persistence of known lesions with only minimal thrombus regression. Persistence of daily chest pain. NAC arrest
D21	Start of caplacizumab. Cessation of chest pain
D27	CA showed thrombus size reduction in the LAD. LAD lesion and the circumflex artery stenosis were both treated with drug-eluting stents
D33	Caplacizumab arrest
D40	Patient discharged

## Case presentation

A 58-year-old woman, known for seropositive arthritis and premature ventricular complexes, without other comorbidity, in particular cardiovascular risk factors, and without known coronary artery disease,

presented with acute chest pain, ventricular fibrillation, and cardiac arrest. After the return of spontaneous circulation, the patient was transferred to the emergency department of our tertiary care hospital.

The electrocardiogram (Figure 1) showed an anterior ST-segment elevation myocardial infarction. Coronary angiography (CA) revealed coronary artery disease with an acute occlusion of the left anterior descending (LAD) artery, which was treated with a drug-eluting stent (Orsiro mission 3.0 × 18 mm, Biotronik, Berlin, Germany) and a significant (70–90%) stenosis of the circumflex artery that was left to be treated later (Figure 1).

After a 4-day stay in the intensive care unit, she was extubated and transferred to the cardiovascular intermediate-care unit. On Day 5, while on aspirin 100 mg o.d., ticagrelor 90 mg b.i.d., and prophylactic unfractionated heparin (UFH), the patient experienced acute onset of chest pain aggravated by breathing, and a new swelling of the left leg. Duplex ultrasonography confirmed a deep vein thrombosis of the left popliteal vein. Therapeutic anticoagulation with UFH was started. In the evening of Day 5, she developed respiratory distress. Computed tomography angiography excluded pulmonary embolism and showed bilateral pleural effusion with septal thickening compatible with cardiac overload. She improved with oxygen, non-invasive ventilation, and diuretics.

A second CA performed on Day 7 because of persistent chest pain and a failure of troponin levels to decrease<sup>4,5</sup> demonstrated a large filling defect within the stent in the LAD artery compatible with subacute intra-stent thrombosis (Figure 2). Antithrombotic treatment was completed with glycoprotein (GP) IIb/IIIa inhibition (eptifibatide 180 mcg/kg IV bolus followed by 2 mcg/kg/min infusion for 12 h).

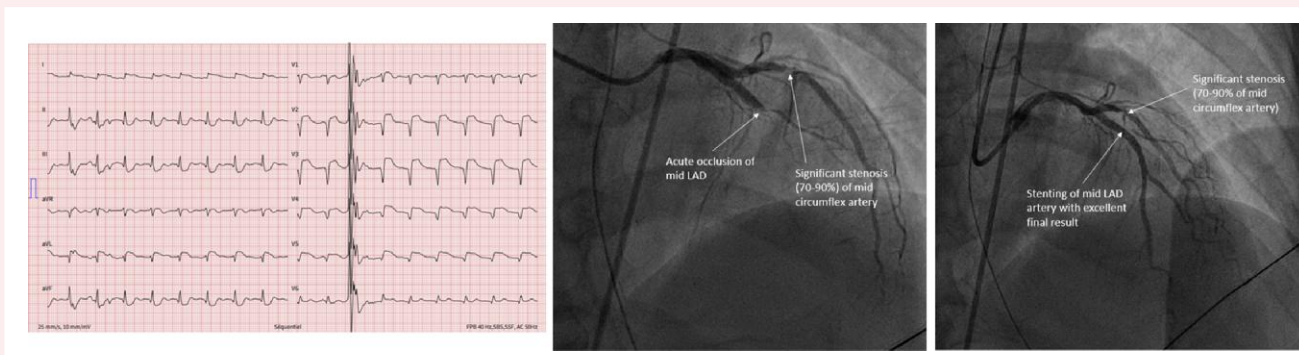
We considered the following possible causes of subacute intra-stent thrombosis: (i) mechanical: stent malapposition/underexpansion; (ii) functional: antiplatelet-treatment resistance, platelet-activating anti-PF4/heparin-antibodies, or severe thrombophilia.

Correct stent deployment was determined during the procedure based on high-pressure non-compliant balloon angioplasty performed with a 3 mm balloon at 18 atm and the subsequent analysis of X-ray enhancement imaging. Since the visual assessment was unequivocal, invasive imaging by intravascular ultrasound (IVUS) was not performed.

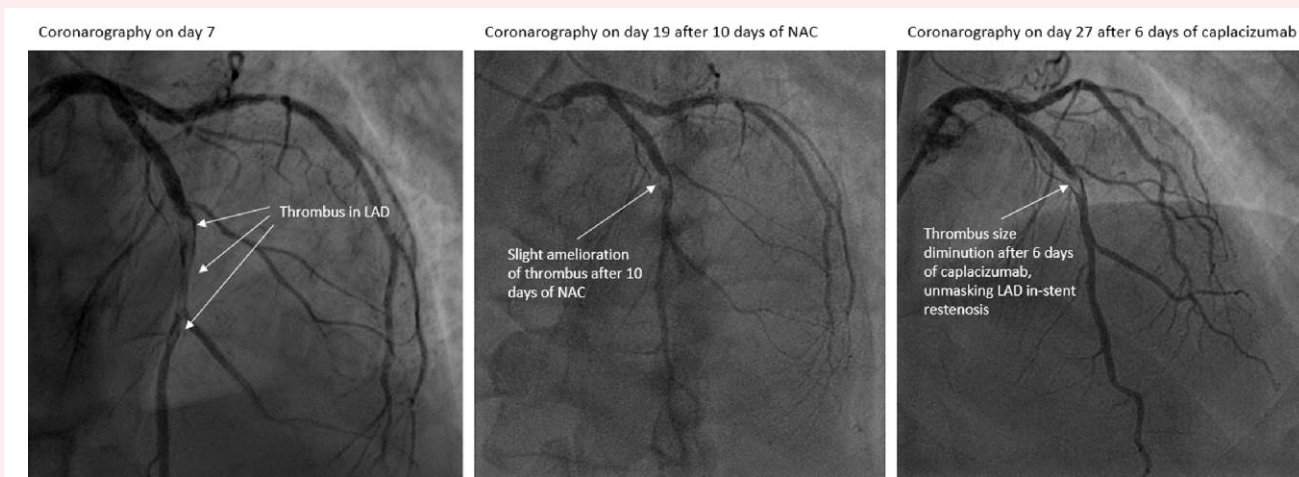
Owing to the recurrent thrombosis despite good stent expansion, ongoing dual antiplatelet therapy, and therapeutic anticoagulation, extensive haematological investigations were performed. Platelet function testing with VASP/P2Y<sub>12</sub><sup>®</sup>, and multiple electrode aggregometry (MEA) showed no argument for ticagrelor resistance and resistance to aspirin was excluded by MEA and light transmission aggregometry (LTA).<sup>6</sup> Blood test showed raised high-sensitive cardiac troponin T (hs-cTnT) at 7546 ng/L (cut-off: < 14 ng/L) and D-dimers at 4047 ng/mL (cut-off: < 500 ng/mL) despite therapeutic UFH anti-Xa activity 0.45 U anti-Xa/mL (in-house therapeutic range: 0.3–0.6 U anti-Xa/mL). Possible prothrombotic causes were excluded by negative results for anti-PF4/heparin-antibodies, anti-phospholipid antibodies, ADAMTS13 activity, factor V Leiden, and G20210A prothrombin mutations. Polymerase chain reactions for SARS-CoV-2 on nasopharyngeal swabs performed at D0 and D5 were negative. Of note, we observed markedly raised values for factor VIII 385% (reference range: 65–170%), VWF activity 208% (50–150%), and antigen 372% (50–150%). Considering the laboratory results showing good platelet inhibition by aspirin and ticagrelor and UFH anti-factor Xa activity within the therapeutic range, in view of the good stent expansion, and in the absence of alternative explanations, subacute intra-stent thrombosis was attributed to the markedly high levels of VWF.

## Therapeutic approach 1: depolymerization of von Willebrand factor multimers

*N*-acetylcysteine (NAC) is a molecule composed of L-cysteine with an acetyl moiety attached to an amine group, which contains a free thiol



**Figure 1** Electrocardiogram and coronary angiography on Day 0 with acute myocardial infarction. Electrocardiogram showing an anterior ST-segment elevation myocardial infarction (left panel). Coronary angiography showing occlusion of the left anterior descending artery and significant stenosis of the circumflex artery (middle panel). Coronary angiography just after angioplasty and stenting of the left anterior descending (right panel).



**Figure 2** Evolution of thrombus under *N*-acetylcysteine and caplacizumab. Coronary angiography with intra-stent thrombosis in the left anterior descending (LAD) artery (left panel). Coronary angiography after 10 days of *N*-acetylcysteine treatment with partial thrombus regression (middle panel). Coronary angiography after 6 days of caplacizumab with thrombus size diminution in the LAD (right panel).

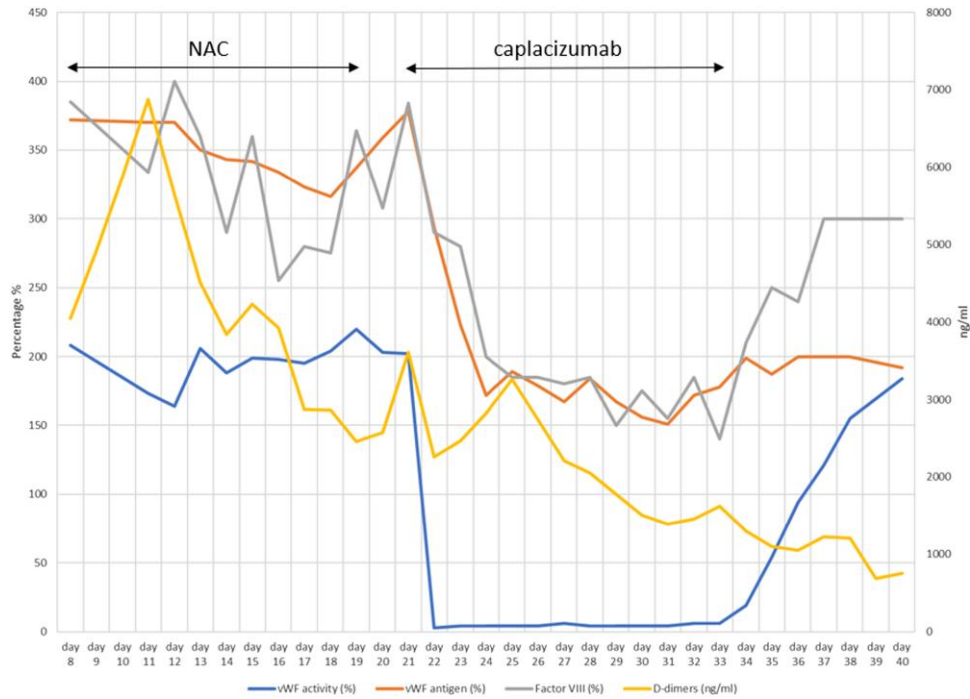
and is capable of reducing the size of polymeric proteins.<sup>7</sup> Its ability to decrease the size of VWF-multimers has been demonstrated *in vitro* as well as in mouse models of thrombocytopenic thrombotic purpura (TTP) and arterial thrombosis.<sup>7,8</sup> *N*-acetylcysteine has also been used in at least eight patients with TTP,<sup>9</sup> and clinical trials are underway in patients with TTP<sup>10</sup> ('NACinTTP') and ischaemic stroke ('Booster').

Based on this knowledge, a treatment of NAC 150 mg/kg/day was started on Day 8. Unfortunately, the high dose of NAC (10 g/day) was not well tolerated by the patient, resulting in several digestive symptoms (nausea, vomiting, and diarrhoea). Blood tests showed no significant improvement in VWF activity (Figure 3). During NAC treatment, hs-cTnT progressively decreased to levels around 450 ng/mL (Figure 4). However, the patient remained symptomatic with recurrent daily chest pain and a control CA performed on Day 19, after 10 days of NAC treatment, showed the persistence of known lesions with only minimal thrombus regression (Figure 2). Given the poor tolerance and lack of clear response observed with NAC, this molecule was stopped.

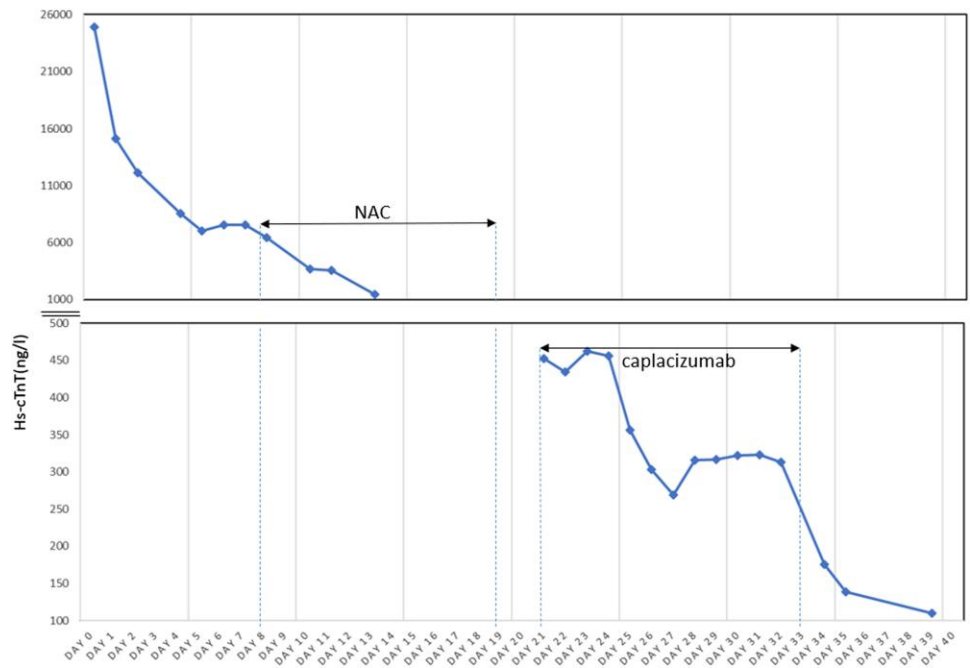
## Therapeutic approach 2: inhibition of platelet GPIIb $\alpha$ -von Willebrand factor A1 domain interaction

Caplacizumab is a nanobody directed against the A1 domain of VWF, which inhibits the interaction of VWF with the platelet GPIIb $\alpha$  receptor.<sup>3</sup> A Phase 1b study in patients with coronary angioplasty showed a decrease in VWF activity and antigen under this treatment, without bleeding complications.<sup>11</sup>

Based on these data and given the critical situation of the patient, after a multidisciplinary discussion and patient agreement, we decided to employ caplacizumab. We administered a first IV dose of 10 mg on Day 21 post-acute myocardial infarction (AMI), followed by daily subcutaneous doses of 10 mg. The treatment was rapidly efficacious from a biological point of view, with suppression of VWF activity, reduction of VWF antigen, and Factor VIII activity (Figure 3). Of note, hs-cTnT, which after Day 5 failed to decrease further as expected,<sup>4,5</sup>



**Figure 3** Evolution of coagulation parameters through time. Evolution over time of the patient's von Willebrand activity (blue), von Willebrand antigen (orange), factor VIII (grey), and D-dimer (yellow) levels, under treatment with N-acetylcysteine (NAC) and then caplacizumab.



**Figure 4** Evolution of hs-cTnT through time. Evolution over time of troponin levels and under treatment with N-acetylcysteine (NAC) and then caplacizumab.

dropped from persistently elevated levels from 450 to 139 ng/mL (Figure 4). Caplacizumab was also efficient from a clinical point of view, with no recurrence of chest pain and improvement of dyspnoea.

After 6 days of positive evolution, CA was performed showing thrombus size reduction in the LAD (Figure 2). This lesion and the circumflex artery stenosis had both been treated with drug-eluting stents.

Caplacizumab was stopped after 12 days of use. Aspirin was discontinued after 1 month and the patient was finally discharged after 40 days of hospitalization on prasugrel 10 mg o.d. (interrupted after 1 year) and long-term acenocoumarol. Her cardiac function is reduced with a left ventricular ejection fraction (LVEF) of 37% under guideline-directed medical therapy for heart failure (Entresto®, metoprolol, spironolactone, and dapagliflozin). Since LVEF was >35% on follow-up controls, an implantable cardioverter defibrillator (ICD) was not considered for primary prevention.<sup>12</sup> At the last visit, 2.5 years after discharge, the patient was progressing well with no recurrent chest pain and no recurrent deep vein thrombosis.

## Discussion

The von Willebrand factor is a plasma glycoprotein secreted by endothelial cells and platelets that circulates in multimers of various length. The von Willebrand factor has a central role in initiating haemostasis and thrombus formation via the interaction of its A1 domain with the GPIIb $\alpha$ -receptor at the platelet surface.<sup>13</sup> This interaction is made possible by the adhesion of VWF-multimers to exposed collagen fibres at the site of vascular wall lesion. In addition, the presence of hydrodynamic variations with high shear stress and acceleration of blood flow can also directly induce the opening of VWF multimeric chains, thus exposing their A1 domains eventually promoting platelet agglutination.<sup>14</sup> Moreover, the ability of VWF to bind platelets is proportional to the size of its multimers. The latter is regulated by ADAMTS13, a metalloprotease that cleaves VWF within its A2-domain, reducing the multimers' size and thus decreasing VWF adhesiveness. It has been shown that during acute ST-segment elevation myocardial infarction, the intracoronary levels of ADAMTS13 were decreased compared with the systemic levels with a decreased ADAMTS13/VWF activity ratio.<sup>15</sup> This relative intracoronary reduction of ADAMTS13 activity would allow for the presence of very long and active VWF-multimers that can be deposited at the site of critical stenosis and mediate platelet adhesion and incorporation in the growing thrombus. This may explain the significant gradient of VWF antigen and activity observed across the coronary occlusion.<sup>15</sup> With this background, very high levels of VWF activity are a possible pathogenic mechanism of intracoronary thrombosis. In the appropriate clinical setting, it is reasonable to consider treatments aimed at decreasing VWF adhesiveness, such as VWF-multimer reduction with NAC or recombinant ADAMTS13, or inhibition of VWF–platelet interaction with caplacizumab. Moreover, the highly increased VWF levels may also have contributed to the DVT diagnosed on Day 5, either directly<sup>16</sup> or indirectly by means of the increased Factor VIII activity.<sup>17</sup>

The major limitation of our Case Report is the absence of IVUS to document good stent deployment. However, the level of evidence for considering the use of intravascular imaging in the case of subacute stent thrombosis is low<sup>18</sup> and in our patient, the per-procedure analysis, with routine high-pressure non-compliant balloon angioplasty and subsequent X-ray imaging enhancement, was considered unequivocal about good stent expansion.

Two other cardiologic management decisions deserve a brief comment. During CA on Day 7, because of normal TIMI flow, the thrombus was not aspirated but treated with GPIIb–IIIa inhibitors instead.<sup>19,20</sup> At discharge, because of the multiple drugs prescribed, ticagrelor was switched to prasugrel in order to minimize the risk of recurrence in the case of suboptimal treatment adherence.<sup>21,22</sup>

## Conclusions

We report the occurrence of subacute intra-stent thrombosis despite efficacious double antiplatelet treatment and therapeutic anticoagulation.

Caplacizumab, a bivalent single-domain antibody inhibiting the interaction between VWF and its receptor on platelets, led to the improvement of clinical symptoms, decrease of laboratory signs of myocardial ischaemia, and possibly reduction of intracoronary thrombus.

Our observations support the pathogenic role of very high levels of VWF in coronary stent thrombosis by their potential to sustain platelet incorporation into the growing thrombus. *In nuce*, these data suggest that caplacizumab may have a relevant potential therapeutic utility, which should be investigated in the critical context of unexplained intra-stent thrombosis.

## Lead author biography



Professor Lorenzo Alberio, MD, is a haematologist, currently serving as chief physician at the Service and Central Laboratory of Hematology of the Centre Hospitalier Universitaire Vaudois, Lausanne, Switzerland and head of the haemostasis unit. His research activities focus on the interactions between platelets and coagulation and include the recent interest for the role of von Willebrand factor in the intra-coronary thrombus formation.

## Supplementary material

Supplementary material is available at *European Heart Journal – Case Reports*.

## Acknowledgements

We thank Michael Henry Cotton, MD, for the careful editing of the English language.

**Slide sets:** A fully edited slide set detailing these cases and suitable for local presentation is available online as [Supplementary data](#).

**Consent:** Signed informed consent was obtained from the patient in accordance with COPE guidelines.

**Conflict of interest:** None declared.

**Funding:** None declared.

## References

- D'Ascenzo F, Bollati M, Clementi F, Castagno D, Lagerqvist B, de la Torre Hernandez JM, et al. Incidence and predictors of coronary stent thrombosis: evidence from an international collaborative meta-analysis including 30 studies, 221,066 patients, and 4276 thromboses. *Int J Cardiol* 2013;**167**:575–584.
- Gori T, Polimeni A, Indolfi C, Räber L, Adriaenssens T, Münzel T. Predictors of stent thrombosis and their implications for clinical practice. *Nat Rev Cardiol* 2019;**16**:243–256.
- Muller O, Bartunek J, Hamilos M, Trana Berza C, Mangiacapra F, Ntalianis A, et al. von Willebrand factor inhibition improves endothelial function in patients with stable angina. *J Cardiovasc Transl Res* 2013;**6**:364–370.
- Laugaudin G, Kuster N, Petiton A, Leclercq F, Gervasoni R, Macia JC. Kinetics of high-sensitivity cardiac troponin T and I differ in patients with ST-segment elevation myocardial infarction treated by primary coronary intervention. *Eur Heart J Acute Cardiovasc Care* 2016;**5**:354–363.
- Van den Berg VJ, Oemrawsingh RM, Umans VAWM, Kardys I, Asselbergs FW, van der Harst P, et al. Temporal evolution of Serum concentrations of high-sensitivity cardiac troponin during 1 year after acute coronary syndrome admission. *J Am Heart Assoc* 2021;**10**:e017393.
- Kovács EG, Katona É, Bereczky Z, Homoródi N, Balogh L, Tóth E, et al. Evaluation of laboratory methods routinely used to detect the effect of aspirin against new reference methods. *Thromb Res* 2014;**133**:811–816.

7. Chen J, Reheman A, Gushiken FC, Nolasco L, Fu X, Moake JL, et al. N-acetylcysteine reduces the size and activity of von Willebrand factor in human plasma and mice. *J Clin Invest* 2011;**121**:593–603.
8. Martinez de Lizarrondo S, Gakuba C, Herbig BA, Repessé Y, Ali C, Denis CV, et al. Potent thrombolytic effect of N-acetylcysteine on arterial thrombi. *Circulation* 2017;**136**:646–660.
9. Sadler JE. Pathophysiology of thrombotic thrombocytopenic purpura. *Blood* 2017;**130**:1181–1188.
10. A pilot study of N-acetylcysteine in thrombotic thrombocytopenia Purpura. Tabular view. ClinicalTrials.gov [Internet]. <https://clinicaltrials.gov/ct2/show/record/NCT01808521> (cited 12 April 2021).
11. Bartunek J, Barbato E, Heyndrickx G, Vanderheyden M, Wijns W, Holz JB. Novel anti-platelet agents: ALX-0081, a nanobody directed towards von Willebrand factor. *J Cardiovasc Transl Res* 2013;**6**:355–363.
12. Zeppenfeld K, Tfelt-Hansen J, de Riva M, Winkel BG, Behr ER, Blom NA, et al. 2022 ESC guidelines for the management of patients with ventricular arrhythmias and the prevention of sudden cardiac death. *Eur Heart J* 2022;**43**:3997–4126.
13. Löf A, Müller JP, Brehm MA. A biophysical view on von Willebrand factor activation. *J Cell Physiol* 2018;**233**:799–810.
14. Zheng Y, Chen J, López JA. Flow-driven assembly of VWF fibres and webs in in vitro microvessels. *Nat Commun* 2015;**6**:7858.
15. Pedrazzini G, Biasco L, Sulzer I, Anesini A, Moccetti T, Kremer Hovinga JA, et al. Acquired intracoronary ADAMTS13 deficiency and VWF retention at sites of critical coronary stenosis in patients with STEMI. *Blood* 2016;**127**:2934–2936.
16. Edvardsen MS, Hindberb K, Hansen ES, Morelli VM, Ueland T, Aukrust P, et al. Plasma levels of von Willebrand factor and future risk of incident venous thromboembolism. *Blood Adv* 2021;**5**:224–232.
17. Kraaijenhagen RA, in't Anker PS, Koopman MM, Reitsma PH, Prins MH, van den Ende A, et al. High plasma concentration of factor VIIIc is a major risk factor for venous thromboembolism. *Thromb Haemost* 2000;**83**:5–9.
18. Neumann FJ, Sousa-Uva M, Ahlsson A, Alfonso F, Banning PA, Benedetto U, et al. 2018 ESC/EACTS guidelines on myocardial revascularization. *Eur Heart J* 2019;**40**:87–165.
19. Ibanez B, James S, Agewall S, Antunes MJ, Bucciarelli-Ducci C, Bueno H, et al. 2017 ESC guidelines for the management of acute myocardial infarction in patients presenting with ST-segment elevation: the task force for the management of acute myocardial infarction in patients presenting with ST-segment elevation of the European Society of Cardiology (ESC). *Eur Heart J* 2018;**39**:119–177.
20. Collet JP, Thiele H, Barbato E, Barthélémy O, Bauersachs J, Bhatt DL, et al. 2020 ESC guidelines for the management of acute coronary syndromes in patients presenting without persistent ST-segment elevation. *Eur Heart J* 2021;**42**:1289–1367.
21. Storey RF. Ticagrelor versus prasugrel for PCI-managed myocardial infarction: the battle of the giants continues. *Heart* 2021;**107**:1111–1112.
22. Schüpke S, Neumann FJ, Menichelli M, Mayer K, Bernlochner I, Wöhrle J, et al. Ticagrelor or prasugrel in patients with acute coronary syndromes. *N Engl J Med* 2019;**381**:1524–1534.