





Available online at
 ScienceDirect
www.sciencedirect.com

Elsevier Masson France

www.em-consulte.com/en



TECHNICAL NOTE

Minimally-invasive internal fixation of extra-articular distal femur fractures using a locking plate: Tricks of the trade

M. Ehlinger^{a,*}, P. Adam^a, L. Abane^a, Y. Arlettaz^b, F. Bonnomet^a

^a Orthopaedic Surgery and Traumatology Department, Strasbourg University Hospital, Hautepierre Medical Center, 1, avenue Molière, 67098 Strasbourg 1 cedex, France

^b Orthopaedic Surgery and Musculo-skeletal Traumatology Department, Valais Hospital, avenue Grand Champsec 80, 1951 Sion, Switzerland

Accepted: 9 November 2010

KEYWORDS

Femur fractures;
Locking plate;
Mini-invasive surgery;
Traumatology

Summary Fractures of the distal femur are rare and occur in two distinct population categories: young patients after high energy traumas and elderly patients who fall from their full height, and often carry severe co-morbidities making especially difficult to manage these complex injuries. In elderly patients the potential complications are numerous including infection, non-union and frequent function deterioration. We present a technique of minimally invasive internal fixation of the distal extra-articular femur using a locking plate and present the tricks of the trade to obtain successful reduction and achieve union. The hardware used includes plate fixation with a large fragment locking screw. This minimally invasive surgery combines stability of the internal fixation device with the principles of closed surgery, allowing early mobilization and immediate weight bearing to warrant good functional recovery.

© 2011 Elsevier Masson SAS. All rights reserved.

Introduction

Fractures of the distal femur are rare [1]. This fracture occurs in two distinct populations, young patients who are victims of high energy traumas and elderly patients who fall from their full height and who often have significant

co-morbidities making management of this complex entity especially difficult. The possible complications are numerous in elderly patients including infection, pseudarthrosis and frequent loss of function [1,2].

There are several types of internal fixation and the choice depends upon the extent of articular damage and the surgical school. The choice must be made between plates and retrograde or even antegrade nailing. We present a minimally invasive technique for internal fixation with a locking plate, with special emphasis on the tricks of the trade to obtain good quality reduction and allow immedi-

* Corresponding author.
E-mail address: matthieu.ehlinger@chru-strasbourg.fr
(M. Ehlinger).

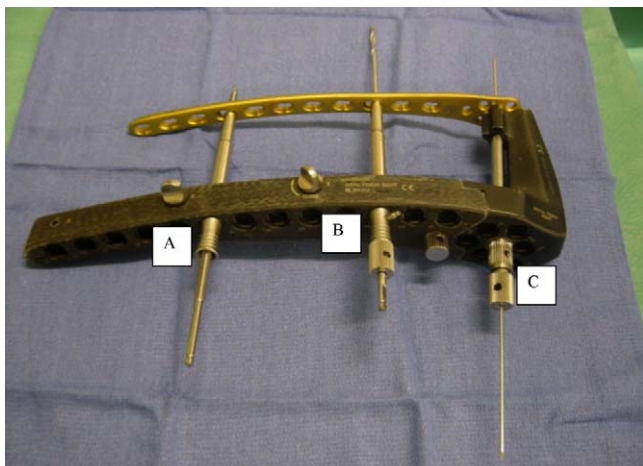


Figure 1 Ancillary LISS. A. Reduction with special instruments to pull the bone to the plate. B. Targeting sleeve and drill. C. Distal targeting sleeve to insert a 2 mm pin to control the position and height of the plate. This targeting sleeve also stabilizes the distal ancillary part of the plate.

ate postoperative weight bearing. This technique optimizes management of frail, elderly patients. It combines stability of the internal fixation device and preservation of the fracture hematoma to improve recovery of function.

Surgical technique

Material

Internal fixation hardware includes titanium plates with large fragment locking screws (LCP™, Synthes, Etupes France). The plate model is unique, anatomical and adapted to the distal femur. The ancillary Less Invasive Stabilisation System (LISS) is systematically used for easy extra-periosteal insertion and especially to facilitate locked screwing (Fig. 1). The so-called “combined” holes in the plate make it possible to use standard or locking screws. Standard screws can be used for bone to plate fixation by lag screw and compression instead of dynamic compression plates (DCP™, Synthes, Etupes France). The locking screw system creates a monoblock assembly for “internal fixa-

tor”. Finally the different screws can be combined to create a mixed system. In addition, there are specific instruments to draw the bone as close to the plate as possible (Fig. 1).

Installation

The patient is in the decubitus dorsal position for the surgical procedure either on a traction or standard operating table. The surgical technique on the traction table is the same as for endomedullary nailing of the femur. Traction can be obtained by boot or tibial pin, because a femoral pin cannot be used due to the proximity of the fracture. The tibial traction pin should be in an anterior position to indirectly correct recurvatum of the distal fragment caused by contraction of the gastrocnemius muscles. Pressure can be applied under the femur from the traction table for direct control of any recurvatum of the distal fragment (Fig. 2a). If the procedure is performed on a standard operating table assistance is required during surgery for traction of the limb along its axis and to control rotation. The contralateral limb is placed in a gynecological stirrup, while being careful of any existing comorbidities, which might limit mobility. A round cushion or sheets are placed under the distal femur to compensate for any secondary recurvatum. The cushion must not be placed in the popliteal groove (Fig. 2b). If surgery is performed on a standard table perioperative control anteroposterior and lateral view X-rays (fluoroscopy?) should be available. The type of table depends on what the surgeon is used to, as both are adapted to treating this type of fracture.

Surgical approach

This is a minimally invasive procedure, thus unlike in periprosthetic fractures, thorough preoperative planning and marking is essential (Fig. 3) to guide the procedure and reduce radiation exposure times. These guide marks are important because they help obtain appropriate positioning of the plate on the frontal plane and in profile to prevent any poor positioning and malunion.

The different guide marks are drawn under fluoroscopic control. The limits of the fracture (proximal and distal), the joint space of the knee and the upper edge of the patella are identified on coronal (frontal) views. The axis of the femoral diaphysis is drawn on profile views so the plate

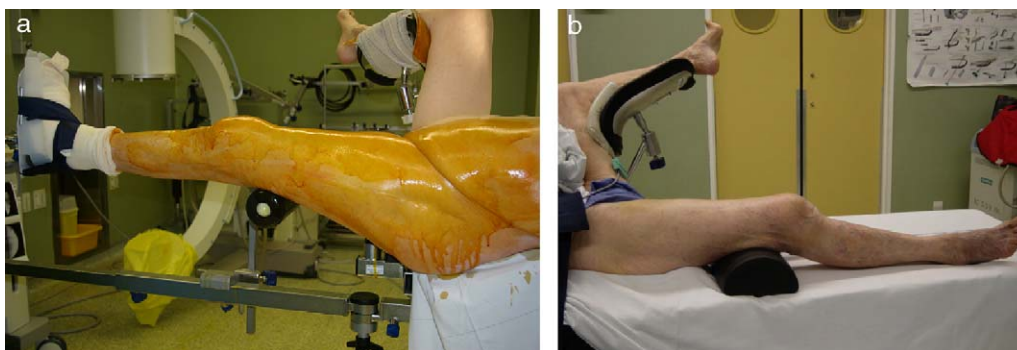


Figure 2 Position to prevent recurvatum. a: positioning on a fracture table, with a support under the distal femur; b: placement on a standard table in the decubitus dorsal position, with the contralateral limb on a gynecological stirrup and a round pillow under the femur but not the popliteal groove.

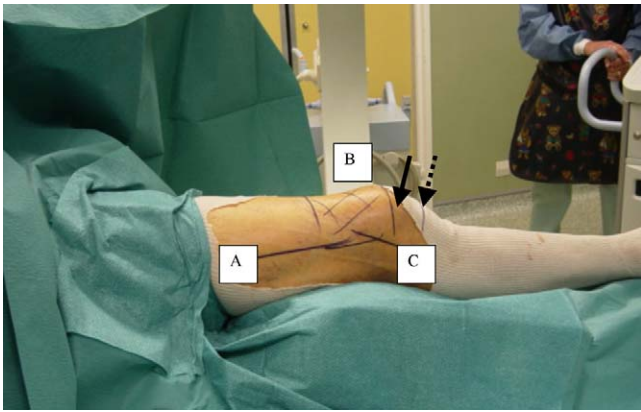


Figure 3 Marks to control the limits of the fractures. A. Control of the diaphyseal femoral axis. B. Shaded area shows the fracture and its distal and proximal ends. C. Mark for the lateral incision. Full arrow: upper end of the patella. Broken arrow: joint space.

can be positioned along the femur for perfect alignment of the plate and the incision. The incision is lateral, distal and paracondylar (Fig. 4). The goal is for surgery to remain minimally-invasive.

Reduction and fixation

The aim is to restore the anatomical and thus the mechanical axis of the limb. There are two phases to reduction: peroperative and perioperative.

The preoperative phase includes traction of the injured limb along its axis on the traction table or with assistance

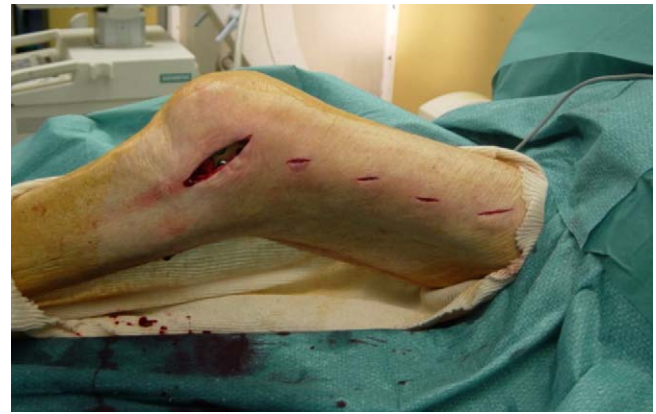

Figure 4 Perioperative minimally invasive approach: paracondylar incision to insert the plate and proximal incisions to insert the screws.

on a standard operating table. This traction is the first step in reduction.

The peroperative phase includes additional reduction manoeuvres (Fig. 5) corresponding to the “tricks of the trade”, which are commonly used in our unit. A temporary intrafocal pin (Fig. 5a) can be used to reduce overlap from recurvatum, flexum or translation. The pin is kept in place until both fragments have been stabilized with at least two screws each. The anatomical design of the distal femoral plate serves as a mold for reduction. The position is correct when the most epiphyseal screws are parallel to the joints. Correct frontal positioning of the plate is controlled fluoroscopically by inserting a 2 mm pin into a specific targeting sleeve that should be parallel to the joint space (Fig. 5b). On profile views the plate should be aligned along the femoral

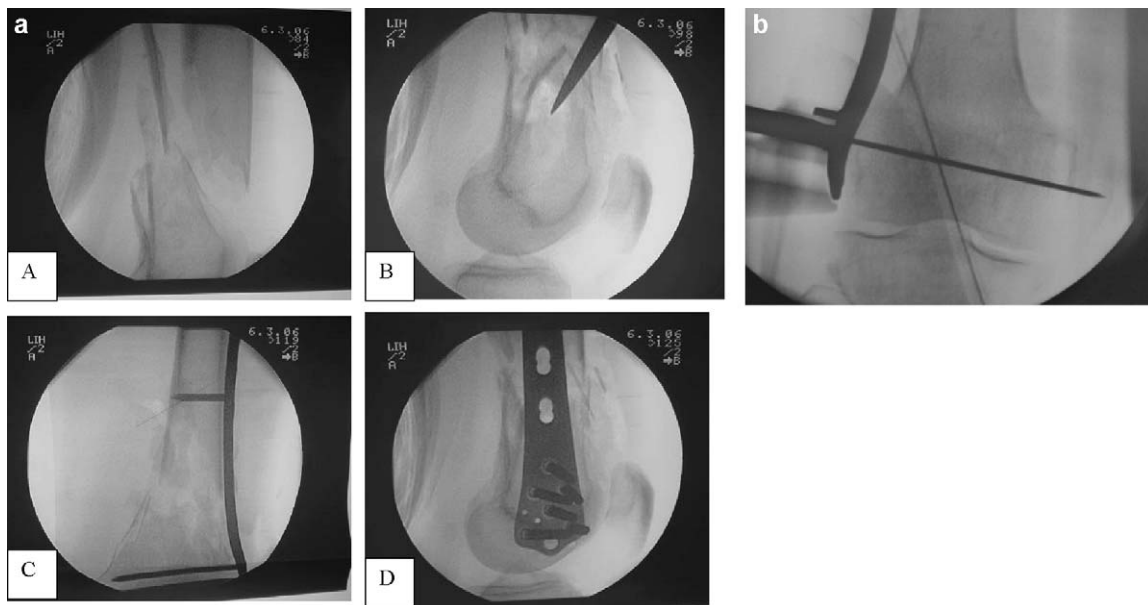


Figure 5 Tricks of the trade for fracture reduction. a: intrafocal pin. A. Perioperative fluoroscopic control image sagittal view. Significant recurvatum of the distal fragment. B. reduction and booting of the fragment thanks to an intrafocal square. C. perioperative fluoroscopic coronal image after plate insertion. D. Fluoroscopic control sagittal view. Reduction of the fracture and alignment of the anterior cortices; b: control of correct positioning of the level of the plate to use the anatomical form of the plate as a mold: 2 mm pin parallel to the joint space.

diaphysis. The position is correct when the anterior cortex is parallel to the anterior edge of the plate. Since this is a monoblock internal fixation system, it does not need to be flush to the bone. Nevertheless, the plate should be parallel to the entire femoral diaphysis whether it is touching the bone or not. Under no circumstances should the gap between the plate and bone be different at the diaphysis and the epiphysis, as this position creates a risk of malunion. For example a valgus malalignment can occur if the plate is touching the bone proximally but not distally. In this case the parallel position of the screw is no longer a criteria for correct positioning. Correct positioning of the plate is essential and makes it possible to use its anatomical structure to confirm good quality reduction. Control of the profile view confirms that the screws are actually screwed into bone and are not tangential to the cortex, which can cause secondary mechanical failure. An indirect way to use the anatomical structure of the plate is by attaching the bone to the plate with a standard return screw so that the plate serves as a mold for reduction. This also helps prevent translation of fragments. It is important to pull the bone towards the plate and not vice versa. Titanium, which is the material we use, is elastic and can become deformed. If the plate is deformed by being pulled to adapt to the bone, fixation of a displaced fragment could occur, resulting in a risk of valgus malunion, for example.

Procedure for internal fixation and immediate post-operative weight bearing

We allow immediate postoperative weight bearing as long as there is no pain. The goal is to restore patient autonomy and reduce the complications of lying in the decubitus dorsal position. The fracture and the internal fixation must meet certain criteria before weight can be applied to the leg:

- extra-articular fracture only;
- minimally-invasive technique which preserves the fracture hematoma for so called biological osteosynthesis [3];
- long internal fixation with at least five proximal holes above the fracture site. Ideally three locking screws should be inserted with a hole separating each. This allows for better distribution and absorption of stresses;
- at least three screws to stabilize the proximal fragment and 4 distal metaphyso-epiphyseal screws depending on the space available;
- bicortical screws should be systematically used to increase the strength of internal fixation and limit tearing [4];
- unicortical screw at the proximal end of the plate to evenly distribute stresses and reduce the risk of fatigue fracture in fragile bone [5];
- placement of screws near the fracture site in "complex" fractures to increase rigidity of the internal fixation device [6] and further from the fracture site in "simple" fractures by leaving a hole free between each. The elasticity of titanium is then intact which is beneficial for union in simple fractures. This prevents excessive screwing, concentrating stress and the risk of stress fracture from the material [6].

Success criteria

Success criteria for this procedure are restoration of an anatomical and thus mechanical axis while preserving the minimally invasive nature of surgery. Exact reduction of fragments and fitting of the fracture is not the goal. However, if reduction is unsatisfactory, a limited open surgical approach should be performed to correct muscle interposition. An axial deviation of less than 5° on the frontal (coronal) or in profile (sagittal) plane is usually considered acceptable in the literature. [7]. Reliable radiological criteria are important to evaluate the quality of reduction. It should be remembered that the condyles should overlap perfectly in a high quality fluoroscopic sagittal view image. These criteria are the basis for control of the coronal view which is perpendicular to the sagittal view. Alignment and the correspondence between cortical thicknesses on coronal and sagittal views also help confirm successful correction. Obviously the best way to avoid errors is to follow the recommendations presented here. Finally, plate positioning should be optimum to prevent any risk of malunion.

Discussion

Theoretically, the titanium LCP we describe here provides better stabilization of osteoporotic bone [3,8–13]. Unlike Dougherty et al. [4] we propose the systematic use of bicortical screws which results in three points of stabilisation (two cortical + the plate) to limit tears. Titanium provides better anchoring to bone because of greater biocompatibility. The association of triple screw fixation, the monoblock device and the material guarantees better long-term stable internal fixation in fragile bone and resistance to tears [6,8,10,14]. The minimally-invasive technique we describe allows biological internal fixation by preserving the fracture hematoma, as in endomedullary nailing while preserving the periosteum and the surrounding soft tissues because there is no open surgery [9,11,12]. By allowing weight bearing if internal fixation is successful, time to union, time in bed and the complications of the decubitus dorsal position are limited [14]. The proposed technique associates the principle of a minimally invasive approach and stable internal fixation. Because the screws are locked, the plate need not be flush with the bone to obtain primary stability by the "friction effect" [9,11], thus preserving peripheral vascularisation and limiting bone resorption under the plate.

Recent experimental data in the literature provide further details on the mechanical rules for these devices. For Ahmad et al. [15] the device should be fairly close to the bone despite the "monoblock" design of this type of internal fixation. In their experimental study of Sawbone®, they concluded that a distance of less than 2 mm provides better resistance to compression and torsion. Plastic deformation was significant when the gap exceeded 5 mm. LCP plates have combined screw holes allowing the use of the "LCP internal fixator" system the "DCP dynamic compression" system or mixing both systems. A recent study by Stoefel et al. [16] compared these three types of utilization of the LCP plate systems on supracondylar + intercondylar distal femur fracture models. The "LCP internal fixator" system was the most rigid during axial compression and had

the least amount of plastic deformation. The DCP system resisted torsion better. Thus, the authors suggest using a mixed system. Finally, it should be remembered that Bottlang et al. [5] suggest using standard screws at the proximal end of the plate in fractures on very fragile bone to limit stress and prevent the risk of underlying stress fractures. This type of assembly increases resistance during flexion without changing resistance to compression or torsion.

Our experience is based on a series of 47 fractures of the distal femur treated by locking plate between January 2005 and December 2008. This included 18 extra-articular fractures, which were treated by a minimally invasive approach. There were six men and 12 women mean age 66 (34–94). Fractures were mainly type A1 according to the AO [17]. The procedure was performed on a standard table in 11 cases and a traction table in 7 cases. Full weight could be applied in 11 cases, partial weight for 6 weeks in one case, no weight for 6 weeks in four cases and two patients were bedridden when the fracture occurred. There were three complications: superficial venous thrombosis, a superficial infection treated with draining and appropriate antibiotics and aseptic pseudarthrosis treated with decortication and grafting. Finally, there were two cases of valgus malalignment of more than 5°. Both cases were clearly due to a technical error-failure to obtain parallel alignment of epiphyseal screws. There was no malalignment on the sagittal plane greater than 5°.

This minimally invasive approach is highly technical and rigorous and a learning curve is clearly necessary. The technical tricks of reduction must be known. Besides sufficient expertise, it should be noted that this technique should be limited to extraarticular fractures, or for fixation of a simple non displaced articular fractures. Minimally-invasive surgery is not an end in itself. The goal should be to obtain high quality reduction at the level of bone axis. Therefore if necessary, the strategy should be changed to a surgical approach to reduce the fracture using a temporary bone forceps in particular in the presence of muscle interposition.

Since this is not open surgery, the problem of perioperative radiation must be mentioned. Preplanning, the position of the patient and implementation of cutaneous marking are essential to minimize exposure to radiation as much as possible. To our knowledge, there are no results in the literature on perioperative radiation during minimally invasive internal fixation with a locking plate.

Placing the patient in the decubitus dorsal position is an important advantage in this elderly population. The absence of open surgery and significant muscular detachment limits blood loss (this has not yet been evaluated in our unit) and immediate postoperative pain.

Conclusion

Minimally-invasive internal fixation of distal extra-articular fractures of the femur with a locking plate is an elegant but difficult technique. It associates the principles of internal fixation in a closed fracture site with assembly stability. It is essential to follow the rules that we suggest to obtain stable internal fixation of the device and successful reduction. The goals of this technique are rapid weight bearing, facilitating functional recovery and obtaining good quality union.

Conflict of interest statement

M. Ehlinger, P. Adam. Occasional Consultant for Synthes®.
L. Abane, Y. Arlettaz, F. Bonnomet. None.

References

- [1] Zlowodzki M, Bhandari M, Marek DJ, Cole PA, Kregor PJ. Operative treatment of acute distal femur fractures: systematic review of 2 comparative studies and 45 cases series. *J Orthop Trauma* 2006;20:366–71.
- [2] Gwathmey Jr FW, Jones-Quaidoo Sm, Kahler D, Hurwitz S, Cui Q. Distal femoral fractures: current concept. *J Am Acad orthop Surg* 2010;18:597–607.
- [3] Lungerhausen W, Ulrich P. Biological osteosynthesis. *Zentralbl Chir* 1997;122:954–61.
- [4] Dougherty PJ, Kim DG, Meisterling S, Wybo C, Yeni Y. Biomechanical comparison of bicortical versus unicortical screw placement of proximal tibia locking plates: a cadaveric model. *J Orthop Trauma* 2008;22:399–403.
- [5] Bottlang M, Doornink J, Byrd GD, Fitzpatrick DC, Madey SM. A nonlocking end screw can decrease fracture risk caused by locked plating in the osteoporotic diaphysis. *J Bone Joint Surg (Am)* 2009;91:620–7.
- [6] Stoffel K, Dieter U, Stachowiak G, Gachter A, Kuster MS. How can stability in locked internal fixators be controlled? *Injury* 2003;34:11–9.
- [7] Ehlinger M, Adam P, Moser T, Delpin D, Bonnomet F. Behavior of type C peri-prosthetic femoral fracture treated by locking plate fixation. Revision at mean 2.5 years of follow-up. *Orthop Traumatol Surg Res* 2010;96:42–7.
- [8] Kregor PJ, Stannard JA, Zlowodzki M, Cole PA. Treatment of distal femur fractures using the less invasive stabilization system: surgical experience and early clinical results in 103 fractures. *J Orthop Trauma* 2004;18:509–20.
- [9] Perren SM. Evolution of the fixation of long bones fractures. The scientific basis of biological internal fixation: choosing a new balance between stability and biology. *J Bone Joint Surg (B)* 2002;84:1093–110.
- [10] Luo CF. Locking compressive plating: a new solution for fractures in rheumatoids patients. *Mod Rheumatol* 2005;15:169–72.
- [11] Wagner M. General principles for the clinical use of the LCP. *Injury* 2003;34(Suppl. 2):31–42.
- [12] Farouk O, Krettek C, Miclau T, Schandelmaier P, Guy P, Tscherner H. Minimally invasive plate osteosynthesis: does percutaneous plating disrupt femoral blood supply less than the traditional technique? *J Orthop Trauma* 1999;13:401–6.
- [13] Bolhofner BR, Carmen B, Clifford I. The results of open reduction and internal fixation of distal femur fractures using a biologic reduction technique. *J Orthop Trauma* 1996;10:372–7.
- [14] Ehlinger M, Cognet JM, Simon P. Treatment of femoral fracture on previous implants with minimally-invasive surgery and total weight-bearing: benefit of locking plate. Preliminary report. *Rev Chir Orthop* 2008;94:26–36.
- [15] Ahmad M, Nanda R, Bajwa AS, Candal-Coutou J, Green S, Hui AC. Biomechanical testing of the locking compression plate: when does the distance between bone and implant significantly reduce construct stability? *Injury* 2007;38:358–64.
- [16] Stoffel K, Lorenz KU, Kuster MS. Biomechanical considerations in plate osteosynthesis: the effect of plate-to-bone compression with and without angular screw stability. *J Orthop Trauma* 2007;21:362–8.
- [17] Muller ME, Allgower M, Schneider R, Willenegger H. Manual of internal fixation. 3rd ed. Berlin: Springer Verlag; 1990.